















## A narrative review of cutaneous manifestations and imaging landmarks of breast cancer

Raul Mihailov <sup>1,2</sup> , Alin Laurentiu Tatu <sup>1,3</sup> , Elena Niculet <sup>1,2</sup> , Laura Rebegea <sup>1,2</sup> , Corina Manole <sup>1,2\*</sup> ,  
Mihaela Craescu <sup>1,2</sup> , Camelia Busila <sup>1</sup> , Laura Iuliana Candussi <sup>1</sup> , Valerii Lutenco <sup>2†</sup> ,  
Oana Mariana Mihailov <sup>1\*\*</sup> , Monica Moraru <sup>1,2†</sup> , Marius Paduraru <sup>2</sup> , Floris Cristian Stanculea <sup>4</sup> ,  
Tiberiu-Ioan Mihalache <sup>1,2</sup> 

<sup>1</sup> Faculty of Medicine and Pharmacy, Dunarea de Jos University, Galati, ROMANIA

<sup>2</sup> Emergency County Hospital "Sf. Apostol Andrei" Galati, Galati, ROMANIA

<sup>3</sup> Clinical Infectious Diseases Hospital Galati, Galati, ROMANIA

<sup>4</sup> Carol Davila University of Medicine and Pharmacy, Bucuresti, ROMANIA

\*Corresponding Author: [corinampalivan@gmail.com](mailto:corinampalivan@gmail.com)

\*\*Corresponding Author: [oanamihailov@yahoo.com](mailto: oanamihailov@yahoo.com)

† Equally contributed with the first author

**Citation:** Mihailov R, Tatu AL, Niculet E, Rebegea L, Manole C, Craescu M, Busila C, Candussi LI, Lutenco V, Mihailov OM, Moraru M, Paduraru M, Stanculea FC, Mihalache T-I. A narrative review of cutaneous manifestations and imaging landmarks of breast cancer. Electron J Gen Med. 2024;21(1):em566. <https://doi.org/10.29333/ejgm/14117>

### ARTICLE INFO

Received: 08 Nov. 2023

Accepted: 03 Jan. 2024

### ABSTRACT

Breast cancer is the most prevalent form of malignancy among women worldwide. Breast cancer can emerge on the skin in two ways: directly, as skin metastases or a direct extension of the tumor; or indirectly, as a paraneoplastic disease. Breast cancer imaging is an essential part of breast cancer screening, diagnosis, preoperative/treatment assessment, and follow-up. The selection of optimal imaging modalities should be contingent upon the patient's risk factors and breast density since breast cancer imaging necessitates a personalized approach rather than a universal solution. There are a lot of different skin conditions that point to breast cancer, either as a sign of recurring disease, undiagnosed breast cancer, or a condition that puts you at a higher risk of getting it. Even though reconstruction has been shown to improve quality of life for many women, there are still a lot of complicated factors that affect morbidity and results.

**Keywords:** breast cancer, mastectomy, cutaneous manifestations

## INTRODUCTION

Breast cancer is the most prevalent form of cancer in the United States, with an estimated 287,850 new cases and 43,250 fatalities in 2022, representing 15.0% of all new cancer cases [1]. In actuality, approximately 12.9% of women will develop breast cancer during their lifespan.

Overall survival rates for breast cancer vary a lot from place to place because people from different socioeconomic backgrounds have different access to screening/early detection, treatment, and specialized therapies. About 10.0-15.0% of newly identified breast cancers in high-income countries are already in stage IV (de novo metastatic breast cancer [MBC]) at the time of diagnosis. In middle- and low-income countries, this number is much higher. High death rates from breast cancer are linked to less access to public cancer centers and less uniform coverage of health care [2]. Also, even if they get the best care, about 30.0% of people with early-stage disease will eventually get sick again [3, 4].

Breast cancer can emerge on the skin in two ways: directly, as skin metastases or a direct extension of the tumor; or indirectly, as a paraneoplastic disease. Another crucial

circumstance is when cutaneous tumors appear in conjunction with a genetic cancer syndrome that increases the chance of breast cancer, such as Cowden syndrome. Slow progress has been made in MBC treatment, and the median survival time has remained constant at three years [4-7]. However, the biological subtype, as well as accessibility to excellent multidisciplinary care and suitable medicines, all have a significant impact on this figure. Individuals diagnosed with MBC who have positive results for the human epidermal growth factor receptor (HER2) and the estrogen receptor (ER) often experience a prolonged survival period of several years [5-7].

## MATERIALS & METHODS

A comprehensive literature search was conducted utilizing the databases PubMed, Web of Science, Scopus, and Medline. The search strategy included the use of specific term: "breast cancer", "cutaneous manifestation", "mastectomy", "reconstruction after breast cancer", "imaging of breast cancer", "advanced breast cancer", "metastatic breast cancer", "clinical exam in breast cancer", "cutaneous paraneoplastic syndrome", "radiotherapy and chemotherapy in breast cancer", and "breast cancer mortality", as well as

their combinations regarding cutaneous manifestations and imaging of breast cancer. We have selected the articles that we consider relevant for our theme from 2000 to the present with a few exceptions that stand out due to the breadth of the studies and the relevance of the data.

## RESULTS

We selected 74 studies for our narrative review. Each study was analyzed by one of the authors and chosen to be used in the review through the prism of the importance of the provided data. The authors appreciated the large groups of patients, the studies carried out in several centers, the systematic presentation of the results as well as the innovations brought to the studied field. We excluded non-peer reviewed articles in preprint databases. No restrictions on language or period of publications were applied. Our research efforts were primarily directed towards the examination of randomized controlled trials, meta-analyses, systematic reviews, and observational studies conducted on extensive patient populations.

## DISCUSSION

### Imaging of Breast Cancer

Breast cancer imaging is an essential part of breast cancer screening, diagnosis, preoperative/treatment assessment, and follow-up. Magnetic resonance imaging (MRI), ultrasound and are three fundamental modalities used in medical imaging, each with distinct advantages and constraints. New technologies have also allowed each modality to improve on its shortcomings. Imaging-guided biopsies provide accurate breast cancer diagnosis with low complication rates.

Imaging for breast cancer is divided into two primary categories: screening and diagnostic. The objective of screening mammography (or other imaging modality) in the healthy, asymptomatic female population is to detect undiagnosed cancer and treat it at an earlier stage before it manifests symptoms. Due to the fact that only a small percentage of breast cancers are detectable solely by clinical breast evaluation and the absence of a specific laboratory biomarker for breast cancer, imaging is the cornerstone of early detection [8]. Even though everyone agrees that the breast cancer screening program is helpful, no one can agree on the beginning age, ending age, or amount of time between screenings [9]. Different countries and organizations, such as the American Cancer Society, the American College of Radiology (ACR), and the European Commission, have come up with different guidelines, but most of them say that screening should start when a woman is between 40 and 50 years old and continue until she is 75 years old or until she has about 10 years left to live [9-11].

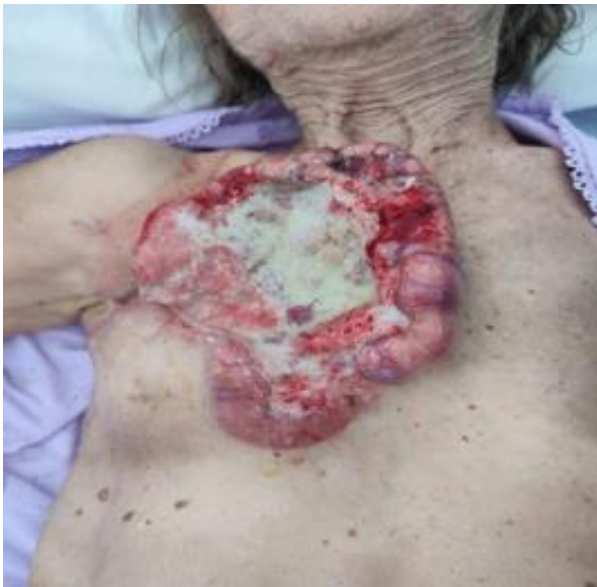Diagnostic breast imaging, on the other hand, is for people who have symptoms or who have had an abnormal physical exam or abnormal first imaging (mostly from abnormal breast screening test memories). According to ACR's criteria for appropriateness, if a woman has a palpable finding, ultrasound is the first choice for patients younger than 30 years old, while mammography is the first choice for patients 40 years or older. In both cases, the next step depends on the results of the first investigation [12,13]. For women between the ages of 30 and

39, mammograms or ultrasound could be the first screening method of choice.

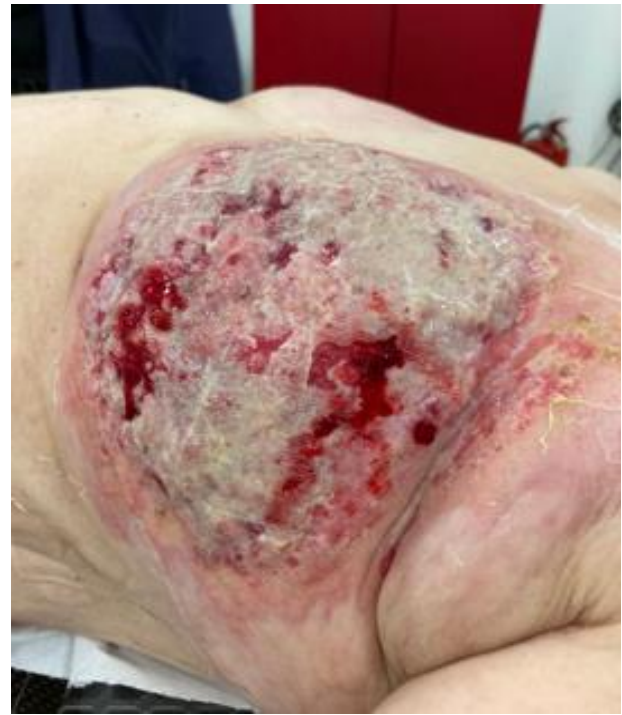The cornerstone of breast imaging, both for screening and diagnostic reasons, is mammography. Each breast is photographed in the usual medio-lateral oblique and craniocaudal perspectives during a mammogram, which is a 2D X-ray imaging of the breast. The preferred screening method for symptomatic women 40 years of age and older is mammography, which is also used as the initial diagnostic test [14]. Breast calcifications are best discovered by mammography and may go undetected on ultrasound and MRI [15]. They can be a marker of ductal carcinoma in situ (DCIS) and invasive malignancy. Additionally, mammography shows panoramic views of both breasts, enabling objective comparisons to the contralateral breast and to various time periods, as well as the identification of asymmetries, architectural anomalies, and spiculated lesions that may be hidden by other imaging modalities [16].

In breast imaging, the United States is a crucial supplementary technique to mammography. It enables real-time, dynamic examination that can help detect minor signs of malignancy and allow for direct assessment of the precise site of a patient's complaints (such as palpable findings, nipple discharge, and discomfort) [17]. Cystic and solid lesions may be consistently distinguished using ultrasound, and the solid lesions can be classified as benign or malignant using BI-RADS descriptors. As thick breasts might hide lumps or cancer on a mammography, it can be utilized as a comprehensive screening technique in individuals with dense breasts. With minimal radiation risk, the United States is the first imaging modality of choice for patients under 30 with palpable abnormalities as well as symptomatic pregnant and lactating individuals [13, 17]. Since ultrasound is the primary recommended technique of breast biopsy, it may be used to examine abnormalities observed on other modalities such as mammography and MRI and enables for biopsy of the findings [17]. The ideal way to check the axilla is also with ultrasound since, because of its elevated placement, it frequently does not fit entirely inside the field of view on mammography.

Breast MRI is the most accurate tool we have for diagnosing breast problems with imaging right now. However, it is expensive and hard to get, and it is only good for certain people and clinical situations. Breast MRI is currently used for screening high-risk and some intermediate-risk patients, assessing the extent of disease in a patient with cancer (e.g., to check for multicentricity or invasion of fascia, to find contralateral cancer), and further evaluating clinical or imaging findings (e.g., cancer of suspected breast origin as metastasis in lymph nodes or other organs, with otherwise inconclusive workup with mammogram and ultrasonography) [18]. The basic idea behind MRI breast cancer diagnosis is that tumoral neo angiogenesis results in leaky blood vessels that enable contrast to extravasate and provide pictures of cancer "enhancement" [19]. When compared to surgical pathology, MRI provides the best correlation of the degree of illness for individuals who have just received a cancer diagnosis, with around 75.0% of malignancies being measured within 1 cm of the pathological size [19]. This advantage is especially potent for the identification of DCIS and aggressive lobular cancer. Up to 20.0% of the time, preoperative MRI can identify additional mammographically occult tumors in the ipsilateral and contralateral breasts, changing the patient's therapy [20].



**Figure 1.** Ulcer-infiltrative tumor formation, with a crateriform appearance, which completely occupies right breast region (central area is ulcerated, with complete destruction of nipple, showing deep whitish deposits & in periphery, edges of tumor are elevated, with a “lacy” appearance, whitish color, accentuated vascular pattern & numerous hemorrhagic areas) (Source: Emergency Clinical Hospital “Sf Apostol Andrei” Galați, First Surgical Clinic. The patient gave her consent to use her personal data and photos by signing the hospitalization form)



**Figure 2.** Ulcer-infiltrative tumor formation located in left mammary region, gray-white in color, with intense hemorrhagic areas (Source: Emergency Clinical Hospital “Sf Apostol Andrei” Galați, First Surgical Clinic. The patient gave her consent to use her personal data and photos by signing the hospitalization form)

The mainstay of breast cancer diagnosis is imaging-guided breast biopsy. Before biopsies, diagnostic imaging should be obtained as post-biopsy alterations such as hematoma, inflammatory changes, and reactive axillary lymph nodes may make the interpretation of the imaging more challenging. Because it is more readily accepted by patients, less costly, and accessible, ultrasound is the chosen main imaging modality for biopsy [17, 21]. It also gives radiologists real-time targeting control with nearly no restrictions on the targetable region in the breast. If a mammogram or MRI abnormality necessitates a biopsy and has an ultrasound correlate, an ultrasound biopsy is typically preferred. Otherwise, biopsy under stereotactic (e.g., calcifications), tomosynthesis (e.g., distortions), or MRI (e.g., non-mass enhancement) guidance are also superb options for non-ultrasound-correlated findings.

### Cutaneous Manifestations of Breast Cancer

Breast cancer can manifest with skin symptoms. There are a variety of breast cancer cutaneous manifestations (**Figure 1**).

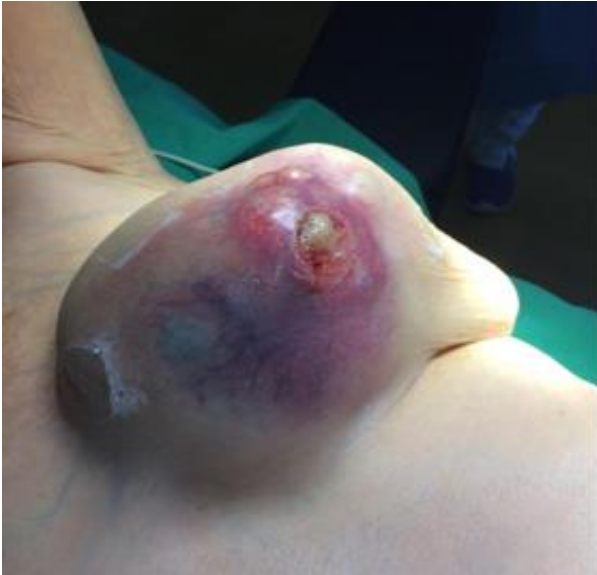The most prevalent clinical manifestations of metastatic cutaneous breast cancer lesions will be described. As indicators of breast cancer, erythema gyratum repens (EGR), acquired ichthyosis, dermatomyositis (DM), multicentric reticulohistiocytosis (MRH), and acquired hypertrichosis lanuginosa have been identified as paraneoplastic cutaneous dermatoses. Mammary Paget’s disease, a condition sometimes accompanied by concurrent breast cancer, and Cowden syndrome, a condition linked to an elevated susceptibility to breast cancer, both have discernible dermatological features. In investigation of newly diagnosed or recurrent breast cancer, it is essential to recognize these distinct cutaneous symptoms.

### Breast cancer cutaneous metastases

Breast cancer is the most often seen malignancy in women that exhibits metastasis to the epidermis. The incidence is approximately 20.0%, with one autopsy series reporting that 26.5% of breast cancer patients have metastatic cutaneous lesions, and 23.9% in a meta-analysis [22, 23]. It was analyzed 724 cases of malignancies with cutaneous metastases that were metastatic [24]. In 3.0% of their MBC cases, it was reported cutaneous metastases as the presenting symptom. The most prevalent location for cutaneous breast metastases is the pectoral wall [24, 25]. Using data from tumor registries, Lookingbill et al. conducted two large retrospective studies and drew several conclusions regarding cutaneous metastases [26, 27]. Breast cancer was the most prevalent tumor to involve skin, accounting for 23.9% of cases, and 3.5% of breast cancer cases had skin involvement as the presenting indicator. Breast cancer cutaneous metastases are the most common metastases diagnosed by dermatologists [28] (**Figure 2**).

Breast cancer cutaneous metastasis manifests itself in a variety of forms. It was analyzed the frequency of the most common clinical presentations of cutaneous metastases in a retrospective study [29]. Nodules are the most prevalent manifestation, occurring in 80.0% of patients. The nodules are typically non-tender, round or oval, mobile, firm, and gelatinous in consistency. They may be solitary or in groups, typically flesh-colored, but also brown, bluish black, pink, or reddish-brown. Also, they can become ulcerated and infected with poor response to topical treatments [30] (**Figure 3**).

Histological examination reveals substantial clusters of malignant cells. Other manifestations of breast cancer with cutaneous metastases have been described. The cutaneous



**Figure 3.** Nodular tumor formation located in left mammary region, whitish in color, with blue areas, increased consistency & with an accentuated vascular pattern (formation is mainly covered by intact skin, except for a small area of ulceration) (Source: Emergency Clinical Hospital “Sf Apostol Andrei” Galați, First Surgical Clinic. The patient gave her consent to use her personal data and photos by signing the hospitalization form)

signs associated with telangiectatic cancer include the presence of papules, plaques, or purpuric nodules. Pruritus is a common concomitant symptom.

Histopathologically, dermal lymphatics are infiltrated by the tumor. Carcinoma en cuirasse, also known as scirrhous carcinoma, is characterized by the presence of dispersed, firm, erythematous, and indurated lesions on the chest wall [31, 32]. Occasionally, the epidermis may appear yellow and have a fibrotic texture. Histologically, there are a small number of dense neoplastic cells, sometimes arranged in an Indian file pattern.

Patients may report searing discomfort. Alopecia neoplastic manifests as circular, indurated patches of alopecia on the scalp due to the hematogenous spread of breast cancer [33]. The areas are typically smooth, non-tender, non-pruritic, and have distinct, rosy-pink borders. These cutaneous metastatic manifestations are identified less frequently than nodules, with two studies reporting incidence rates of 8.0-11.0% for telangiectatic carcinoma, 3.0-6.3% for carcinoma erysipeloid, 3.0-4.0% for carcinoma en cuirasse, and 2.0-12.0% for alopecia neoplastic (2.0%) [28, 29].

When there are many skin tumors, the whole body needs to be treated. The consideration of hormone receptor (HR) status and HER2 status is crucial in the treatment of metastatic skin cancers. This is the same way that visceral metastases are treated. Several endocrine drugs can be used to treat a growth that is HR-positive. Chemotherapy is used for skin tumors that are HR-negative and/or are getting worse quickly. HER2-directed treatment with or without chemotherapy should be used to treat a tumor that is positive for HER2. External beam radiation therapy can be used to treat skin metastases locally, but it would not be used in places that have already been exposed to radiation because of the total dose.

### **Paraneoplastic cutaneous dermatoses**

There are different skin conditions that can show up as paraneoplastic dermatoses and be linked to breast cancer. Even though it happens rarely, it could help find cancer early.

MRH has reddish-brown lumps and papules that are one to two mm in size and look like “coral beads.” They are found on the face and hands [34]. The head, ears, wrists, and elbows are also affected. Some of the signs are losing weight, feeling tired, and having a fever. The joint symptoms can include pain in the distal interphalangeal joints of the hands, wrists, shoulders, knees, or hips. This pain can be on one side or both sides. MRH is thought to be caused by reactive macrophages and monocytes, and an underlying tumor could release a factor that could cause a similar histiocytic reaction [35]. From a histological point of view, there are big, single-nucleated, or multiple-nucleated histiocytes with fine particles in their eosinophilic cytoplasm. One of the cancers most often seen in people with MRH is breast cancer.

EGR looks like wide, colored, circular bands that look like woodgrain or are twisted. It can grow quickly, about one cm per day. Most of it is on the back and arms and legs, but not on the face, hands, or feet. Patients have eosinophilia and have very bad itching. This rash usually gets worse as the cancer gets worse. Most of the time, it shows up between one month and six years before the cancer is found, but it can also happen at the same time or later. The histology shows that there is mild to moderate hyperkeratosis, parakeratosis, spongiosis of the skin, and a lymphocytic infiltrate around the blood vessels. Pathophysiology is not known, but theories include cancer-stimulated antibodies that react with cutaneous antigens or the buildup of tumor antibody-antigen complexes in the skin, which causes inflammation [36]. EGR goes away when the breast cancer that caused it is treated. Systemic cortisone and topical steroids can be helpful as well with their well-known adverse reactions [37].

The most common skin signs of DM are a heliotrope rash, violaceous, swollen, scaly papules over the knuckles (called Gottron’s papules), malar erythema, and erythema or poikiloderma in a “V” pattern on the upper torso (called a “shawl sign”). There is weakness in the muscles near the joint. About 20.0% of the time, DM may be a symptom of breast cancer called a paraneoplastic condition. It has been suggested that the immune reaction to tumors can lead to DM and other inflammatory diseases. Also, since DM and cancers often happen at the same time, they could both be caused by the same antigen or carcinogen [36]. Most of the time, DM goes away when the breast cancer is treated [39-41].

Cowden syndrome, also called multiple hamartoma syndrome, is an example of a cancer syndrome that runs in families and can show up in the skin. There is a higher chance of getting breast cancer (about 20.0% to 50.0%), thyroid tumors, especially follicular and cystic ones, which have a 3.0% to 10.0% lifetime risk, and uterine cancer, which has a 5.0% to 10.0% lifetime risk [42]. The condition under consideration is a hereditary cancer syndrome that exhibits autosomal dominance. Its etiology may be attributed to a mutation in the PTEN tumor suppressor gene, located on chromosome 10q22-23. The presence of several face trichilemmomas is a significant dermatological manifestation with clinical relevance. These are small, flesh-colored papules on the face, head, and neck that look like warts and range in size from one to five mm [41]. Mucocutaneous diseases also include papillomatous papules

on the lips, tongue, gingivae, and oral mucosa, which can look like cobblestones when they stick together. Acral keratoses can also happen. These are bumps on the hands and feet that can be felt or are hyperkeratotic and look like warts. Cancers of the breast, thyroid, and endometrium can happen in people with Cowden syndrome, so knowing about it can help doctors find them [43].

### Impact of Mastectomy & Reconstruction Technique

Breast cancer is the prevailing form of cancer among women globally. In the United States, the chance that a woman will get breast cancer in her lifetime is about one in eight [44]. Approximately 33.0% of these women will get a mastectomy, either due to the presence of cancer, for aesthetic purposes, or as a result of personal preference. Breast reconstruction will be chosen by half of the women in this subgroup [45]. If you decide to have reconstruction after a mastectomy, you will have to make a lot of other choices as well. Some decisions are limited by the patient's anatomy or the skills of the surgeon, but the patient and the healthcare team make decisions about unilateral vs. bilateral surgery, autologous vs. implant-based reconstruction(s), and to some extent, even the timing of reconstruction(s).

When there are so many things to think about when making a number of choices, figuring out how happy the patient is becomes very important. Even though it's clear that rebuilding after a mastectomy has positive effects on a woman's mental health and body image as a whole, there is not much information about how each decision she has to make in this process affects her.

When a breast pathology is found, it is important to think about personal factors like the desire for matching mammoplasty, preventive surgery in the case of non-inherited mutations that cause breast cancer, the time of reconstruction, and the advice of the surgeon [46-48]. Despite the transformative impact of breast-conserving surgery (BCS) followed by radiation therapy on the management of early-stage breast cancer, patients retain the autonomy to choose among various treatment options according to their own preferences. Due to its good results and ease of use, breast organ protection through breast conserving therapy (BCT refers to BCS typically followed by radiation therapy) is now the treatment of choice in this situation. Despite this, several population-based studies showed that mastectomy is still seen as a real treatment choice and is still picked by many breast cancer patients [49-52]. Early-stage breast cancer care can be thought of as a preference-sensitive setting, where decisions about which treatment choices to choose can change based on what the patient wants [53].

Typical reasons for choosing mastectomy as a treatment include:

- (a) worries about cancer coming back,
- (b) the belief that health is more important than keeping the breasts [54], or
- (c) the imagined effects of BCT, such as the possible side effects of radiation therapy [53, 55].

More recently, there has been a rise in the use of skin-sparing or nipple-sparing mastectomies with rapid breast reconstruction, which shows a renewed interest in and movement toward mastectomy [56-58]. Compared to total mastectomy, this treatment gives better results in terms of appearance and quality of life.

Breast cancer treatment has changed a lot over time, and the number of local recurrences after BCT has gone down a lot [59]. The effect of mammography screening on disease progression to earlier stages was smaller tumors and less involvement of lymph nodes. This was followed by changes in adjuvant medicines that were made to fit biology of disease.

Post-mastectomy radiation therapy (PMRT) plays a significant role in the local treatment regimen for a substantial number of women diagnosed with breast cancer. When a patient has a mastectomy, they are usually given choices for breast replacement. For people who are candidates for PMRT, it is hard to find the best way to use radiation to get the best oncological results while reducing side effects and getting the best reconstruction results. The way these choices are made keeps changing as surgical and radiation methods get better and more widely used and as more patients with different local recurrence risk profiles get PMRT.

The decision to undergo breast reconstruction represents a significant advancement in the provision of healthcare for those who have had a mastectomy as part of their breast cancer treatment. The impact on the patient's quality of life and mental well-being is substantial. Recent studies say that around 62.0% of women who have had a mastectomy will have reconstruction. Immediate and implant-based repair are also becoming more common [60-63]. Almost one-third of people who have a mastectomy need extra radiation to the chest wall and the lymphatics that drain from it. Several randomized trials and a meta-analysis conducted by the early breast cancer trialists' collaborative group (EBCTCG) have shown evidence that PMRT has benefits in terms of enhancing local control, disease-free survival, and overall survival rates in patients with a higher risk of cancer recurrence [64-67]. But expecting PMRT can cause surgery to be put off or not happen at all. Additionally, it is noteworthy that this condition may have an influence on the patient's physical appearance, overall quality of life, as well as the potential for consequences. A recent revision of EBCTCG meta-analysis showed that PMRT is useful for patients with less advanced diseases. As a consequence of this finding, the national comprehensive cancer network has recommended the use of PMRT for individuals diagnosed with breast cancer who have tumors measuring five cm or less and between one and three positive lymph nodes [68]. PMRT has been shown to cause about two to three times as many problems after surgery after an implant or donor repair [69-74]. Radiation methods are always getting better, with the goal of reducing long-term side effects as much as possible. Integration of reconstruction and PMRT is still hard because of the need to put oncologic outcomes first, improve radiation methods to reduce side effects and try to get a good result from reconstruction. Current data show different chances of complications. This is partly because of differences in how complications are defined and measured, and partly because of differences in how repair is done.

## CONCLUSIONS

In conclusion, breast imaging is important for screening, identifying, and assessing breast cancer before and after treatment. Mammography, ultrasound, and MRI each have their strengths and possible weaknesses, as well as new technology developments. The selection of optimal imaging modalities should be contingent upon the patient's risk factors

and breast density since breast cancer imaging necessitates a personalized approach rather than a universal solution. Artificial intelligence and personalized screening may become part of everyday professional practice in the future.

There are a lot of different skin conditions that point to breast cancer, either as a sign of recurring disease, undiagnosed breast cancer, or a condition that puts you at a higher risk of getting it. Also, if you notice any of the paraneoplastic skin conditions listed here, you should be suspicious of hidden breast cancer. This will help you get the right diagnosis and treatment for it.

In the end, there is new information about breast surgery after radiation treatment for a mastectomy. Even though reconstruction has been shown to improve quality of life for many women, there are still a lot of complicated factors that affect morbidity and results that make it hard to study and find ways to make real changes. Also, practices vary a lot from one school to the next, which makes things even more complicated. Recent headway has been made with prospective studies that focus on patient-reported outcomes, but the different ways the studies were done, and the different results make it hard to say what the best treatment is.

**Author contributions:** **RM, ALT, & T-IM:** conceptualization; **RM & ALT:** methodology & writing–review and editing; **RM:** project administration & funding acquisition; **ALT & T-IM:** supervision; **EN, LR, CM, & MC:** validation; **LR, VL, & MP:** investigation; **CM, MC, & FCS:** resources; **CB, LIC, VL, & OMM:** visualization; **OMM & MM:** software; & **T-IM:** data curation & writing–original draft preparation. All authors have agreed with the results and conclusions.

**Funding:** APC was paid by the “Dunarea de Jos” University of Galati, Romania.

**Acknowledgments:** This study was academically supported by Multidisciplinary Integrated Center of Dermatological Interface Research Center MICDIR, “Dunarea de Jos” University of Galati, Romania.

**Ethical statement:** The authors stated that the study was conducted in accordance with the Declaration of Helsinki and approved by the Ethics Committee of “Sf. Apostol Andrei” Clinical Emergency County Hospital from Galati, Romania (no 16125/24.07.2023).

**Declaration of interest:** No conflict of interest is declared by authors.

**Data sharing statement:** Data supporting the findings and conclusions are available upon request from the corresponding author.

## REFERENCES

- National Cancer Institute. National cancer stat facts: Female breast cancer. Available at: <https://seer.cancer.gov/statfacts/html/breast.html> (Accessed: 7 November 2023).
- Duggan C, Trapani D, Ilbawi AM, et al. National health system characteristics, breast cancer stage at diagnosis, and breast cancer mortality: A population-based analysis. *Lancet Oncol.* 2021;22(11):1632-42. [https://doi.org/10.1016/S1470-2045\(21\)00462-9](https://doi.org/10.1016/S1470-2045(21)00462-9) PMID:34653370
- Harbeck N, Penault-Llorca F, Cortes J, et al. Breast cancer. *Nat Rev Dis Primers.* 2019;5(1):66. <https://doi.org/10.1038/s41572-019-0111-2> PMID:31548545
- Cardoso F, Paluch-Shimon S, Senkus E, et al. 5<sup>th</sup> ESO-ESMO international consensus guidelines for advanced breast cancer (ABC 5). *Ann Oncol.* 2020;31(12):1623-49.
- Fietz T, Tesch H, Rauh J, et al. Palliative systemic therapy and overall survival of 1,395 patients with advanced breast cancer—Results from the prospective German TMK cohort study. *Breast.* 2017;34:122-30. <https://doi.org/10.1016/j.breast.2017.05.014> PMID:28586735
- Gobbini E, Ezzalfani M, Dieras V, et al. Time trends of overall survival among metastatic breast cancer patients in the real-life ESME cohort. *Eur J Cancer.* 2018;96:17-24. <https://doi.org/10.1016/j.ejca.2018.03.015> PMID:29660596
- Deluche E, Antoine A, Bachelot T, et al. Contemporary outcomes of metastatic breast cancer among 22,000 women from the multicentre ESME cohort 2008-2016. *Eur J Cancer.* 2020;129:60-70. <https://doi.org/10.1016/j.ejca.2020.01.016> PMID:32135312
- Menes TS, Coster D, Coster D. Contribution of clinical breast exam to cancer detection in women participating in a modern screening program. *BMC Womens Health.* 2021; 21(1):368. <https://doi.org/10.1186/s12905-021-01507-x> PMID:34666735 PMCid:PMC8524962
- Niell BL, Freer PE, Weinfurter RJ, et al. Screening for breast cancer. *Radiol Clin North Am.* 2017;55(6):1145-62. <https://doi.org/10.1016/j.rcl.2017.06.004> PMID:28991557
- Schünemann HJ, Lerda D, Quinn C, et al. Breast cancer screening and diagnosis: A synopsis of the European breast guidelines. *Ann Intern Med.* 2020;172(1):46-56. <https://doi.org/10.7326/M19-2125> PMID:31766052
- Stefanopol IA, Baroiu L, Neagu AI, et al. Clinical, imaging, histological and surgical aspects regarding giant paraovarian cysts: A systematic review. *Ther Clin Risk Manag.* 2022;18:513-22. <https://doi.org/10.2147/TCRM.S361476> PMID:35516165 PMCid:PMC9064068
- Moy L, Heller SL, Bailey L, et al. ACR appropriateness criteria<sup>®</sup> palpable breast masses. *J Am Coll Radiol.* 2017; 14(5S):S203-24. <https://doi.org/10.1016/j.jacr.2017.02.033> PMID:28473077
- Vasile CI, Vasile MC, Zlati ML, et al. Post COVID-19 infection psychosis: Could SARS-CoV-2 virus infection be a neuropsychiatric condition that triggers psychotic disorders?—A case-based short review. *Infect Drug Resist.* 2022;15:4697-705. <https://doi.org/10.2147/IDR.S373578> PMID:36034176 PMCid:PMC9416515
- D’Orsi CJ SE, Mendelson EB, Morris EA, et al. ACR BI-RADS atlas, breast imaging reporting and data system. Reston, (VA): American College of Radiology; 2013.
- Ikeda D, Miyake KK. Breast imaging: The requisites. St. Louis (MI): Elsevier; 2017.
- Steyerova P, Burgetova A. Current imaging techniques and impact on diagnosis and survival—A narrative review. *Ann Breast Surg.* 2021;6. <https://doi.org/10.21037/abs-21-22>
- Hooley RJ, Scoutt LM, Philpotts LE. Breast ultrasonography: State of the art. *Radiology.* 2013; 268(3):642-59. <https://doi.org/10.1148/radiol.13121606> PMID:23970509
- American College of Radiology. ACR practice parameter for the performance of contrast-enhanced magnetic resonance imaging (MRI) of the breast. Available at: <https://www.acr.org/-/media/acr/files/practice-parameters/mr-contrast-breast.pdf> (Accessed: 7 November 2023).
- Mann RM, Cho N, Moy L. Breast MRI: State of the art. *Radiology.* 2019;292(3):520-36. <https://doi.org/10.1148/radiol.2019182947> PMID:31361209
- Plana MN, Carreira C, Muriel A, et al. Magnetic resonance imaging in the preoperative assessment of patients with primary breast cancer: Systematic review of diagnostic accuracy and meta-analysis. *Eur Radiol.* 2012;22(1):26-38. <https://doi.org/10.1007/s00330-011-2238-8> PMID:21847541

21. Bick U, Trimboli RM, Athanasiou A, et al. Image-guided breast biopsy and localisation: Recommendations for information to women and referring physicians by the European Society of Breast Imaging. *Insights Imaging*. 2020;11(1):12. <https://doi.org/10.1186/s13244-019-0803-x> PMID:32025985 PMCid:PMC7002629
22. Spencer PS, Helm TN. Skin metastases in cancer patients. *Cutis*. 1987;39(2):119-21.
23. Krathen RA, Orengo IF, Rosen T. Cutaneous metastasis: A meta-analysis of data. *South Med J*. 2003;96(2):164-7. <https://doi.org/10.1097/01.SMJ.0000053676.73249.E5> PMID:12630642
24. Brownstein MH, Helwig EB. Metastatic tumors of the skin. *Cancer*. 1972;29(5):1298-307. [https://doi.org/10.1002/1097-0142\(197205\)29:5<1298::AID-CNCR2820290526>3.0.CO;2-6](https://doi.org/10.1002/1097-0142(197205)29:5<1298::AID-CNCR2820290526>3.0.CO;2-6) PMID:4336632
25. Wong CY, Helm MA, Kalb RE, Helm TN, Zeitouni NC. The presentation, pathology, and current management strategies of cutaneous metastasis. *N Am J Med Sci*. 2013; 5(9):499-504. <https://doi.org/10.4103/1947-2714.118918> PMID:24251266 PMCid:PMC3818821
26. Lookingbill DP, Spangler N, Sexton FM. Skin involvement as the presenting sign of internal carcinoma. A retrospective study of 7316 cancer patients. *J Am Acad Dermatol*. 1990; 22(1):19-26. [https://doi.org/10.1016/0190-9622\(90\)70002-Y](https://doi.org/10.1016/0190-9622(90)70002-Y) PMID:2298962
27. Lookingbill DP, Spangler N, Helm KF. Cutaneous metastases in patients with metastatic carcinoma: A retrospective study of 4020 patients. *J Am Acad Dermatol*. 1993;29(2 Pt 1):228-36. [https://doi.org/10.1016/0190-9622\(93\)70173-Q](https://doi.org/10.1016/0190-9622(93)70173-Q) PMID:8335743
28. De Giorgi V, Grazzini M, Alfaioli B, et al. Cutaneous manifestations of breast carcinoma. *Dermatol Ther*. 2010;23(6):581-9. <https://doi.org/10.1111/j.1529-8019.2010.01365.x> PMID:21054704
29. Mordenti C, Peris K, Concetta Fagnoli M, et al. Cutaneous metastatic breast carcinoma. *Acta Dermatovenerologica*. 2000;9(4):143-8.
30. Nwabudike LC, Tatu AL. Magistral prescription with silver nitrate and peru balsam in difficult-to-heal diabetic foot ulcers. *Am J Ther*. 2018;25(6):e679-80. <https://doi.org/10.1097/MJT.0000000000000622> PMID:28614088
31. Mullinax K, Cohen JB. Carcinoma en cuirasse presenting as keloids of the chest. *Dermatol Surg*. 2004;30(2 Pt 1):226-8. <https://doi.org/10.1111/j.1524-4725.2004.30071.x> PMID:14756657
32. Carlesimo M, Rossi A, De Marco G, et al. Carcinoma en cuirasse of the breast. *Eur J Dermatol*. 2009;19:289-0. <https://doi.org/10.1684/ejd.2009.0662> PMID:19557891
33. Mallon E, Dawber RP. Alopecia neoplastica without alopecia: A unique presentation of breast carcinoma scalp metastasis. *J Am Acad Dermatol*. 1994;31(2 Pt 2):319-21. [https://doi.org/10.1016/S0190-9622\(94\)70163-6](https://doi.org/10.1016/S0190-9622(94)70163-6) PMID:8034796
34. Valencia IC, Colsky A, Berman B. Multicentric reticulohistiocytosis associated with recurrent breast carcinoma. *J Am Acad Dermatol*. 1998;39(5 Pt 2):864-6. [https://doi.org/10.1016/S0190-9622\(98\)70367-6](https://doi.org/10.1016/S0190-9622(98)70367-6) PMID:9810917
35. Bennàssar A, Mas A, Guilbert A, Julià M, Mascaró-Galy JM, Herrero C. Multicentric reticulohistiocytosis with elevated cytokine serum levels. *J Dermatol*. 2011;38(9):905-10. <https://doi.org/10.1111/j.1346-8138.2010.01146.x> PMID:21658110
36. Gore M, Winters ME. Erythema gyratum repens: A rare paraneoplastic rash. *West J Emerg Med*. 2011;12(4):556-8. <https://doi.org/10.5811/westjem.2010.11.2090> PMID:22224159 PMCid:PMC3236141
37. Niculet E, Bobeica C, Tatu AL. Glucocorticoid-induced skin atrophy: The old and the new. *Clin Cosmet Investig Dermatol*. 2020;13:1041-50. <https://doi.org/10.2147/CCID.S224211> PMID:33408495 PMCid:PMC7779293
38. Pectasides D, Koumpou M, Gaglia A, et al. Dermatomyositis associated with breast cancer. *Anticancer Res*. 2006;26:2329-31.
39. Sandhu NP, Zakaria S, Degnim AC, Boughey JC. Dermatomyositis presenting as a paraneoplastic syndrome due to underlying breast cancer. *BMJ Case Rep*. 2011;2011:bcr1020103416. <https://doi.org/10.1136/bcr.10.2010.3416> PMID:22714621 PMCid:PMC3062365
40. Richardson JB, Callen JP. Dermatomyositis and malignancy. *Med Clin North Am*. 1989;73(5):1211-20. [https://doi.org/10.1016/S0025-7125\(16\)30629-0](https://doi.org/10.1016/S0025-7125(16)30629-0) PMID:2671542
41. Vulink AJE, ten Bokkel Huinink D. Acquired hypertrichosis lanuginosa: A rare cutaneous paraneoplastic syndrome. *J Clin Oncol*. 2007;25(12):1625-6. <https://doi.org/10.1200/JCO.2007.10.6963> PMID:17443005
42. Pilarski R, Burt R, Kohlman W, et al. Cowden syndrome and the PTEN hamartoma tumor syndrome: Systematic review and revised diagnostic criteria. *J Natl Cancer Inst*. 2013;105(21):1607-16. <https://doi.org/10.1093/jnci/djt277> PMID:24136893
43. National Comprehensive Cancer Network. Genetic/familial high-risk assessment: Breast and ovarian. Available at: [http://www.nccn.org/professionals/physician\\_gls/pdf/genetics\\_screening.pdf](http://www.nccn.org/professionals/physician_gls/pdf/genetics_screening.pdf) (Accessed: 7 November 2023).
44. Rojas K, Stuckey A. Breast cancer epidemiology and risk factors. *Clin Obstet Gynecol*. 2016;59(4):651-72. <https://doi.org/10.1097/GRF.0000000000000239> PMID:27681694
45. Souto LRM. Invited discussion on: The impact of reconstructive modality and postoperative complications on decision regret and patient-reported outcomes. *Aesthetic Plast Surg*. 2022;46(2):661-6. <https://doi.org/10.1007/s00266-021-02706-5> PMID:35031824
46. Boccola MA, Savage J, Rozen WM, et al. Surgical correction and reconstruction of the nipple-areola complex: Current review of techniques. *J Reconstr Microsurg*. 2010;26(9):589-600. <https://doi.org/10.1055/s-0030-1263290> PMID:20721849
47. Butler PD, Plana NM, Hastings AL. Finishing touches: Expanding access to nipple-areola tattooing as a component of postmastectomy breast reconstruction. *Plast Reconstr Surg Glob Open*. 2019;7(11):e2558. <https://doi.org/10.1097/GOX.0000000000002558> PMID:31942320 PMCid:PMC6908362
48. Stoller AJ, Sullivan SK, Dellacroce FJ. Technical considerations in nipple-sparing mastectomy: 82 consecutive cases without necrosis. *Ann Surg Oncol*. 2008;15(5):1341-7. <https://doi.org/10.1245/s10434-007-9753-5> PMID:18256883
49. Agarwal S, Pappas L, Neumayer L, Kokeny K, Agarwal J. Effect of breast conservation therapy vs mastectomy on disease-specific survival for early-stage breast cancer. *JAMA Surg*. 2014;149(3):267-74. <https://doi.org/10.1001/jamasurg.2013.3049> PMID:24429935

50. van Maaren MC, de Munck L, de Bock GH, et al. 10 year survival after breast-conserving surgery plus radiotherapy compared with mastectomy in early breast cancer in the Netherlands: A population-based study. *Lancet Oncol.* 2016;17(8):1158-70. [https://doi.org/10.1016/S1470-2045\(16\)30067-5](https://doi.org/10.1016/S1470-2045(16)30067-5) PMID:27344114
51. Hartmann-Johnsen OJ, Kåresen R, Schlichting E, Nygård JF. Survival is better after breast conserving therapy than mastectomy for early stage breast cancer: A registry-based follow-up study of Norwegian women primary operated between 1998 and 2008. *Ann Surg Oncol.* 2015;22(12):3836-45. <https://doi.org/10.1245/s10434-015-4441-3> PMID:25743325 PMCID:PMC4595537
52. Corradini S, Bauerfeind I, Belka C, et al. Trends in use and outcome of postoperative radiotherapy following mastectomy: A population-based study. *Radiother Oncol.* 2017;122(1):2-10. <https://doi.org/10.1016/j.radonc.2016.08.018> PMID:27641786
53. Gu J, Groot G, Holtslander L, Engler-Stringer R. Understanding women's choice of mastectomy versus breast conserving therapy in early-stage breast cancer. *Clin Med Insights Oncol.* 2017;11:1179554917691266. <https://doi.org/10.1177/1179554917691266> PMID:28469511 PMCID:PMC5395266
54. Lee WQ, Tan VKM, Choo HMC, et al. Factors influencing patient decision-making between simple mastectomy and surgical alternatives. *BJS Open.* 2018;3(1):31-7. <https://doi.org/10.1002/bjs.5.50105> PMID:30734013 PMCID:PMC6354187
55. Shaverdian N, Wang X, Hegde JV, et al. The patient's perspective on breast radiotherapy: Initial fears and expectations versus reality. *Cancer.* 2018;124(8):1673-81. <https://doi.org/10.1002/cncr.31159> PMID:29479673
56. Agarwal S, Agarwal S, Neumayer L, Agarwal JP. Therapeutic nipple-sparing mastectomy: Trends based on a national cancer database. *Am J Surg.* 2014;208(1):93-8. <https://doi.org/10.1016/j.amjsurg.2013.09.030> PMID:24581994
57. Sisco M, Kyrillos AM, Lapin BR, Wang CE, Yao KA. Trends and variation in the use of nipple-sparing mastectomy for breast cancer in the United States. *Breast Cancer Res. Treat.* 2016;160(1):111-20. <https://doi.org/10.1007/s10549-016-3975-9> PMID:27620883
58. Li M, Chen K, Liu F, Su F, Li S, Zhu L. Nipple sparing mastectomy in breast cancer patients and long-term survival outcomes: An analysis of the SEER database. *PLoS One.* 2017;12(8):e0183448. <https://doi.org/10.1371/journal.pone.0183448> PMID:28841691 PMCID:PMC5571910
59. Poortmans, PMP, Arenas M, Livi L. Over-irradiation. *Breast.* 2017;31:295-302. <https://doi.org/10.1016/j.breast.2016.07.022> PMID:27522160
60. Matros E, Shamsunder M, Disa JJ. The effect of the breast cancer provider discussion law on breast reconstruction rates in New York State. *Plast Reconstr Surg.* 2019;144(3):569-70. <https://doi.org/10.1097/PRS.0000000000005905> PMID:31461003 PMCID:PMC6755661
61. Pusic AL, Matros E, Fine N, et al. Patient-reported outcomes 1 year after immediate breast reconstruction: Results of the mastectomy reconstruction outcomes consortium study. *J Clin Oncol.* 2017;35(22):2499-506. <https://doi.org/10.1200/JCO.2016.69.9561> PMID:28346808 PMCID:PMC5536162
62. Nguyen AT, Chang DW. Discussion: A paradigm shift in U.S. breast reconstruction: Increasing implant rates. *Plast Reconstr Surg.* 2013;131(1):24-5. <https://doi.org/10.1097/PRS.0b013e3182729d83> PMID:23271516
63. Albornoz CR, Bach PB, Mehrara BJ, et al. A paradigm shift in U.S. breast reconstruction: Increasing implant rates. *Plast Reconstr Surg.* 2013;131(1):15-23. <https://doi.org/10.1097/PRS.0b013e3182729cde> PMID:23271515
64. Overgaard M, Hansen PS, Overgaard J, et al. Postoperative radiotherapy in high-risk premenopausal women with breast cancer who receive adjuvant chemotherapy: Danish breast cancer cooperative group 82b trial. *N Engl J Med.* 1997;337(14):949-55. <https://doi.org/10.1056/NEJM199710023371401> PMID:9395428
65. Overgaard M, Jensen MB, Overgaard J, et al. Postoperative radiotherapy in high-risk postmenopausal breast-cancer patients given adjuvant tamoxifen: Danish breast cancer cooperative group DBCG 82c randomised trial. *Lancet.* 1999;353(9165):1641-8. [https://doi.org/10.1016/S0140-6736\(98\)09201-0](https://doi.org/10.1016/S0140-6736(98)09201-0) PMID:10335782
66. EBCTCG (Early Breast Cancer Trialists' Collaborative Group), McGale P, Taylor C, et al. Effect of radiotherapy after mastectomy and axillary surgery on 10-year recurrence and 20-year breast cancer mortality: Metaanalysis of individual patient data for 8135 women in 22 randomised trials. *Lancet.* 2014;383(9935):2127-35. [https://doi.org/10.1016/S0140-6736\(14\)60488-8](https://doi.org/10.1016/S0140-6736(14)60488-8)
67. Ragaz J, Jackson SM, Le N, et al. Adjuvant radiotherapy and chemotherapy in node-positive premenopausal women with breast cancer. *N Engl J Med.* 1997;337(14):956-62. <https://doi.org/10.1056/NEJM199710023371402> PMID:9309100
68. Frasier LL, Holden S, Holden T, et al. Temporal trends in postmastectomy radiation therapy and breast reconstruction associated with changes in national comprehensive cancer network guidelines. *JAMA Oncol.* 2016;2(1):95-101. <https://doi.org/10.1001/jamaoncol.2015.3717> PMID:26539936 PMCID:PMC4713236
69. Poppe MM, Agarwal JP. Breast reconstruction with postmastectomy radiation: Choices and tradeoffs. *J Clin Oncol.* 2017;35(22):2467-70. <https://doi.org/10.1200/JCO.2017.72.7388> PMID:28481705
70. Alderman AK, Wilkins EG, Kim HM, et al. Complications in postmastectomy breast reconstruction: Two-year results of the Michigan breast reconstruction outcome study. *Plast Reconstr Surg.* 2002;109(7):2265-74. <https://doi.org/10.1097/00006534-200206000-00015> PMID:12045548
71. Benediktsson K, Perbeck L. Capsular contracture around saline-filled and textured subcutaneously-placed implants in irradiated and nonirradiated breast cancer patients: Five years of monitoring of a prospective trial. *J Plast Reconstr Aesthet Surg.* 2006;59(1):27-34. <https://doi.org/10.1016/j.bjps.2005.08.005> PMID:16482787
72. Whitfield GA, Horan G, Irwin MS, et al. Incidence of severe capsular contracture following implant-based immediate breast reconstruction with or without postoperative chest wall radiotherapy using 40 gray in 15 fractions. *Radiother Oncol.* 2009;90(1):141-7. <https://doi.org/10.1016/j.radonc.2008.09.023> PMID:18977547
73. Christante D, Pommier SJ, Samuelson BT, et al. Using complications associated with postmastectomy radiation and immediate breast reconstruction to improve surgical decision making. *Arch Surg.* 2010;145(9):873-8. <https://doi.org/10.1001/archsurg.2010.170> PMID:20855758



- 
74. Fowble B, Park C, Wang F, et al. Rates of reconstruction failure in patients undergoing immediate reconstruction with tissue expanders and/or implants and postmastectomy radiation therapy. *Int J Radiat Oncol Biol Phys.* 2015;92(3):634-41. <https://doi.org/10.1016/j.ijrobp.2015.02.031> PMID:25936815