




Report of two cases of acute appendicitis prior to exams in medical students using OpenAI's ChatGPT

Jeel Moya-Salazar^{1*} , Carmen R Salazar² , Eliane A Goicochea-Palomino³ 

¹Faculties of Health Science, Universidad Privada del Norte, Lima, PERU

²Qualitative Unit, Nesh Hubbs, Lima, Peru, PERU

³Faculties of Health Science, Universidad Tecnológica del Perú, Lima, PERU

*Corresponding Author: jeel.moya@upn.edu.pe

Citation: Moya-Salazar J, Salazar CR, Goicochea-Palomino EA. Report of two cases of acute appendicitis prior to exams in medical students using OpenAI's ChatGPT. *Electron J Gen Med.* 2024;21(3):em585. <https://doi.org/10.29333/ejgm/14571>

ARTICLE INFO

Received: 20 Jun. 2023

Accepted: 17 Apr. 2024

ABSTRACT

Introduction: Acute appendicitis (AA) is a significant cause of emergency admissions among university students aged over 20 years. Students experience high demands during their undergraduate studies, often leading them to postpone mealtimes or rest breaks. Here, with the assistance of ChatGPT, we present two cases of medical students with AA who delayed their surgical treatment due to exams.

Clinical cases: Two young patients (a 23-year-old female and a 20-year-old male) presented with severe abdominal pain, anorexia, and general discomfort. They had high C-reactive protein levels and white blood cell counts, as well as an ultrasound showing an enlarged appendix. Despite the confirmed diagnosis of appendicitis through abdominal ultrasound, both patients decided to postpone hospitalization and surgery due to university exams. They subsequently underwent uncomplicated emergency laparoscopic appendectomy. The clinical report of both cases was successfully addressed with ChatGPT, using the initial data from the medical record, and coherent discussions regarding patient management and follow-up were generated.

Conclusions: The surgical intervention applied in both cases of AA was successful, and although both patients recovered without issues, delaying surgery can increase the risk of complications. It is necessary to educate the university population about the importance of immediate medical attention for the treatment of AA. ChatGPT appears to be a useful tool for organizing clinical information and improving discussions on therapeutic management.

Keywords: appendicitis, appendectomy, artificial intelligence, inflammation, ChatGPT, abdominal pain

INTRODUCTION

Acute appendicitis (AA) is an obstruction in the appendiceal lumen that results in edema, causing abdominal pain, fever, and anorexia. Laparoscopic appendectomy (LA) is the most effective treatment if performed early, but if the inflammation progresses, postoperative complications such as intra-abdominal abscess, surgical reintervention, among others, can occur [1].

AA is a common condition among university students. In the US, 297 (10.0%) students from Coe College who underwent appendectomy were reported over an eight-year period [2]. Additionally, at Northwestern University, 153 cases of AA were registered in a similar period, with a predominance in male students and symptoms such as constant, dull, and diffuse abdominal pain. The majority of patients (78.2%) were operated on within 24 hours, which prevented the occurrence of complications [3]. Early diagnosis and LA are therefore crucial in preventing complications.

OpenAI's ChatGPT emerged in late 2022 as a disruptive open-access tool that is improving healthcare and promoting scientific research in all fields [4]. In addition to providing

alternatives in medical diagnosis in radiology [5] and ophthalmology [6], this LLM tool also appears to be useful for case reporting [7]. While its advantages in constructing clinical case reports have been previously defined [8], its potential in narrative construction during patient interviews and the comparison of its reporting attributes with those of a human healthcare professional have not been evaluated.

Here, we describe the experience of two patients with AA who underwent LA prior to a medical exam in Peru. This report is warranted because of high-stress academic settings on medical students as has been reported in several studies [9, 10]. It is conceivable that the psychological strain experienced by medical students may affect their overall health, potentially leading to various health issues [11].

Additionally, we compared the clinical reports of each case and utilized a qualitative approach to evaluate the patient's experience. We used an additional qualitative approach to the case report because the phenomenological approach to the postponement of symptoms due to university exams is essential to understanding of the environment in which they occur.

Finally, an analysis of ChatGPT's interpretation is performed based on transcripts from each interview following the guidelines of the CARE [12] and COREQ [13] guidelines.

CLINICAL CASE

Patient 1

A 23-year-old woman residing in Lima, fully vaccinated and without any known risk factors for chronic diseases. As a sixth-year medical student, she denies any history of tobacco use, drug use, or consumption of energizers. Furthermore, there is no family history of autoimmune diseases. Her chief complaints include progressive pain in the right hypochondrium, extending to umbilical region, accompanied by anorexia and general discomfort. These symptoms surfaced during her gynecology externship. She also presented with nausea and progressive headache. Her medical record included a previous surgery on her lower limb for a torn anterior cruciate ligament at the age of eight, with no known allergies or prior hospitalizations. She reported experiencing symptoms after a 12-hour shift, which prompted her to rest in the hospitalization area for three hours starting at 11 am.

"I thought it was the start of my menstruation and it was also because of being tired after my shift; that's why I did not pay attention and I said to myself it is going to pass."

After getting up from the bed and descending from the examination table, she felt more intense abdominal pain. She

Table 1. Main laboratory findings in students with acute appendicitis

Laboratory test	Evaluation*	Patient 1	Patient 2
PCR (0-10 mg)	1	11.1	2.7
	2	23.8	34.8
	3	-	10.1
Leukocyte count (cel/mm ³)	1	8.300	7.450
	2	16.713	23.200
	3	-	12.130

Note. *First evaluation was due to suspected AA; second was on day of surgical intervention (patient 1); & patient 2 was evaluated during hospitalization (evaluation 2) & after surgery (evaluation 3)

called her colleagues who informed the resident in charge of the rotation. Physical examination revealed suspected AA based on progressive pain and positive Murphy's and Blumberg's signs. Blood pressure (BP) was 110/60 mmHg, respiratory rate (RR) was 26 breaths per minute, oxygen saturation was 98.0%, heart rate (HR) was 70 beats per minute, and Glasgow coma scale score was 15/15. Laboratory tests were requested (**Table 1**), and an abdominal ultrasound showed increased echogenicity adjacent to the presence of a fecalith, confirming AA. Despite the diagnosis, the patient refused hospitalization and surgical management due to having a final exam for the course in a few hours, stating that she would return later.

The report assisted by ChatGPT based on the initial data without abbreviations entered the prompt before requesting the writing of the clinical report is shown in **Table 2**.

"When I arrived at the university, it was difficult for me to go upstairs to take the exam. To my misfortune, they

Table 2. Clinical report of patient 1 using ChatGPT



Answer 1	Could you write a 200-word medical history on following text?
	<p>A 23-year-old woman, a sixth-year medical student, presented with progressive pain in the right hypochondrium that extended to the navel, anorexia, and general malaise during her gynecology externship. She also experienced symptoms of nausea and progressive headache. Her past medical history includes a lower limb surgery for cruciate ligament rupture at the age of 8, and she has no known allergies or previous hospitalizations.</p> <p>The onset of symptoms occurred after 12 hours of duty during her externship. As a result, she was allowed to rest in the hospitalization area for 3 hours at 11 am. Upon getting up from the stretcher, she experienced intensified abdominal pain, leading her to seek assistance from her colleagues, who informed the resident in charge of the rotation.</p> <p>During the physical examination, acute appendicitis was suspected due to the progressive pain and positive Murphy and Bloomberg signs. Vital signs were stable, with a blood pressure (BP) of 110/60, respiratory rate (RR) of 26 rpm, 98% oxygen saturation, heart rate (HR) of 70 bpm, and Glasgow Coma Scale score of 15/15. To confirm the diagnosis, laboratory tests were requested (see Table 1), and an abdominal ultrasound revealed adjacent increased echogenicity with the presence of a fecalith, confirming the diagnosis of acute appendicitis.</p> <p>Despite the diagnosis, the patient refused hospitalization and surgical management because she had a final exam for her course in a few hours. She stated that she would return for further management after completing her exam.</p>

Table 3. Qualitative description of history of process of patient 1's disorder using ChatGPT

Answer 2	Could you write a 200-word summary of following transcript of a patient's story?
	<p>The patient shared their story, recounting their experience during college when they faced difficulties due to appendicitis. They struggled to climb the stairs to reach the exam venue but had the misfortune of finding out that the location had been changed. Having to descend the stairs again caused even more pain. When the teacher noticed their discomfort, the classmates informed the teacher about the patient's condition, stating that they had appendicitis. The teacher expressed concern and suggested that they should not be present in such a state. However, the patient insisted on taking the exam and then undergoing surgery. Eventually, the teacher decided to accompany them to the hospital.</p> <p>During the taxi ride, every bump on the road caused excruciating pain for the patient. They were accompanied by their mother and returned from the hospital crying due to the intensity of the pain. Upon arrival at the emergency room, the patient felt remorseful and described their state as pitiful. However, their surgery was delayed when an emergency neurosurgery was prioritized for a child injured by a fallen television. The patient had to endure two more hours of agony before finally being operated on, feeling unable to bear the pain or even breathe properly. They attributed the delay to their own negligence.</p> <p>Overall, the patient's account reflects their determination to fulfill their academic obligations despite suffering from appendicitis, as well as the challenges and delays they faced in receiving the necessary medical attention.</p>

changed the exam location. I had to go downstairs again, and the pain worsened. The professor asked me, 'What's wrong with you?' And my classmates said, 'She says she has appendicitis!' The professor said, 'oh dear!' (...) 'How could you be here?' I replied, 'I'll take my exam and then I'll go for surgery.' Eventually, he took me to the hospital. In the taxi, 'I saw stars with every bump.' I went with my mother, and I returned crying from the pain. I arrived at the emergency department like a remorseful dog (...) and just as they were about to operate on me, a TV had fallen on a child, and they rushed him to emergency neurosurgery. So, I waited for another two hours. I could not bear the pain anymore; I could not even breathe. They operated on me three hours later, but it was all my own negligence."

As patient 1 describes, medical students may face additional pressure to perform well on exams, even disregarding their health status to meet the demands of the medical program. The qualitative report assisted by ChatGPT is shown in **Table 3**.

Patient 2

A 20-year-old sixth-year medical student is admitted to the hospital ER for reporting progressive abdominal pain for the past five days, which was partially relieved with nonsteroidal anti-inflammatory drugs. He has received all required immunizations and occasionally consumes alcohol socially. He reports no use of drugs or tobacco in the past semester. He is undergoing of a family member (uncle) with AA undergoing emergency surgery and his mother has GERD. There is no recent history of travel to endemic areas and currently works on weekends in sales.

In admission other symptoms included general discomfort and anorexia. On physical examination, he exhibited the Cope's triad (vomiting, abdominal pain, and febrile syndrome) with a BP of 120/60 mmHg, RR of 28 breaths per minute, oxygen saturation of 97.0%, HR of 80 beats per minute, and Glasgow coma scale score of 15/15. He had no significant medical history, and his COVID-19 test result was negative. Two days before admission, during his pre-hospital clinical practice, he had a C-reactive protein level of 2.7 mg/dL and a complete blood count of 7,450 leukocytes/mm³.

Due to suspicion of AA, an emergency evaluation was performed, which showed positive Murphy's and Blumberg's signs. Abdominal ultrasound revealed an increased caliber of the cecal appendix measuring 9 mm without the presence of a fecalith. Despite the diagnosis, the patient refused surgical intervention due to being in "exam week" and signed a voluntary discharge form.

"I had to wait for five days, from Tuesday to Saturday, because I had a difficult internal medicine exam. My cousin, who is a nurse, told me, 'It's not appendicitis,' and gave me pain pills. But I already knew that's what it was, and I felt like it was about to burst, I was on the verge of peritonitis. The exam was also difficult, the professor was strict and would not allow rescheduling (...) Apparently, the pandemic changed my diet, and I had a high consumption of fats and sugary drinks. Also, virtual classes had us sitting in front of the computer all day without moving. I think all of that affected me."

Table 4. Clinical report of patient 2 using ChatGPT



Answer 1	Could you write a 200-word medical history on following text?
	<p>The patient is a 20-year-old male, a fifth-year medical student, who has been experiencing progressive abdominal pain for the past 5 days. The pain is relieved by non-steroidal anti-inflammatory drugs. Additionally, he complains of malaise and anorexia. On physical examination, the patient presents with a cope triad consisting of vomiting, abdominal pain, and a febrile syndrome. His blood pressure is 120/60 mmHg, respiratory rate is 28 breaths per minute, oxygen saturation is 97%, heart rate is 80 beats per minute, and Glasgow Coma Scale score is 15 out of 15. The patient has no significant medical history and has tested negative for COVID-19.</p> <p>Two days prior to admission, while on his pre-hospital practices, the patient underwent evaluation which revealed a C-Reactive Protein level of 2.7 mg/dl and a complete blood count showing 7450 leukocytes/mm³. Suspecting acute appendicitis, an emergency assessment was performed, confirming the diagnosis with positive Murphy and Bloomberg signs. An abdominal ultrasound showed an enlarged cecal appendix measuring 9 mm, without the presence of a fecalith.</p> <p>Despite the diagnosis, the patient expressed his refusal for surgical intervention due to being in the midst of "exam week" and voluntarily signed an informed consent, opting against immediate surgical management.</p>

Table 5. Qualitative description of history of process of patient 2's disorder using ChatGPT

Answer 2	Could you write a 200-word summary of following transcript of a patient's story?
	<p>The patient explains that they experienced abdominal pain but had to wait for five days, from Tuesday to Saturday, because they had a challenging internal medicine exam. Their cousin, who is a nurse, believed it was not appendicitis and provided them with pain medication. However, the patient was convinced that they had appendicitis and felt as if their appendix was about to rupture, potentially leading to peritonitis. Despite their condition, the patient was determined not to reschedule the exam, as the teacher was strict and would not accept any changes.</p> <p>The patient reflects on possible factors that could have contributed to their condition. They mention changes in their diet, with a high consumption of fats and sugary drinks, possibly influenced by the pandemic. Additionally, the transition to virtual classes required prolonged periods of sitting in front of a computer without much movement. The patient speculates that these lifestyle changes may have had an impact on their health.</p>

Case report and qualitative analysis of patient 2 are shown in **Table 4** and **Table 5**. Both cases were urgently taken to the hospital without taking the medicine course exam, which led to postponing their hospitalization and surgery. Both patients underwent AL and antibiotic therapy, and their recovery was free of complications at the three-month follow-up.

COMMENTARIES

Non-Artificial Intelligence Discussion on Management of Appendicitis

AA is a painful, progressive, and highly prevalent condition [14]. Most cases are of a "non-complicated" nature and can be treated without surgery. However, after 72 hours from the onset of symptoms, the risk of perforation increases significantly [15, 16]. This risk depends not only on the timing of intervention (**Figure 1**) but also on early identification of complicated appendicitis, access to medical care, microbial

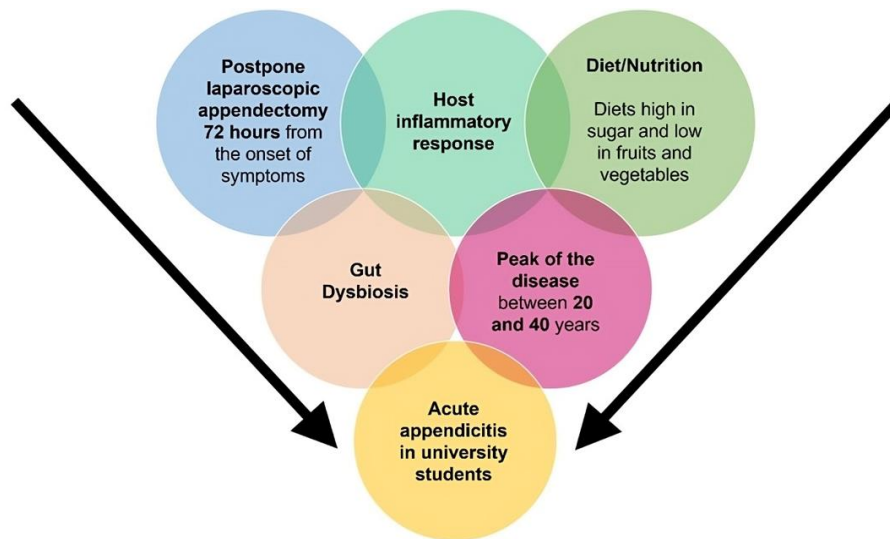


Figure 1. Factors conducive to appendicitis in university students (Source: Authors, ©Jeel Moya-Salazar)

composition, and inflammatory response [14]. Open appendectomy was first described in 1894 by McBurney, who made an incision in the abdomen to remove the appendix [17]. In 1981, Semm performed the first AL, using three trocars to examine the abdominal cavity, confirm the diagnosis of AA, and aspirate the appendix [18].

Currently, AL can be performed through a single incision and is preferred over open appendectomy due to its effectiveness in reducing infections, shorter hospital stay, and lower readmission rates [19]. It has also been successful in adults and children with uncomplicated appendicitis [20].

AL is associated with faster recovery and less postoperative pain [21], allowing pediatric patients with complicated AA to be discharged earlier than those undergoing open appendectomy [22]. However, age, surgical time, diagnosis of complicated appendicitis, and being a female may prolong postoperative hospitalization time [22]. It has been shown that women have a slower and lower-quality recovery from general anesthesia due to pharmacological interactions of progesterone and estrogenic hormones [23].

The demographic characteristics of the reported patients coincide with the peak age for AA (20-40 years) [24]. This age group has few abdominal surgeries other than appendectomy [2], with age being a common factor. It is important to note that in both cases, surgical intervention was delayed due to preparation for university medical exams, which can be attributed to the high academic demands of the medical career and the anxiety it generates [25]. In addition, the restrictions imposed to prevent the spread of COVID-19 and the fear of contracting the virus have influenced the increase in complicated AA cases due to reduced timely surgical care [26]. Furthermore, the pandemic has also led to lifestyle changes affecting nutrition (high intake of sugars and low intake of fruits and vegetables) in the population [24], which is an important risk factor for AA [28]. Therefore, it is necessary to promote the study of AA among university students, given the limited number of reports on this topic [2, 3].

The connection between the two case reports sheds light on the unique challenges faced by medical students in the context of acute health crises. Both patients, despite experiencing symptoms indicative of AA, delayed seeking medical attention due to impending university exams. This

underscores the immense pressure students face to prioritize academic obligations over their health [29, 30]. Patient 1's decision to postpone surgery until after her final exam exemplifies this dilemma, even enduring severe pain during the examination. Similarly, patient 2 rationalized his symptoms to prioritize an internal medicine exam, ultimately delaying treatment.

These cases highlight the need for increased awareness and support for medical students navigating the demanding academic environment while managing their health effectively.

Discussion of Cases Using ChatGPT

1. The presented cases highlight the dilemmas faced by medical students when their health conditions coincide with important academic obligations. The decision to prioritize academic pursuits over surgical intervention raises ethical concerns, as it involves balancing patient autonomy and the duty to provide appropriate medical care. In these situations, clear and empathetic communication is crucial to ensure informed decision-making while considering the potential risks and consequences.
2. Medical institutions should establish policies and support mechanisms to address the unique needs of medical students experiencing health issues during critical academic periods. Flexible scheduling options, such as rescheduling exams or providing academic accommodations, can help alleviate the conflict between medical training and personal health. Collaboration among healthcare professionals, faculty members, and students is essential to ensure a patient-centered approach while acknowledging the students' academic aspirations.

ChatGPT could provide substantial insights into ethical and political considerations by analyzing and elaborating on the ethical dilemmas presented in the text [31]. It could explore various ethical frameworks (i.e., utilitarianism), to evaluate the decision-making process of medical students prioritizing academic obligations over health concerns. Additionally, ChatGPT could discuss the potential impact of institutional policies on student well-being and academic performance, considering factors like patient autonomy, duty of care, and

institutional responsibilities [32]. Furthermore, ChatGPT could delve into the political implications of healthcare policies and institutional practices affecting medical education, highlighting potential disparities in access to healthcare and educational resources. ChatGPT could provide comprehensive analyses and recommendations for addressing these complex issues at the intersection of academia, healthcare, and ethics.

CONCLUSIONS

This case report has demonstrated that the management of AA was successful using methods even with delayed medical attention. However, it is important to highlight the postponement of healthcare by students who prioritize their academic activities. This attitude, on the one hand, can put their lives at risk, and on the other hand, reflects the demands and challenges of medical school. It is crucial to establish emergency care protocols for students in situations of risk or illness, as well as to provide opportunities in educational programs that reduce the impact and pressure on students, offering alternatives for other activities.

It is worth noting that the use of ChatGPT has allowed the reporting of patient cases based using clinical data gathered during medical assessments. Furthermore, this tool has been instrumental in analyzing patient narratives. The generative language model seems beneficial for structuring medical text, enhancing the organization of symptom presentation, and simplifying qualitative analysis derived from participant interviews. However, further research is warranted to assess ChatGPT's efficacy in medicine, case reporting, qualitative research, and clinical decision-making.

Author contributions: **JM-S:** provided study concept & design, data curation & formal analysis, & wrote manuscript; **CRS:** provided design, formal analysis, & visualization, & wrote manuscript; **EAG-P:** provided data acquisition, performed data management, & wrote manuscript. All authors have agreed with the results and conclusions.

Funding: No funding source is reported for this study.

Acknowledgements: The authors would like to thank patients included in this case report. The authors would also like to thank patients for their availability to conduct interviews & support with clinical records.

Ethical statement: The authors stated that the ethical research guidelines were met following the CIOMIS guidelines and the Declaration of Helsinki. Also, informed consent was obtained from each participant for the report of their case.

Declaration of interest: No conflict of interest is declared by authors.

Data sharing statement: Data supporting the findings and conclusions are available upon request from the corresponding author.

REFERENCES

- Di Saverio S, Podda M, De Simone B, et al. Diagnosis and treatment of acute appendicitis: 2020 update of the WSES Jerusalem guidelines. *World J Emerg Surg.* 2020;15(1):27. <https://doi.org/10.1186/s13017-020-00306-3> PMID: 32295644 PMCID:PMC7386163
- Stiles KA, Mulsow FW. Incidencia de apendicitis de una encuesta de estudiantes universitarios [Incidence of appendicitis from a survey of university students]. *Jor DD.* 1946;13:39-40. <https://doi.org/10.1007/BF03002787> PMID: 21015921
- Donald E, Hansen MD. Acute appendicitis; a review of 153 university students with emphasis on early diagnosis. *Q Bull Northwest Univ Med Sch.* 1952;26(4):315-320.
- Dave T, Athaluri SA, Singh S. ChatGPT in medicine: An overview of its applications, advantages, limitations, future prospects, and ethical considerations. *Front Artif Intell.* 2023;6:1169595. <https://doi.org/10.3389/frai.2023.1169595> PMID:37215063 PMCID:PMC10192861
- Bhayana R, Krishna S, Bleakney RR. Performance of ChatGPT on a radiology board-style examination: Insights into current strengths and limitations. *Radiology.* 2023; 307(5):e230582. <https://doi.org/10.1148/radiol.230582> PMID:37191485
- Mihalache A, Popovic MM, Muni RH. Performance of an artificial intelligence chatbot in ophthalmic knowledge assessment. *JAMA Ophthalmol.* 2023;141(6):589-97. <https://doi.org/10.1001/jamaophthalmol.2023.1144> PMID: 37103928
- Raxwal B, Baisla P, Nath J. A collaborative case report utilizing ChatGPT AI technology of traumatic right coronary artery dissection resulting in inferior wall ST-elevation myocardial infarction. *Cureus.* 2023;15(3):e35894. <https://doi.org/10.7759/cureus.35894> PMID:37033522 PMCID:PMC10080982
- Carnielli LM. Cómo hacer que ChatGPT informe historias clínicas por ti [How to have ChatGPT report medical records for you]. Available at: <https://www.linkedin.com/pulse/c%C3%B3mo-hacer-que-chatgpt-informe-historias-cl%C3%ADnicas-por-carnielli/?originalSubdomain=es> (Accessed: 19 June 2023)
- Abdus S, Rabeya Y, Muhammad A, Mainul H. Stress among medical students in malaysia: A systematic review of literatures. *Inter Med J.* 2013;20:649-55.
- Kumar B, Shah M, Kumari R, Kumar A, Kumar J, Tahir A. Depression, anxiety, and stress among final-year medical students. *Cureus.* 2019;11(3):e4257. <https://doi.org/10.7759/cureus.4257>
- Swaminathan A, Viswanathan S, Gnanadurai T, Ayyavoo S, Manickam T. Perceived stress and sources of stress among first-year medical undergraduate students in a private medical college Tamil Nadu. *Natl J Physiol Pharm Pharmacol.* 2016;6(1):9-14. <https://doi.org/10.5455/NJPPP.2015.5.1909201574>
- Riley DS, Barber MS, Kienle GS, et al. CARE guidelines for case reports: Explanation and elaboration document. *J Clin Epidemiol.* 2017;89:218-35. <https://doi.org/10.1016/j.jclinepi.2017.04.026> PMID:28529185
- Tong A, Sainsbury P, Craig J. Consolidated criteria for reporting qualitative research (COREQ): A 32-item checklist for interviews and focus groups. *Int J Qual Health Care.* 2007;19(6):349-57. <https://doi.org/10.1093/intqhc/mzm042> PMID:17872937
- Salminen P. Acute appendicitis incidence-predisposing factors, from microbiota to socioeconomic status? *JAMA Surg.* 2020;155(4):338-9. <https://doi.org/10.1001/jamasurg.2019.6031> PMID:32129802
- Jiang L, Liu Z, Tong X, et al. Does the time from symptom onset to surgery affect the outcomes of patients with acute appendicitis? A prospective cohort study of 255 patients. *Asian J Endos Surg.* 2020;14(3):361-7. <https://doi.org/10.1111/ases.12870> PMID:32996273

16. Elniel M, Grainger J, Nevins EJ, Misra N, Skaife P. 72 h is the time critical point to operate in acute appendicitis. *J Gastrointest Surg.* 2018;22(2):310-5. <https://doi.org/10.1007/s11605-017-3614-8> PMID:29086150
17. Martínez MG, Reyes DHE. Charles Heber McBurney: La incisión, el punto y el cirujano [Charles Heber McBurney: The incision, the point and the surgeon]. *Cir Gen.* 2007;29(1):70-5.
18. Langberg A, Montoya JC, Cevallos M. Apendicectomía laparoscópica: Experiencia en 30 casos [Laparoscopic appendectomy: Experience in 30 cases]. *J Gastroenterol Peru.* 1997;17(3):242-8.
19. Galvez CLG. Apendicectomía laparoscópica vs. abierta en apendicitis aguda perforada en niños: Revisión sistemática y metaanálisis [Laparoscopic appendectomy vs. open in acute perforated appendicitis in children: Systematic review and meta-analysis] [Thesis]. Trujillo: Universidad Privada Antenor Orrego; 2023.
20. Botchway E, Marcisz L, Schoeman H, Kofi Botchway PP, Mabitsela EM, Tshifularo N. Laparoscopic versus open appendectomy: A retrospective cohort study on the management of acute appendicitis (simple and complicated) in children under 13 years of age. *Afr J Paediatr Surg.* 2021;18(4):182-6.
21. Cervera-Ocaña RI, Burgos-Chávez OA. Factores asociados a la duración de la estancia hospitalaria posterior a la apendicectomía laparoscópica [Factors associated with the length of hospital stay after laparoscopic appendectomy]. *Rev Colomb Cir.* 2023;38:121-7. <https://doi.org/10.30944/20117582.2211>
22. Quintanilla ARG. Efectividad de la apendicectomía laparoscópica versus abierta en el tratamiento de la apendicitis complicada en niños [Effectiveness of laparoscopic versus open appendectomy in the treatment of complicated appendicitis in children] [Thesis]. Lima: Universidad Nacional Mayor de San Marcos; 2013.
23. Buchanan FF, Myles PS, Cicuttini F. Effect of patient sex on general anaesthesia and recovery. *Br J Anaesth.* 2011;106(6):832-9. <https://doi.org/10.1093/bja/aer094> PMID:21558068
24. Jaschinski T, Mosch CG, Eikermann M, Neugebauer EAM, Sauerland S. Laparoscopic versus open surgery for suspected appendicitis. *Cochrane Database Syst Rev.* 2018;11(11):CD001546. <https://doi.org/10.1002/14651858.CD001546.pub4> PMID:30484855 PMCid:PMC6517145
25. Cruz OMC, Aragón APM. Ansiedad ante los exámenes en alumnos del octavo ciclo de las carreras profesionales de derecho y medicina humana de una universidad de Chiclayo [Anxiety before exams in students of the eighth cycle of professional careers in law and human medicine at a university in Chiclayo]. *Rev PAIAN.* 2020;11(1):79-91. <https://doi.org/10.26495/rcp.v11i1.1339>
26. Orthopoulos G, Santone E, Izzo F, et al. Increasing incidence of complicated appendicitis during COVID-19 pandemic. *Am J Surg.* 2021; 221(5):1056-60. <https://doi.org/10.1016/j.amjsurg.2020.09.026> PMID:33012500 PMCid:PMC7521886
27. Balanzá-Martínez V, Kapczinski F, de Azevedo Cardoso T, et al. The assessment of lifestyle changes during the COVID-19 pandemic using a multidimensional scale. *Rev Psi Salud Mental.* 2021;14(1):16-26. <https://doi.org/10.1016/j.rpsm.2020.07.003> PMCid:PMC7456305
28. Peeters T, Houben B, Cools P, et al. An observational study on lifestyle and environmental risk factors in patients with acute appendicitis. *Heliyon.* 2023;9(4):e15131. <https://doi.org/10.1016/j.heliyon.2023.e15131> PMID:37128345 PMCid:PMC10147974
29. Brandão M, Pimentel F, Cardoso M. Impact of academic exposure on health status of university students. *Rev Saude publica.* 2011;45(1):49-58. <https://doi.org/10.1590/S0034-89102011000100006> PMID:21203695
30. Bernert B. Assessing the impact of undergraduate college student health on academic performance across academic year. *J Psychol Res.* 2017;7. <https://doi.org/10.17265/2159-5542/2017.07.005>
31. Moya-Salazar J, Salazar CR, Delzo SS, Goicochea-Palomino EA, Rojas-Zumaran V. After a few months, what are the uses of OpenAI's ChatGPT in medicine? A Scopus-based systematic review. *Electron J Gen Med.* 2024;21(2):em577. <https://doi.org/10.29333/ejgm/14354>
32. Wong RS, Ming LC, Raja Ali RA. The intersection of ChatGPT, clinical medicine, and medical education. *JMIR Med Educ.* 2023;9:e47274. <https://doi.org/10.2196/47274> PMID:37988149 PMCid:PMC10698645