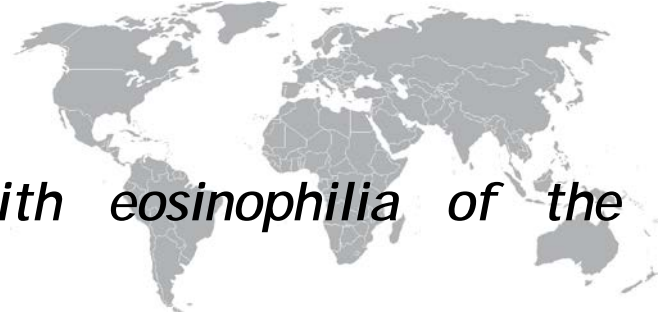



Angiolymphoid hyperplasia with eosinophilia of the maxillary sinus and orbit

Ismet Emrah Emre¹, Elif Aksoy¹, Ömer Faruk Ünal²

ABSTRACT

Angiolymphoid hyperplasia with eosinophilia (ALHE) is an inflammatory disorder characterized by benign vasoproliferative lesions. Although these lesions are typically found around the ear and external auditory canal, there are several studies that present cases with ocular involvement. In this report we present the first case of ALHE with ocular and sinus involvement in Turkish literature.

Keywords: angiolymphoid hyperplasia with eosinophilia (ALHE), kimura disease, epithelioid hemangioma, orbita, maxillary sinus

INTRODUCTION

Angiolymphoid hyperplasia with eosinophilia (ALHE) is a benign disorder that presents with subdermal nodules that show an affinity for the head and neck region with the typical lesion involving the external auditory canal. Although previously frequently used as a synonym with Kimura's disease, today the two are generally accepted to be two different diseases. ALHE shows a definite predilection for the external auditory canal, it may present in the maxillary sinus, ethmoid sinus and orbita. Removal of these lesions often results in recurrence and the need for secondary surgery. In this report we present an unusual case of both maxillary and orbital involvement in a male patient with ALHE.

CASE REPORT

A 31-year old Caucasian male presented with right-sided eye swelling, diplopia, limitation of eye movements and a feeling of fullness in his right cheek area. His physical examination revealed restricted right globe movements and proptosis. Optical evaluation showed diminished sight.

MRI showed a lobulated, well circumscribed lesion, measuring 25 x 38 x 39 mm in the right inferior orbita, displacing the globe and other orbital structures anteromedially and superiorly. Invasion findings were present in the neighboring inferior, medial and lateral walls of the orbita, inferior rectus muscle, roof of the maxillary sinus and the lesion seemed to extend into the right middle ethmoid cells and superior part of the right maxillary sinus (Figure 1). A CT scan was obtained and showed a lesion arising from the right maxillary bone with extension into the right orbital cavity. The floor, medial and posterior walls of the orbital bone were eroded but there was no evidence of globe involvement. The lesion also had extension into the nasal cavity (Figure 2). A CBC showed minimally elevated leukocyte levels yet the eosinophil count was normal. A biopsy from the maxillary extension of the lesion was performed; the histological evaluation showed a spindle cell tumor with epithelioid cells later designated as an epithelioid hemangioendothelioma. A second operation for total excision was performed however, due to the lesions

localization, a small residual tumor was left to preserve eyesight. The microscopic assessment was reported as angiolymphoid hyperplasia with eosinophilia.

DISCUSSION

Although Angiolymphoid hyperplasia with eosinophilia (ALHE) and Kimura disease have very similar clinical and histopathological properties they represent two different disease processes. The two terms have been used interchangeably for the similar clinical spectrum in the previous literature (1) the two entities both show a predilection for the head and neck, frequently recur after treatment, and most often present as subcutaneous masses with vascular proliferation and eosinophilia. However after a study by Rosai et al. (2), the two processes were divided into two distinct diseases.

Angiolymphoid hyperplasia with eosinophilia (ALHE) also termed epithelioid hemangioma is a benign, rare disorder which presents with pink to red-brown, dome shaped, dermal or subdermal papules or nodules of the head and neck with a predilection for the ear, especially the external auditory canal (3). ALHE is accepted to be a benign vasoproliferative formation with inflammation, however there is no consensus regarding the causative predisposer for the development of this disease although trauma, low grade infections, allergy and pregnancy have all been implicated (4). The pathogenesis is believed to begin with the formation of an arteriovenous malformation (5). Microscopic evaluation of these nodules shows a proliferation of vessels surrounded by a lympho-eosinophilic predominant infiltrate. The vessels have an endothelial covering which appears to be like an epithelioid and some may produce epithelioid endothelium, causing obstruction of these vessels. The treatment for epithelioid hemangiomas is surgical. Spontaneous regression is still a matter of debate although a consensus has been reached stating that recurrence is common.

The typical presentation of ALHE is a middle-aged Caucasian woman with multiple subdermal or dermal, matted red lesions, predominantly located in the head and neck region. The behavior of lesions differ and show a range; from asymptomatic bumps to pruritic and painful swellings (6). Lesions are

¹ Acibadem University, Department of Otorhinolaryngology, Istanbul, Turkey
² Koç University, Department of Otorhinolaryngology, Istanbul, Turkey

Correspondence: Ismet Emrah Emre
Halkalı merkez mahallesi, Turgut Özal Bulvarı, No: 16 Küçükçekmece, Istanbul, Turkey
Phone: +905325402662

E-mail: emrah.emre@acibadem.com.tr

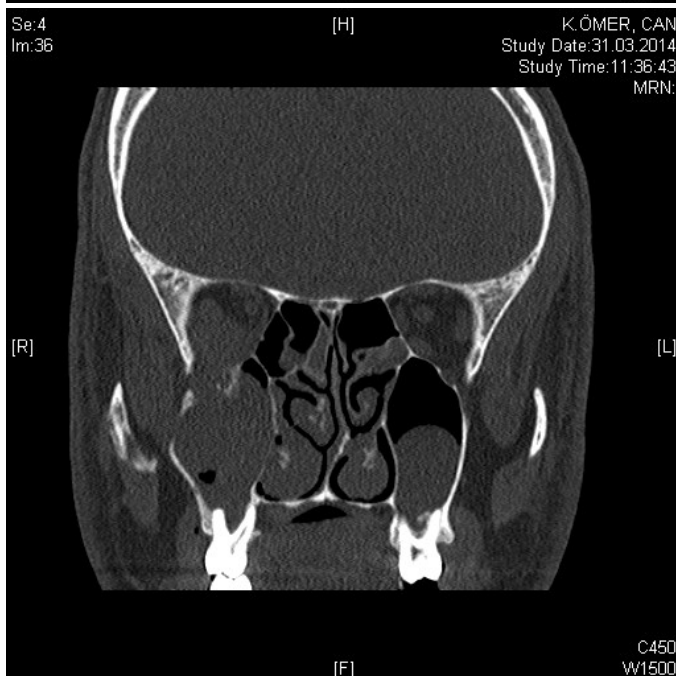
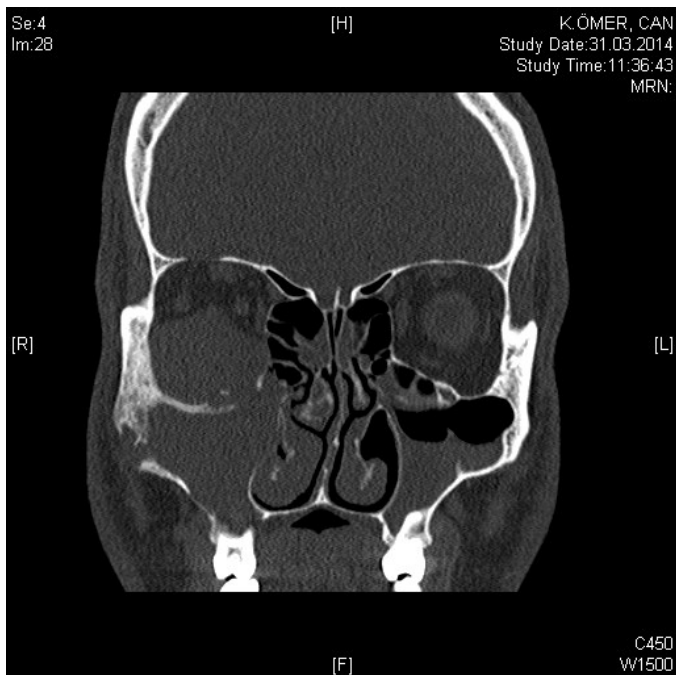


Figure 1: a: Precontrast T1 weighted axial plane MR image depicts a well circumscribed lesion in the right orbita displacing the globe anteromedially. b: Postcontrast T1 weighted coronal plane MR image shows that the lesion enhances homogeneously. Globe is displaced superomedially and the lesion extends into the neighboring maxillary and middle ethmoid sinuses

occasionally reported in different parts with the orbital tissues, parotid, chest and lingual mucosa being some of the areas presented (4, 7, 8, 9). Orbital involvement of ALHE is very rarely bilateral and is generally treated with surgery. Be it de-bulking or complete removal, several studies have shown that the lesions involute more rapidly when the lesion is excised (8, 10, 11). Other treatment modalities initiated in the treatment of ALHE are intralesional steroids, cryotherapy, cytotoxic drug injections, phototherapy, radiation therapy and alpha-2a interferon therapy (12).

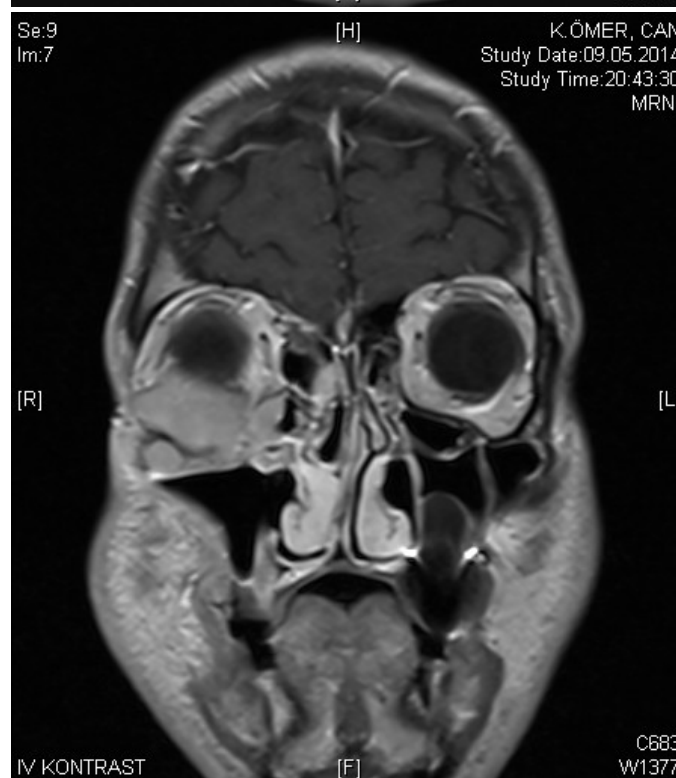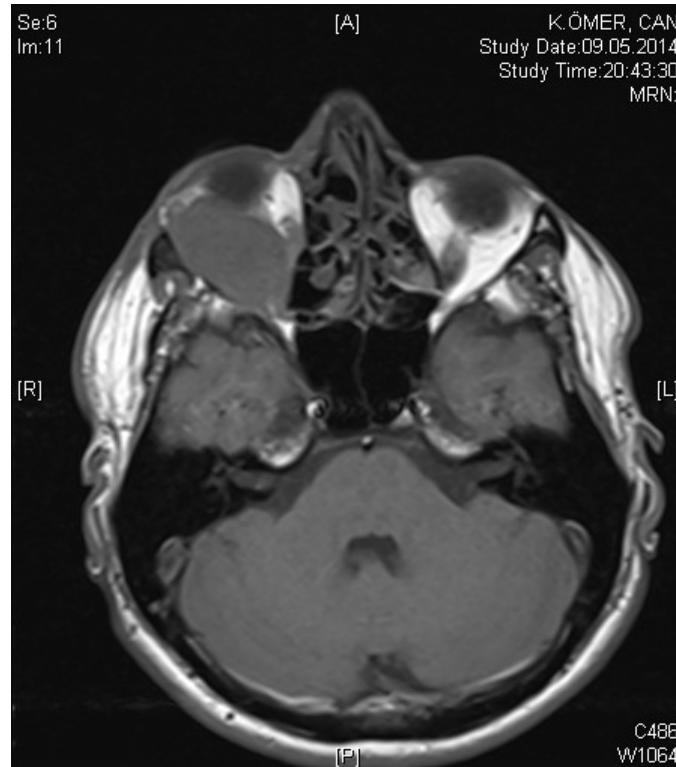


Figure 2: a: The lesion with erosion of the inferior orbital wall and extension into the nasal cavity. Note the displacement of the inferior and lateral rectus muscles. b: The lesion extending posteriorly and eroding the posterior maxillary wall together with the posterolateral orbital floor

Kimura's disease is described as a chronic inflammatory disease that presents as deep, subcutaneous masses in the head and neck, especially around the ear and on the scalp. Involvement of salivary glands and lymph nodes is frequently seen and blood analysis shows increased levels of both immunoglobulin E (IgE) and peripheral blood eosinophilia (13). Microscopy shows lymphoid tissue with reactive follicular hyperplasia with deposits of eosinophilic proteinaceous

material in the germinal center, hence the appearance of a granuloma. Eosinophilia and elevated IgE levels are characteristic of KD and it has been postulated that the level of eosinophilia may be correlated with the size of the lesion (14). KD has also been linked with allergic diseases such as asthma, eczema and rhinitis.

The stereotypic KD patient is an Asian, young male with a single subdermal lesion, accompanying lymphadenopathy with elevated levels of blood eosinophils and IgE (15). Although there is a small chance of spontaneous involution making it a viable option to observe asymptomatic cases, the treatment of choice is surgery in symptomatic cases (16). KD has a higher recurrence rate than ALHE and for this reason; incomplete removal of the lesion is generally not an accepted method of treatment.

REFERENCES

1. Weiss SW, Goldblum JR. Benign tumors and tumor-like lesions of blood vessels. *Enzinger and Weiss's Soft Tissue Tumors*, 5th Edition. Philadelphia, PA: Mosby Elsevier. 2008;633-679.
2. Rosai J, Gold J, Landy R. The histiocytoid hemangiomas. A unifying concept embracing several previously described entities of skin, soft tissue, large vessels, bone and heart. *Hum Pathol*. 1979;10:707-30.
3. James WD, Berger TG, Elston DM. *Andrews' diseases of the skin*. Clinical Dermatology. 10th edition. Philadelphia, PA: Saunders Elsevier. 2006;591-2,601.
4. Nangia R, Puri A, Gupta R, Bansal S, Negi A, Chauhan I. Epithelioid hemangioma of lingual alveolar mucosa: an immunohistochemical case report. *Case Rep Med*. 2014;2014:436240.
5. Stewart N, Zagarella S, Mann S. Angiolymphoid hyperplasia with eosinophilia occurring after venipuncture trauma. *J dermatol* 2013 May;40(5):393-5
6. Olsen TG, Helwig EB. Angiolymphoid hyperplasia with eosinophilia: a clinicopathologic study of 116 patients. *J Am Acad Dermatol*. 1985;12(5 pt. 1):781-796.
7. Sanchez-Orgaz M, Insausti-Garcia A, Gregorio LY, Duralde AA, Romero-Martin R. Epithelioid hemangioma of the orbit or angiolymphoid hyperplasia with eosinophilia. *Ophthal Plast Reconstr Surg*. 2014 May-June;30(3):e70-2.
8. Azari AA, Kanavi MR, Lucarelli M et al. Angiolymphoid hyperplasia with eosinophilia of the orbit and ocular adnexa: report of 5 cases. *JAMA Ophthalmol*. 2014 May;132(5):633-6.
9. Trindade F, Haro R, Requena L. Giant angiolymphoid hyperplasia with eosinophilia on the chest. *J cutan Pathol*. 2009 Apr;36(4):493-6.
10. Kahana A, Lee BJ, Flint A, Elnor VM. Periocular epithelioid hemangioma: Response to bevacizumab and vascular pathogenesis. *Arch Ophthalmol*. 2012 Sep;130(9):1209-12.
11. Alder B, Proia A, Liss J. Distinct, bilateral epithelioid hemangioma of the orbit. *Orbit*. 2013 Feb;32(1):51-3.
12. Panduranga Kamath M, Bhojwani KM, Bhandarkar AM, Pai RR, Rent NH. Angiolymphoid hyperplasia with eosinophilia of root of nose: a rare Phenomenon. *J Clin Diagn Res*. 2014 Mar;8(3):144-5.
13. Sah P, Kamath A, Aramanadka C, Radhakrishnan. Kimura's disease - An unusual presentation involving subcutaneous tissues, parotid gland and lymph node. *J Oral Maxillofac Pathol*. 2013;17:455-9
14. Dik VK, Van der Wiel BA, Vasmel WL. Kimura's disease of the parotid glands and multiple cervical lymph nodes. *Neth J Med*. 2010;68:175-7.
15. Jani A, Coulson M. Kimura's disease: A typical case of a rare disorder. *West J Med*. 1997;166:142-4.
16. Meningaud JP, Pitak-Arnop P, Fouret P, Bertrand JC. Kimura's disease of the parotid region: Report of 2 cases and review of the literature. *J Oral Maxillofac Surg*. 2007;65:134-40.



<http://www.ejgm.org>

CONCLUSION

Kimura's disease and ALHE are two different pathologies with very similar appearances. Where ALHE is considered a benign proliferative disorder, KD is accepted as a chronic allergic process. The differences in age, race and sex may give clues as to which disease is being dealt with but definitive categorization is done histochemically. Orbital involvement may be seen in both diseases and should be treated similarly to dermal lesions. Total excision is the preferred method but if not possible, to speed along the process of spontaneous regression, especially in the case of epithelioid hemangioma, de-bulking is the next best option.