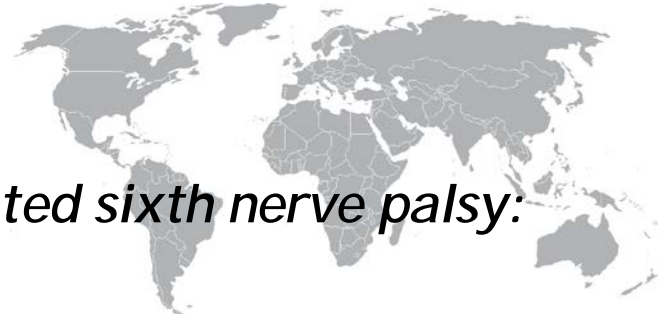

# Tuberculoma presenting as isolated sixth nerve palsy: A rare case report

Deepak Jain<sup>1</sup>, H.K. Aggarwal<sup>2</sup>, Avinash Rao<sup>3</sup>, Shaveta Dahiya<sup>4</sup>

## ABSTRACT

Tuberculomas constitute 5-30% of the space occupying lesions of central nervous system in developing countries. Children and young adults constitute the most affected population. Most common presentations of tuberculomas are cranial nerve palsies or focal neurological signs but presentation as isolated sixth nerve palsy is very rare. We report a case of an elderly female who presented with history of double vision for 2 months and was found to have isolated abducens nerve palsy of left eye due to tuberculoma in the ponto-medullary junction. Patient improved symptomatically within antitubercular treatment with complete recovery of eye movements.

**Keywords:** Tuberculoma, isolated abducent nerve palsy, space occupying lesions

## INTRODUCTION

Brain stem tuberculoma is an infrequent entity. It usually presents with multiple cranial nerve palsies and long tract signs. It should be suspected in patients with space-occupying lesions of the brain stem who live in geographic areas where tuberculosis is endemic. There are case reports of tuberculomas presenting with isolated cranial nerve involvement with presentations including eye movement disorders, nystagmus, decreased vision, gaze abnormalities, one and half syndrome secondary to involvement of medial longitudinal fasciculus, isolated facial palsies (1, 2).

In the absence of evidence of pulmonary or other extra-pulmonary tuberculosis, the diagnosis of tuberculoma remains a diagnostic confusion. We report a case of an elderly female patient who presented to the outpatient department with history of diplopia. After thorough clinical, laboratory and radiological investigations, she was found to have tuberculoma in the ponto-medullary junction. We describe the methodology of investigations carried out with a brief insight to pathogenesis and treatment of the disease.

## CASE REPORT

A 66 year female presented to out patient department with the history of double vision since 2 months. It was insidious in onset, progressive in nature and associated with light headedness along with medial deviation of left eye which disappeared on occlusion of either eye. Double vision was present more on the left gaze horizontally. There was no drooping of eye lids, diurnal variation of the symptom, no associated pain or numbness in the orbital region. There was no history of ear ache, ear discharge, abnormal facial sensations/movements, and trauma to the eye. There was no history suggestive of drug intake, diabetes, hypertension, tuberculosis, seizure disorder or dental procedures.

On general physical examination, patient was conscious, oriented. Vitals were stable. On eye examination, anatomical components including pupil size, reaction, eye lids and fundus

were normal. In the functional examination of the eyes, direct and consensual reflexes were normal. Visual acuity was 6/6 in the bilateral eyes. On finger confrontation test and perimetric examination, there was constriction in the left temporal eye field. Patient was unable to abduct the left eye (Figure 1). Systemic examination including cardiovascular, respiratory and nervous systems was normal.

On the day of hospitalization, laboratory examination showed normal hematological profile with increased erythrocyte sedimentation rate of 45 mm/1<sup>st</sup> hour. Renal function tests and liver function tests were within normal limits. Viral markers for HIV were negative. Thyroid profile was normal. Serum ACE level was normal. ELISA for cysticercosis in the serum was negative. Mantoux test was positive with induration of 12 mm.

Chest X-ray of the patient was normal (Figure 2). CECT thorax was also normal. MRI brain of the patient revealed an approximately 5mm enhancing nodular lesion on the left side of pons near ponto-medullary junction with perilesional edema extending into pons and medulla which suggested an active inflammatory granuloma with possibility of tuberculoma (Figure 3).

With the evidence of tuberculoma, patient was started on antitubercular therapy with HRZE along with dexamethasone 8 mg thrice daily. Patient was followed up in the out patient clinic with monitoring of the liver enzymes. She improved symptomatically within a span of 6 weeks with complete recovery of eye movements.

<sup>1</sup> Assistant Professor, Department of Medicine, Sharma University of Health Science, India

<sup>2</sup> Senior Professor & Head Department of Medicine IV, Sharma University of Health Science, India

<sup>3</sup> Resident, Department of Medicine, Sharma University of Health Science, India

<sup>4</sup> Senior Resident, Department of Medicine, Sharma University of Health Science, India

Correspondence: Dr. Deepak Jain

Department of Medicine, Pt. B.D. Sharma University of Health Sciences, ROHTAK-124001 (Haryana), India

E-mail: [jaindeepakdr@gmail.com](mailto:jaindeepakdr@gmail.com)



Figure 1: Photographs of the patient at presentation. Finger confrontation test revealed the inability to abduct the left eye

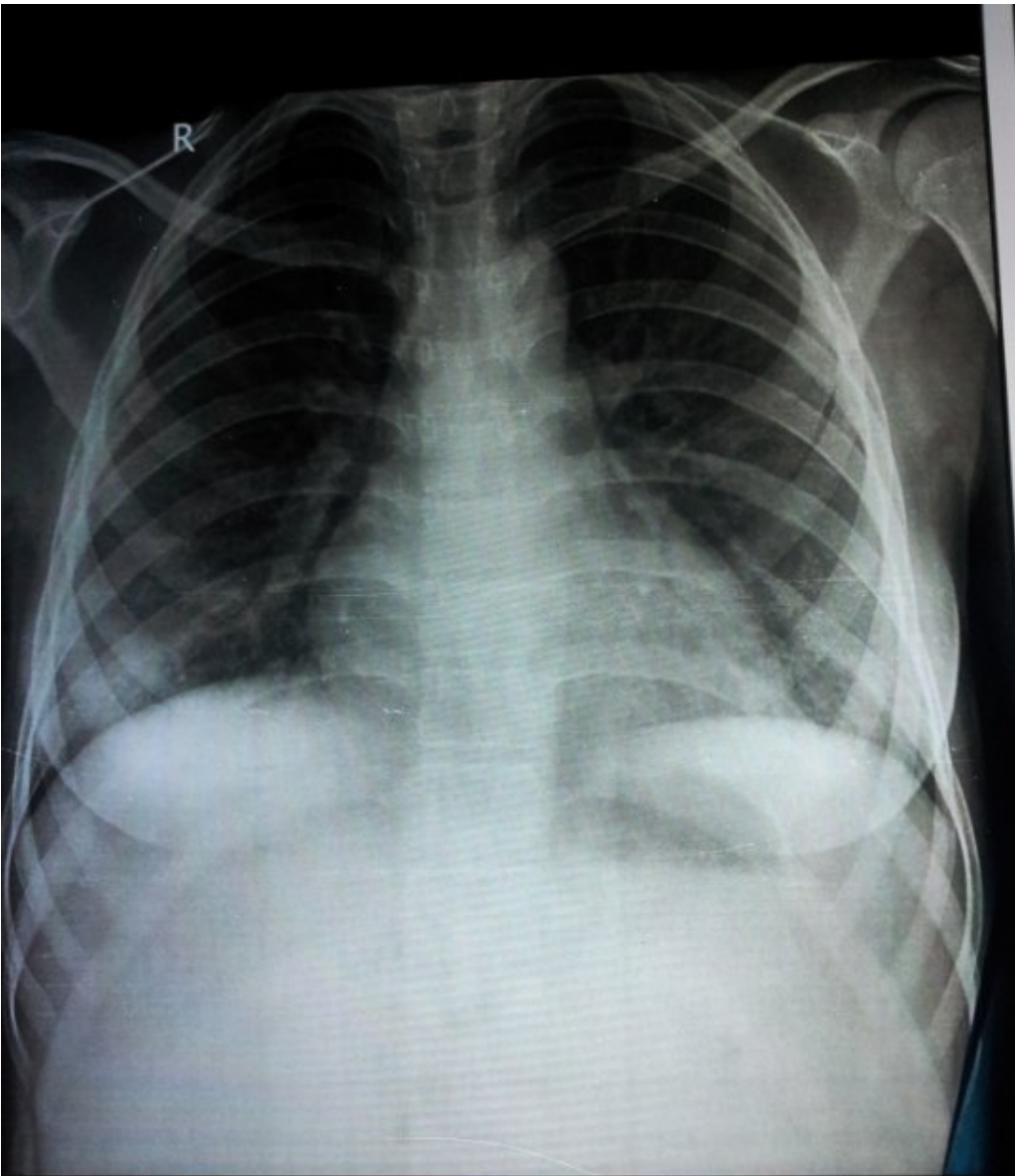


Figure 2: Normal Chest X Ray of the patient

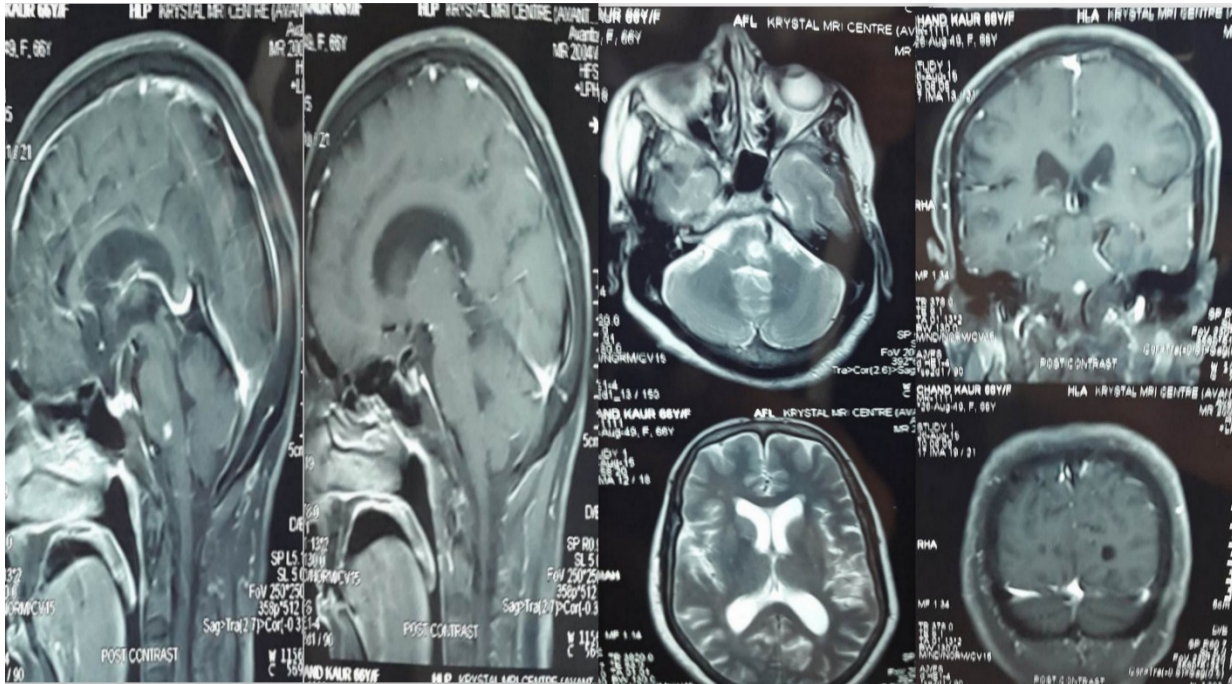


Figure 3: MRI brain of the patient revealing an approximately 5mm enhancing nodular lesion on the left side of pons near ponto-medullary junction with perilesional edema extending into pons and medulla

## DISCUSSION

Abducens nerve palsy is the most common isolated palsy as the nerve has a long peripheral course. The abducens nucleus is situated in the caudal pons, at the level of the facial colliculus. Isolated nuclear lesion of the abducens nerve is extremely rare as facial nerve loop and pontine gaze center are located in the vicinity of the abducens nerve nucleus. Abducens nerve exits the brainstem at the margin of the pons and medullary pyramids. As it can be affected anywhere along its long intracranial course, differential diagnosis of abducens nerve palsy demands extensive investigation to find the proper cause (3).

The isolated abducent nerve injury could be due to vascular, neoplastic, degenerative, infectious, inflammatory or traumatic etiology. The diagnosis of intracranial tuberculoma should be considered in any patient from a developing country, or with past history suggestive of exposure to tuberculosis. Usually brainstem tuberculoma presents with low grade fever,

weight loss, vomiting along with sixth and seventh cranial nerve affections along with motor and sensory symptoms, which are usually unilateral. Isolated abducens nerve palsy could be attributed to lesions of the nerve along their extra axial course (4).

Brain stem tuberculoma presenting as isolated abducent nerve involvement in elderly patient has not been reported yet to best of our knowledge. The clinical presentation, laboratory reports showing raised erythrocyte sedimentation rate and positive mantoux test with radiological demonstration of enhancing nodular lesion suggestive of active inflammatory granuloma pointed clearly towards tuberculoma. In the light of tubercular etiology, the biopsy of the lesion was not done in the patient. Patient gradually improved with anti-tubercular therapy in the course of the follow up. The rarity in this case is the isolated involvement of the abducens nerve by the tuberculoma in an elderly female patient which resolved with treatment.

## REFERENCES

1. Shamim MS, Enam SA, Ali RP, Wasay W. Overview of surgical management of infectious non-suppurative brain lesions. *Pak J Neural Sci.* 2009;4(2):77-82.
2. De Angelis LM. Intracranial tuberculoma: Case report and review of the literature. *Neurology.* 1981;31:1133.
3. Brinar VV, Habek M, Ozretic D, Djakovic V, Matijevic V. Isolated nontraumatic abducens nerve palsy. *Acta neurol Belg.* 2007;107:126-30.
4. Sharma C, Kumawat B, Tripathi G, Dixit S. Isolated Sensory Trigeminal Neuropathy- A Rare Clinical Presentation of Brain Stem Tuberculoma. *The Internet Journal of Neurology.* 2008;11:1-3.



<http://www.ejgm.org>