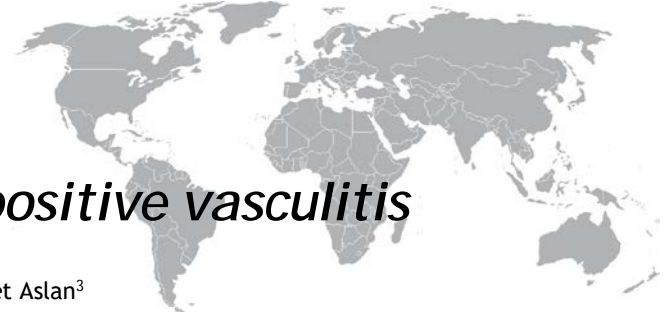

# A case with drug-related ANCA-positive vasculitis

Raziye Yazıcı<sup>1</sup>, İbrahim Güney<sup>1</sup>, Lütfullah Altıntepe<sup>1</sup>, Ali Karagöz<sup>2</sup>, Şevket Aslan<sup>3</sup>

## ABSTRACT

Main causes of drug-related antineutrophil cytoplasmic antibody (ANCA)-positive vasculitis are antithyroid drugs. It is known that ANCA-positive vasculitis occurs after long term use of the drugs and develops in 4-6.5 percent of the patients. Herein, we present a female patient with propylthiouracil (PTU)-related ANCA-positive vasculitis, mimicking appendicitis and familial mediterranean fever (FMF), which developed after long-term drug usage.

**Keywords:** vasculitis, ANCA, propylthiouracil

## INTRODUCTION

The main causes of drug-related antineutrophil cytoplasmic antibody (ANCA)-positive vasculitis are the drugs used for the treatment of hyperthyroidism. ANCA-positive vasculitis develops approximately in 4-6.5% of patients using antithyroid drugs (1,2). It is known that ANCA-positive vasculitis occurs after long term use of antithyroid drugs. Most of the patients have high levels of myeloperoxidase (MPO)-ANCA. The symptoms disappear with decreasing levels of MPO-ANCA (3). The patients with propylthiouracil (PTU)-related ANCA-positive vasculitis have higher frequency and higher levels of antinuclear antigen (ANA) than that of the patients with untreated Graves disease. The most frequent symptoms and signs seen in antithyroid drug-related ANCA-positive vasculitis are arthralgia, fever and cutaneous vasculitis. In addition, other findings of ANCA-associated vasculitis, crescentic glomerulonephritis and alveolar hemorrhage, may develop. Although prognosis of drug-related ANCA-positive vasculitis is better than that of idiopathic ANCA-associated vasculitis, in some patients renal and/or pulmonary symptoms may develop and steroids and/or immunosuppressive drugs may be required. Herein, we present a female patient with PTU-related ANCA-positive vasculitis, mimicking appendicitis and familial Mediterranean fever (FMF), which developed after long-term drug usage. So, we would like to draw attention to the importance of the history of drug use.

## CASE

A 23-year-old female patient admitted to hospital in May 2002 with joints pain, feeling of fever, eritematous lesions on whole body, itching, shortness of breath, palpitation, sweating. She was diagnosed as Graves' disease, and PTU 300mg/day was started. Methylprednisolone treatment was given for urticarial lesions. She discontinued methylprednisolone after 1 year and received PTU in changing doses until 2011. In April 2010, she underwent appendectomy operation with the prediagnosis of appendicitis due to severe-sudden onset abdominal pain and fever. During operation there was no finding of appendicitis. After that, asymmetric migratory pains on joints were started. Pain is more severe on hands and wrist joints and also on ankle

joints, knee and elbow. In June 2010, colchicine 1.5 mg/day and hydroxychloroquine 400 mg/day was started with the diagnosis of familial mediterranean fever (FMF) by Rheumatology Department, methylprednisolone (48 mg/day) was added to this treatment because of continuing symptoms.

In July 2010, she admitted to our department because of proteinuria. Physical examination, complete blood count, sedimentation and C-reactive protein level was normal. Serum albumin and total protein level was 3.5 g/dl and 6.4 g/dl respectively, other biochemical parameters were normal. Level of thyroid stimulating hormone, free T3 and free T4 was 1.21 µIU/ml, 3.21 pg/ml and 1.41ng/ml respectively. She had 1353 mg/day proteinuria. C3 and C4 level was 0.84 g/l and 0.07 g/l respectively. ANA was homogen 1/1000 positive, p-ANCA was 1/1000 positive. Extractable Nuclear Antigen (ENA) profile and cryoglobulin was negative. Urinary ultrasonography showed that localization, size, parenchymal thickness of the kidneys were normal and there was grade 1 ectasia on pelvicalyxial structure of right kidney and parenchymal echo of right kidney was grade 1.

She underwent renal biopsy. On light microscopic examination, there were segmental necrotizing lesions in some of the 19 glomeruli and there was proliferation and cohesiveness on epithel of neighbour Bowman capsule. There was a bit fibrosis and lymphocytic infiltration on periglomerular region and fibrous crescent in one glomeruli. On immune fluorescent examination, there were 5 glomerulus and nonspecific infiltration with IgM and C3 on necrotizing segments. IgG, IgA, C1q, fibrinogen and amyloid was negative. Pathological diagnosis was pauci-immune segmental necrotizing glomerulonephritis with focal crescent formation. Methylprednisolone 48mg/day and azathioprine 100mg/day was started with the diagnosis of PTU-related ANCA-positive vasculitis (renal involvement). PTU, colchicine and klorokin was discontinued and the patient underwent thyroidectomy operation. On follow-up, symptoms of the patient were regressed and proteinuria disappeared.

## DISCUSSION

Antithyroid drugs may lead to some adverse events such as agranulocytosis, pancytopenia, hepatic failure and drug

<sup>1</sup> Türkiye Sağlık Bilimleri Üniversitesi Konya Eğitim ve Araştırma Hastanesi Nefroloji Kliniği, Konya, Turkey  
<sup>2</sup> Sağlık Bakanlığı, Cihanbeyli Devlet Hastanesi, Konya, Turkey  
<sup>3</sup> Türkiye Sağlık Bilimleri Üniversitesi Konya Eğitim ve Araştırma Hastanesi Allerji Kliniği, Konya, Turkey

Correspondence: Raziye Yazıcı  
Konya Eğitim ve Araştırma Hastanesi Nefroloji Kliniği, Meram, Konya, Turkey  
Phone: +90 5053179564.

E-mail: drraziye42@hotmail.com

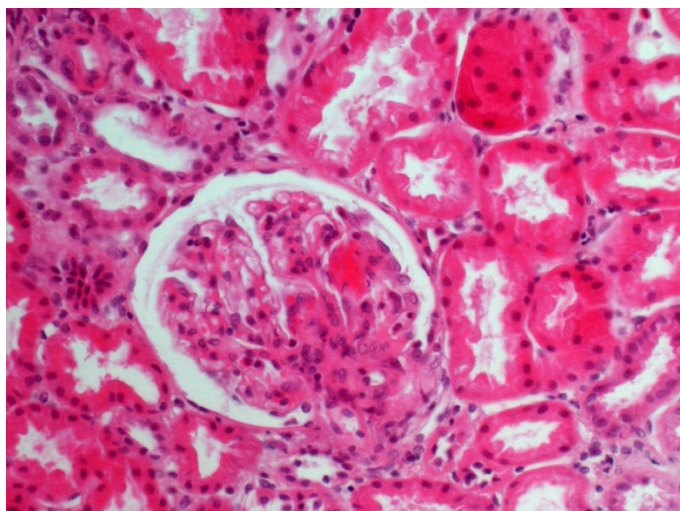


Figure 1. Segmental fibrinoid necrosis on HE staining (x20)

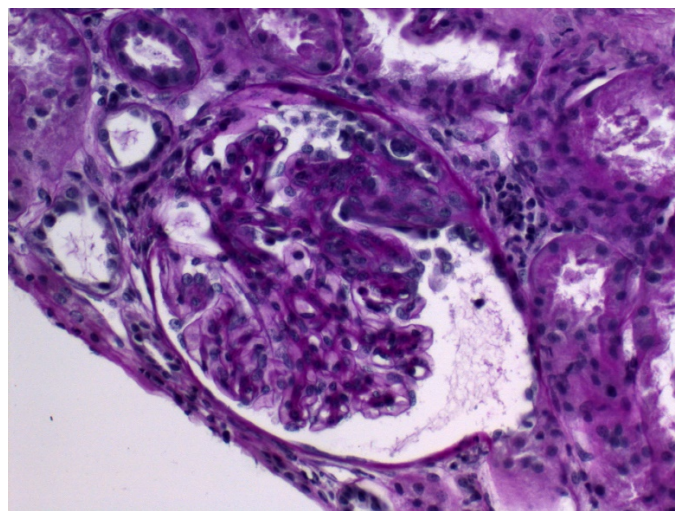


Figure 2: Crescent formation on PAS staining

eruptions. These adverse events usually develop in a few months after beginning of treatment and may be decreased by reducing dosage of the drugs (5). However duration until development of drug-related MPO-ANCA vasculitis is variable. Its frequency increases with the longer duration of antithyroid drug treatment, but it may also occur in a few months (5). In the study of Yazisiz et al., no relation was detected between ANCA positivity and duration and dosage of PTU treatment (6). Glomerulonephritis may develop in approximately 2 years or later. It may develop without using high dose drug (7). It may be seen more frequently among young women (8,10). Our patient used PTU in changing doses for 9 years. She was presented with the symptoms mimicking appendicitis and underwent an unnecessary surgery. Then she treated with the misdiagnosis of FMF and diagnosis of PTU-related ANCA- positive vasculitis was delayed.

The frequency of PTU-related ANCA is 20%-64% (2). In a study, the frequency of PTU-related ANCA and ANCA-associated vasculitis was reported as 11% and 4% respectively (1). In the study of Yazisiz et al., ANCA positivity among patients receiving PTU was reported as 41.3% (6). All antithyroid drugs may lead to ANCA positivity, but PTU causes mostly MPO-ANCA formation (8). ANCA-positive vasculitis is reported most frequently in patients with Graves' disease. It may also develop in patients with toxic nodular goiter (9). The kidneys are most affected organs; some findings, such as hematuria, proteinuria, elevated serum creatine level may be seen (2). The rate of renal involvement is 58.0-66.7% (10). The signs of PTU-related ANCA-positive vasculitis are less severe compared with primary ANCA-associated vasculitis (8, 10), the less number of patients have

clinical findings of rapidly progressive glomerulonephritis. Rate of end stage renal failure and mortality is low (2).

In a review, 3 possible reasons of good prognosis in patients with PTU-related ANCA associated vasculitis were reported: firstly, at presentation, mild clinical manifestations and less crescents in renal biopsy examination, secondly; decrease in the drug-related immune response with discontinuing the causal drug, thirdly; in PTU-related ANCA associated vasculitis, ANCA, such as anti-MPO antibodies have lower avidity and absence of the IgG3 subclass (2). To determine the severity of disease and treatment plan, renal biopsy is recommended in patients with renal vasculitis. In PTU-related ANCA-positive vasculitis, typically pauci-immune necrotizing crescentic glomerulonephritis may be established, but this is not required for diagnosis (2).

## CONCLUSION

ANCA-associated vasculitis may develop in patients receiving antithyroid drugs. This risk increases with using the drugs (especially PTU) for long term (over 4 years) and higher doses (250 mg/day). In most patients, level of MPO-ANCA is high. Level of antithyroid peroxidase and antithyroglobulin antibody is similar to that of untreated Graves' disease. The most frequent symptoms are arthralgia and fever. It must be kept in mind that ANCA-positive vasculitis may develop in patients receiving antithyroid treatment for long time; for these patients periodic urine analysis might be useful.

## REFERENCES

1. Slot M, Links TP, Stegeman CA, et al. Occurrence of antineutrophil Cytoplasmic Antibodies and Associated Vasculitis in Patients With Hyperthyroidism Treated With Antithyroid Dugs: A Long-Term Followup Study. *Arthritis Rheum* 2005;53:108-13.
2. Gao Y, Zhao MH. Review article: Drug-induced antineutrophil cytoplasmic antibody-associated vasculitis. *Nephrology (Carlton)*. 2009 Feb;14(1):33-41.
3. Morita S, Ueda Y, Eguchi K. Anti-thyroid drug-induced ANCA-associated vasculitis: a case report and review of the literature. *Endocr J*. 2000 Aug;47(4):467-70.
4. Harper L, Cockwell P, Savage CO. Case of propylthiouracil-induced ANCA associated small vessel vasculitis. *Nephrol Dial Transplant*. 1998 Feb;13(2):455-8.
5. Noh JY, Yasuda S, Sato S, Matsumoto M, Kunii Y, Noguchi Y, et al. Clinical characteristics of myeloperoxidase antineutrophil cytoplasmic antibody-associated vasculitis caused by antithyroid drugs. *J Clin Endocrinol Metab*. 2009;94(8):2806-11.
6. Yazisiz V, Öngüt G, Terzioğlu E, Karayalçın U. Clinical importance of antineutrophil cytoplasmic antibody positivity during propylthiouracil treatment. *Int J Clin Pract* 2010;64(1):19-24.

7. Visavachaipan N, Ong-Ajyooth L, Chanchairujira T, Parichatikanond P, Choensuchon B. Clinical features and outcomes in patient with antineutrophil cytoplasmic autoantibody-positive glomerulonephritis associated with propylthiouracil treatment in Siriraj Hospital. *J Med Assoc Thai.* 2010;93 Suppl 1:139-46.
8. Bonaci-Nikolic B, Nikolic MM, Andrejevic S, Zoric S, Bukilica M. Antineutrophil cytoplasmic antibody (ANCA)-associated autoimmune diseases induced by antithyroid drugs: comparison with idiopathic ANCA vasculitis. *Arthritis Res Ther.* 2005;7:1072-81.
9. Bilge NS, Kaşifoğlu T, Korkmaz C. PTU-induced ANCA-positive vasculitis: an innocent or a life-threatening adverse effect? *Rheumatol Int.* 2012 Jan 8.
10. Yu F, Chen M, Gao Y, Wang SX, Zou WZ, Zhao MH, Wang HY. Clinical and pathological features of renal involvement in propylthiouracil-associated ANCA-positive vasculitis. *Am J Kidney Dis.* 2007 May;49(5):607-14.



<http://www.ejgm.org>