

# A case report of primary tuberculosis of the tongue

Celalettin Korkmaz<sup>1</sup>, Munise Daye<sup>2</sup>, Turgut Teke<sup>1</sup>, Hatice Toy<sup>3</sup>, Eda Hasal<sup>2</sup>, Durdu Mehmet Yavsan<sup>1</sup>

## ABSTRACT

At present, the rate of extrapulmonary tuberculosis is gradually increasing among all tuberculosis cases. The secondary tuberculosis of oral cavity represents 0.2-1.5% of all cases with extrapulmonary tuberculosis. Although incidence of oral lesions secondary to pulmonary tuberculosis ranges from 0.4% to 1.5%, primary tuberculosis of the tongue occurs very rare, and it is published only as isolated case reports. A male patient presented to our dermatology clinic with complaints of painful ulcerated white plaques on the tip of his tongue lasting for three months, and an excisional biopsy showed granulomatous inflammation with caseification necrosis. Pulmonary and systemic examination showed no evidence of pulmonary or other extra-pulmonary tuberculosis, and he was initiated therapy for diagnosis of primary tuberculosis of the tongue. We found that the lesion completely resolved during the follow up visit after 1 month. Primary tuberculosis of the tongue should be for differential diagnosis of resistant painful oral lesions.

**Keywords:** tuberculosis of the tongue, extrapulmonary tuberculosis, primary tuberculosis

## INTRODUCTION

Extrapulmonary tuberculosis (EPTB) associated with several reasons has become increasingly a significant part of tuberculosis morbidity during the 20th century. EPTB is evaluated in two specific conditions; during examination of fever of unknown origin and in case of biopsy showing granulomatous inflammation in a organ or infected site (1).

Involvement of the upper respiratory tract often appears as a complication of pulmonary tuberculosis. It occurs during first exposure of these structures to sputum with mycobacteria, which mostly results in involvement of the larynx (2). Other involved areas of the upper respiratory tract include middle ear, mastoid, nasopharynx, nasal concha, tonsils and tongue (3). Tuberculosis of the upper respiratory tract has been substantially reduced by the use of anti-tuberculosis drugs. Its incidence ranges from 0.4% to 1.5%. Like other EPTBs, tuberculosis of the upper respiratory tract still remains one of the major clinical problems due to its atypical symptoms and signs and challenges in diagnosis (4).

In patients with pulmonary tuberculosis, the reported incidence of secondary oral tuberculosis lesions varies between 0.4% and 1.5% (5). Primary tuberculosis is a very rare condition, which has been published as isolated case reports.

## CASE PRESENTATION

A 46 year-old male patient presented to our outpatient clinic with a complaint of inflammatory painful wound on the tip of his tongue for 3 months. He had previously received local treatment at the dermatology and ear nose and throat outpatient clinics of external centers, however due failure to respond, he was treated with cauterization and excision, but same complaints recurred.

The dermatological examination showed a 1x1.5 cm ulcerated white plaque in the mid part of the tongue, and he underwent excisional biopsy (Figure 1) for preliminary diagnosis of squamous cell carcinoma, leukokeratosis, leukoplakia, lichen

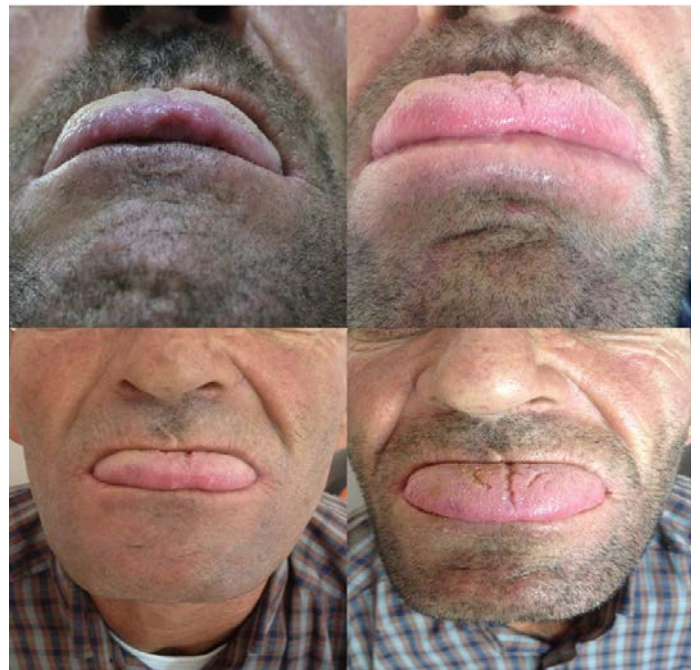

Figure 1: The appearance of the tongue, post-excisional biopsy and post-treatment

planus, traumatic ulcer, nicotine stomatitis, pemphigus vulgaris. Excisional biopsy of the tongue showed granuloma formations, langhans type giant cells including caseating necrosis under the epithelium in areas covered by multilayer squamous epithelium with an ulcerated center (Figure 2). The patient was referred to the chest diseases and tuberculosis outpatient clinic for suspected tuberculosis.

Medical history and physical examination of the patients at the department of chest diseases showed no respiratory symptoms or signs. Other system examinations were normal. There was no abnormality in his hemogram, sedimentation rate,

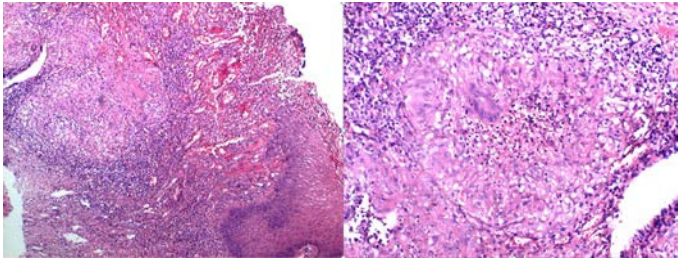
<sup>1</sup> Department of Chest Diseases, Meram Faculty of Medicine, Necmettin Erbakan University, Konya, Turkey.

<sup>2</sup> Department of Dermatology, Meram Faculty of Medicine, Necmettin Erbakan University, Konya, Turkey.

<sup>3</sup> Department of Pathology, Meram Faculty of Medicine, Necmettin Erbakan University, Konya, Turkey.

Correspondence: Celalettin Korkmaz  
Necmettin Erbakan Universitesi, Meram Tip Fakultesi Hastanesi Gogus Hastaliklari Anabilim Dalı, 42080 Meram, Konya, Turkey

E-mail: [celalettinkorkmaz@hotmail.com](mailto:celalettinkorkmaz@hotmail.com)



**Figure 2:** a) X40, H&E, ulceration of the squamous epithelium, with a dense lymphocytic infiltration around the granuloma structures under the epithelium. b) X100, H&E, including giant cell granulomatous structure.

urinalysis and routine biochemical tests. Serologically human immunodeficiency virus (HIV), and venereal disease research laboratory (VDRL) test result was negative.

PA chest radiography and thoracic tomography showed no pathological result. PPD test result was 24 mm.

The patient was initiated on a quadruple therapy for tuberculosis (isoniazid, rifampicin, ethambutol, pyrazinamide). The ulcerated white plaque was completely resolved during the follow up visit after 1 month (Figure 1).

## DISCUSSION

Primary tuberculosis of the tongue occurs very rare. Among all types of extrapulmonary tuberculosis, the incidence of secondary tuberculosis of the oral cavity ranges from 0.2 to 1.5% (6). Tuberculosis of the tongue is more common in women than in men, being usually observed at patients aged over 40 years of age (7). Our patient was a 46 year-old male.

Tuberculosis of the oral cavity usually develops secondary to active pulmonary tuberculosis. These patients develop disease as a result of direct implantation of tubercle bacilli from the sputum into the damaged mucosa with the help of predisposing factors (2). Although it is rare, cases with primary tuberculosis of the oral cavity have been reported (8). As it was the case in our patient, bacillemia which develops less frequently during the primary infection evoked on first exposure to tubercle bacilli and mycobacteria that can spread throughout the body can be controlled by host cellular immunity, however it rarely results in primary tuberculosis of the tongue with activation of bacilli since this response is usually inadequate for sterilization. Therefore, tuberculosis should be suspected in patients with resistant painful oral lesions, and it should be kept in mind despite presence of a normal chest radiogram.

## REFERENCES

1. Iseman MD. Extrapulmonary tuberculosis in adults. In: Iseman MD, editor. *A clinician's guide to tuberculosis*. Philadelphia: Lippincott Williams and Wilkins. 2000:145-97.
2. Kilgore TR, Jenkins DW. Laryngeal tuberculosis. *Chest*. 1983;83:139-41.
3. Prada JM, Kindelan JL, Jurado R, Sanchez Guijo P, Torre Cisneros J. Tuberculosis of tongue in two immunocompetent patients. *Clin Infect Dis*. 1994;19:200-02.
4. Kalac N, Gozu A, Ugurman F, et al. A Rare Entity: Nasopharyngeal Tuberculosis (Report of 5 Cases). *Respiratory Diseases*. 2009;20:121-125.
5. Woolfe M. Secondary tuberculous ulceration of the tongue. A case report. *Br Dent J*. 1968; 125:270-71.
6. Nemes RM, Lanosi ES, Pop CS et al. Tuberculosis of the oral cavity. *Rom J Morphol Embryol*. 2015;56(2):521-25.
7. Ucinska R, Sieminska A, Stominski JM. Tuberculosis of the tongue. *Case Rep Clin Pract Rev*. 2002;3:102-04.
8. Dimitropoulos I, Rouloumis L, Lazandis N, Karakosis D, Trigondis G, Sichelndis L. Primary tuberculosis of the oral cavity. *Oral Surg Oral Med Oral Pathol*. 1991; 72(6):712-15.
9. Arınç S, Arınç B, Bayal I, Uyanusta Kucuk C, Yaldız E, Bulum S, Karagoz T. Secondary lingual tuberculosis: a case report. *Turkish Respir J*. 2003;4:25-26.
10. Kornet H, Scnaefer RF, Mahoney PL. Bilateral tuberculous granulomas of the tongue. *Arc Otolaryngol*. 1965;82:649-51.

Predisposing factors of the disease include poor oral hygiene, trauma, irritation, tooth extraction, pyogenic focus and leukoplakia. Our patient had a poor oral hygiene and caries.

Tongue is the most commonly affected part of the oral cavity. The dorsal surface is more commonly involved than the ventral surface (9). The most common oral tuberculosis lesions are tip of the tongue, lateral tongue and floor of mouth, soft palate, anterior tonsillar pillar, uvula, superior and posterior parts of the tongue, respectively (10). Lesions are mainly in the form of ulcerations. Our patient had 1x1.5 cm ulcerated white plaque on the tip of his tongue. Oral ulcers are usually single

rather than multiple; they have an indurated, irregular and undermined margin with a necrotic base. Other manifestations of oral tuberculosis may include nodular lesion or cold abscess (11).

The symptoms present as pain and discomfort while eating. The main complaint of our patient was an ulcer and inflammatory pain on the tip of his tongue. Lesion was markedly resistant to the invasion by mycobacterium tuberculosis due to high concentration of therapeutic drugs, prominent vascularity of oral mucous membranes and reduced fibrinolytic activity (6).

The clinical course of oral tuberculosis is non-specific. It must be differentiated from epidermoid Ca, syphilis, fungal infections and other granulomatous conditions. VDRL was negative in our patient. Biopsy showed no evidence of malignancy. Early biopsy results are often not diagnostic. Repeated biopsies, radiographic examinations, serological tests, culture, gram and acid fast staining are required for the diagnosis (12). We made the diagnosis in our patient depending on the granulomatous inflammation with caseification necrosis during the first biopsy of the tongue.

Oral tuberculosis responds well to antituberculosis therapy. We found that the tongue completely resolved in our patient during the follow up after 1 month, and there was no recurrence.

## CONCLUSION

Although it is rare, primary tuberculosis of the tongue should be kept in mind for differential diagnosis of resistant painful oral lesions, and such patients mostly seen by dermatologists, ear nose throat specialists and dentists should be examined accordingly without any delay.

11. Dogra SS, Chander B, Krishna M. Tuberculosis of oral cavity: a series of one primary and three secondary cases. Indian J Otolaryngol Head Neck Surg. 2013; 65(3):275-79.

12. Held T, Kissler W, Reich let A, Mielke M, Alexander M. Tuberculosis of the larynx oral cavity and pharynx. Dithsch Med. Wocherscher. 1991;116(31-32):1186-90.



<http://www.ejgm.org>