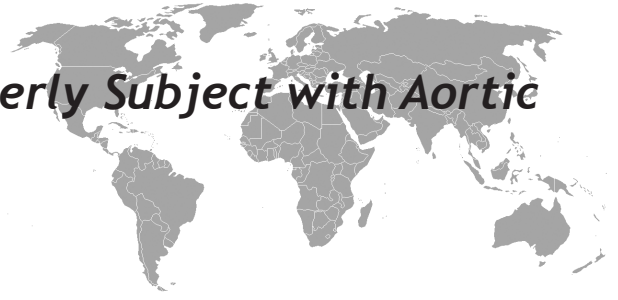

An Unclear Anemia in an Elderly Subject with Aortic Stenosis

Valerio Massimo Magro



ABSTRACT

We describe the case of a woman who showed an unclear anaemia. The patient suffered of aortic valve stenosis and we also found an intestinal bleeding from angiodysplasia. So we put the diagnosis of Heyde's syndrome and we treated with mesenteric angiography and embolization. The clinical case allows to assert that in presence of the anaemia its causes must always be carefully investigated even in elderly patients.

Key words: Aortic stenosis, gastrointestinal bleeding, elderly patient, Heyde's syndrome, angiodysplasia

Aort Darlığı olan Bir Yaşlı Hastada Belirsiz Bir Anemi

ÖZET

Biz belirsiz anemi gösteren bir kadın olgusunu tanımladık. Aort kapak darlığından şikayeti olan hastada anjiyodisplaziden dolayı bağırsak kanaması olduğunu tespit ettik. Bundan dolayı biz Heyde sendromu tanısı koyduk. Biz mezenterik anjiyografi ve embolizasyon ile tedavi ettik. Bu vaka yaşlı hastalarda anemi varlığında dikkatli bir araştırma yapılması gerektiğini gösterdi.

Anahtar kelimeler: Aort darlığı, gastrointestinal kanama, yaşlı hasta, Heyde sendromu, anjiyodisplazi

INTRODUCTION

Anemia is a frequently encountered problem in the older patient (1-3). The adopted criteria by the World Health Organization (WHO) for the diagnosis of anemia define the anemic state if hemoglobin levels are below 12 g/dl in a female subject. The causes of anemia in the elderly are also extremely heterogeneous and its difficult to distinguish between them (multifactorial anemia or mixed anemia): iron deficiency and/or folate and/or vitamin B12 deficiency, chronic disease and/or kidney failure. In the NHANES III study (it comprised a cohort of 2800000 anemic outpatients), up to 33.6% of anemia had a known cause (4). Among the atypical causes of anemia in the elderly, definitely, there is Heyde's syndrome. This condition which is associated with angiodysplasia and aortic stenosis was described in 1958 by Heyde (5) and defined as such in 1992 by Olearchyk (6) and that's pathogenesis is still debate in the literature. Here we present a clinical case.

CASE

A 83 years old woman admitted for fatigue and dyspnea with exercise and presence of cognitive impairment. The symptoms have occurred since a few months The patient already had a history of moderate-to-severe aortic stenosis but the hemodynamic status was stable.

The patients weight, height, body mass index (BMI) and body surface area (BSA according to DuBois) were 63 kg, 159 cm, 24.9 kg/m², 1.65 m², respectively. The woman was in discrete conditions; vital signs and hemodynamic signs were normal except tachycardia (HR 104 bpm); there were no signs of peripheral and pulmonary stasis. At the inspection we observed a waxy pallor of the skin, hypoelastic cutis with mild dehydration. The visible mucous membranes were pale. The multidimensional assessment indicated a Mini-Mental State Examination Test (MMSE) of 25/30, with normal Activities Daily Living (ADL 6/6) and Instrumental Activities of Daily Living

Member of the Italian Federation of General Practitioners (Federazione Italiana dei Medici di Medicina Generale - FIMMG)

Received: 02.01.2014, Accepted: 12.05.2014

Correspondence: Member of the Italian Federation of General Practitioners (Federazione Italiana dei Medici di Medicina Generale - FIMMG)

Parameter	Units of measure	values at the lower limit	normal high limit
white blood cells	X 10 ³ /mm ³	4.8	10.8
red blood cells	X 10 ⁶ /mm ³	4.2	5.4
hemoglobin	g/dl	12	16
hematocrit	%	37	47
MCV	fL	81	99
mch	pg	27	31
MCHC	g/dl	33	37
rdw	%	11.5	14.5
ldw	g/dl	2.2	3.2
platelets	X 10 ³ /mm ³	130	400
Comment	Anisomacrotosis and hypochromia of the red cells		

Figure 1. Blood tests of patient

(IADL with preserved functions 8/8), so the patient was categorized as "minimal cognitive impairment". We ordered echocardiography for monitoring valvular heart disease and blood tests, resulting a severe anemia of Hb 6.9 g/dl requiring transfusion of packed red blood cells and subsequent treatment with iron and folate, with satisfactory achievement of hemoglobin goal (Figure 1). The remaining parameters were normal except creatinine (1.12 mg/dl, creatinine clearance calculated by the Cockcroft and Gault formula was 37.8 ml/min). Echocardiography showed an enlarged left atrium with an interventricular septal hypertrophy of moderate severity, aortic stenosis (mean aortic gradient 53,2 mm Hg, LVEF 77%) with calcified valve cusps, moderate mitral regurgitation and mild to moderate tricuspid regurgitation (Figure 2).

We tried to investigate the patient looking for one or more pathological conditions that could explain the big picture as a whole(7). The symptoms reported were not part of the prodromal symptom of dementia (MMSE , ADL and IADL were normal) (8-10). Aortic valve stenosis (previously known) was confirmed with echocardiography, but dyspnea was certainly exacerbated by the anemic condition. The hypercreatininemia, detected on multiple testing in a extremely dehydrated patient could not justify the degree of anemia detected on the analysis, requiring a transfusion (11,12). The iron levels, the folate and vitamin B12 values were normal (13). The patient was underweight (BMI 24.9) and nutritional parameters (albumin, lymphocytes) were good (14). The drug history was inconclusive: the patient did not take antiplatelet agents, corticosteroids, non-steroidal anti-inflammatory drugs or other gastrolesive medications. The fecal occult blood test appeared firstly negative on a single control (enzymatic method) and subsequently



Figure 2. Findings of echocardiography

on three positive samples in series.

The hypochromic normocytic anemia with low value of red blood cells arose the suspicion of chronic blood loss of unknown origin: gastric polyps, colonic diverticula, hemorrhoids, cancer of the left colon/rectum/right colon. Therefore endoscopic examinations were required that could clarify one or more episodes of occult bleeding, subsequently worsening oxygenation and causing symptoms in a patient with severe aortic valvular disease. The gastroscopy report was normal while the enteroclysis showed "a diverticulosis of the colon , the presence of internal hemorrhoidal swelling" and the colonoscopy showed "the presence of some diverticula in the sigmoid and descending colon, gaping at collar and intact mucosa." Then, it was treated anaemia, returning to appear again some time later, although with less severe values less (Hb 8.9 g/dl) compared with the previous episode. A new colonoscopy showed "normal distal ileum, no significant lesions at the level of the bottom and right colon, nothing in the rectum, anal mucosal congestion", so the patient continued cycles of iron therapy. It was decided to conduct a videocapsule enteroscopy was pointed out that : "...at the level of fasting shows small area of mucosal hyperemia suspected to angiodysplasia" (Figure 3). At this point the patient is subjected to an angiography of visceral vessels with transfemoral approach and selective cath-

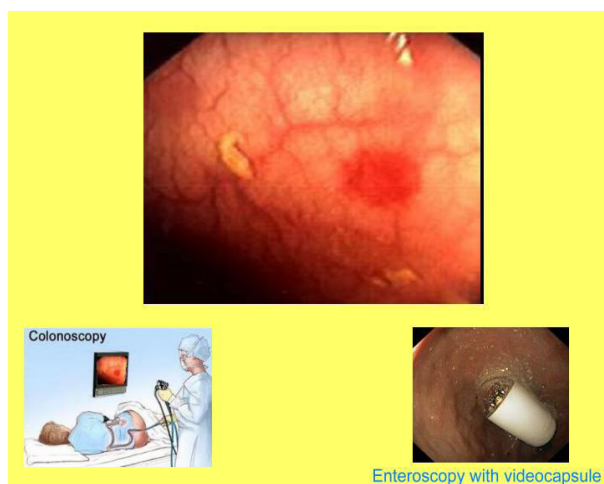


Figure 3. Videocapsule enteroscopy

eterization of the superior mesenteric artery. The initial mesenteric angiography documented "the presence of a few small foci of increased vascularization at the expense of fasting and the first part of the ileum, consistent with small angiodysplastic areas." Then the patient was treated with embolization for partial bowel angiodysplasia of jejunum and ileum of the first section in a patient with degenerative aortic stenosis with mild regurgitation of media entities. Subsequently, gastroprotective therapy was prescribed under periodic medical follow-up. In the remainder of the follow-up the patient was asymptomatic and kept in fairly good general condition, fairly stable hemoglobin values and less need for the implementation of iron therapy.

DISCUSSION

The Heyde's syndrome describes the association between severe aortic stenosis and bleeding from the digestive tract in the elderly with a greater propensity for occult or overt bleeding of the upper digestive tract in patients with intestinal angiodysplasia. Angiodysplasia of the colon is a degenerative, acquired lesion represented by the presence of dilated veins (vascular ectasia) and distorted veins in the mucosa of the small intestine and colon, which can cause gastrointestinal bleeding; microscopically they look similar to racemous hemangiomas of the skin and they appear as star-shaped vessels that branch into the submucosa with sizes ranging from 2 to 1 cm in diameter. Usually the lesions are

multiple and they are primarily found in the caecum and ascending colon, but they may also arise from the stomach to the rectum. The diagnosis is based on colonoscopy, enteroscopy with videocapsule and selective mesenteric angiography, which has a high degree of diagnostic accuracy (15-21).

The pathogenesis of the syndrome, yet the subject of interesting debate, is multifactorial. While the severe calcific aortic stenosis may induce a chronic ischaemia of the colonic mucosa with possible outcome of angiodysplasia (ischaemia induces the formation of angiogenic factors), on the other hand the same valvulopathy is seen to be associated with a primary abnormality of hemostasis with increased bleeding time: under conditions of high stress/trauma (such as in the presence of heavily calcified aortic cusps), a platelet dysfunction is established, elongation of bleeding time reveals itself with longer bleeding in different locations and bleeding diathesis, as well as von Willebrand syndrome (factor VIII deficiency). In fact, the aortic stenosis may lead to a defective larger reversible polymer von Willebrand factor (exposed to high flow through the stenotic aortic valve) and explain the association with intestinal bleeding especially the venous ectasia, already frequent in the elderly. For this reason, some authors reported a complete remission of bleeding after aortic valve replacement, so as to offer surgery as the choice of therapy (22-27).

The treatment of this case, nevertheless too invasive, suggested a different alternative to the surgical treatment of aortic stenosis (aortic valve replacement) as embolization after selective catheterization, with improved quality of life and the use of smaller number of cycles of iron therapy. However, recently, has been described that Transcatheter Aortic Valve Implantation (TAVI) is also an effective treatment able to reduce future gastrointestinal bleeding in patients with Heyde syndrome at high-risk for traditional surgery (28). In this case the interventricular septal hypertrophy of moderate severity, the presence of valvular calcification, the presence of moderate mitral regurgitation, the difficulties of a precise quantification of the diameter of the left ventricular outflow tract with the Doppler was affected by the decision to proceed with TAVI. Both conditions - aortic stenosis and intestinal angiodysplasia - are relatively frequent in the elderly, and the latter is a well-recognized cause of bleeding often hidden in these patients. The case emphasizes careful evaluation

of anemia in the elderly population due to its atypical manner as seen in this case, in order to make appropriate choices avoiding both the turnout uncritical that a finalistic interventionism.

REFERENCES

1. Carmel R. Anemia and aging: an overview of clinical, diagnostic and biological issues. *Blood Rev* 2001; 15(1): 9-18.
2. McCormick L, Stott DJ. Anemia in elderly patients. *Clin Med* 2007;7(5):501-4.
3. Guralnik JM, Ershler WB, Schrier SL, et al. Anemia in elderly: a public health crisis in hematology. *Hematology Am Soc Hematol Educ Program* 2005:528-32.
4. Guralnik JM, Eisenstaedt RS, Ferrucci L, et al. Prevalence of anemia in persons 65 years and older in the United States: evidence for a high rate of unexplained anemia. *Blood* 2004; 104(8):2263-8.
5. Heyde EC. Gastrointestinal bleeding in aortic stenosis. *N Engl J Med* 1958; 259: 196.
6. Olearchyk AS. Heyde's syndrome. *J Thorac Cardiovasc Surg* 1992; 103 (4): 823-4.
7. Makipour S, Kanapuru B, Ershler WB. Unexplained anemia in the elderly. *Semin Hematol* 2008;45(4):250-4.
8. Hong CH, Falvey C, Harris TB, et al. Anemia and risk of dementia in older adults: findings from the Health ABC study. *Neurology* 2013 6;81(6):528-33.
9. Weuve J, Mendes de Leon CF, Bennett DA, et al. The Red Cell Distribution Width and Anemia in Association With Prevalent Dementia. *Alzheimer Dis Assoc Disord* 2013 6.
10. Andro M, Led Squere P, Estivin S, Gentic A. Anaemia and cognitive performances in the elderly: a systematic review. *Eur J Neurol* 2013;20(9):1234-40.
11. McClellan W, Aronoff SL, Bolton WK, et al. The prevalence of anemia in patients with chronic kidney disease. *Curr Med Res Opin* 2004;20 (9):1501-10.
12. Ble A, Fink JC, Woodman RC, et al. Renal function, erythropoietin, and anemia of older persons: the InCHIANTI study. *Arch Intern Med* 2005;89(3):549-61.
13. Andrés E, Affenberg S, Vinzio S, et al. Food-cobalamin malabsorption in elderly patients: clinical manifestations and treatment. *Am J Med* 2005;118(10):1154-59.
14. Carmel R. Nutritional anemias and the elderly. *Semin Hematol* 2008;45(4):225-34.
15. Dos Santos VM, Dos Santos LA, Modesto AA, Amui MO. Heyde syndrome in a 71-year-old man who underwent chest radiotherapy at young age. *An Sist Sanit Nacar* 2013 6;36(2):339-45.
16. Figuinha FC, Spina GS, Tarasoutchi F. Heyde's Syndrome: Case Report and Literature Review. *Arq Bras Cardiol*. 2011;96(3):e42-5.
17. Vaz A, Correia A, Martins B, Capelo J, Ferreira P, Henriques P, Santos O. Heyde syndrome - The link between aortic stenosis and gastrointestinal bleeding. *Rev Port Cardiol* 2010;29(2):309-14
18. Garcia-Martin A, Moreno A, Moro C. Heyde's Syndrome. *Rev Esp Cardiol* 2011;64(1):75-7
19. Martinez-Caselles A, Martinez-Pascual C, Sánchez-Torres Am Carballo-Alvarez F. Beyond Heyde's syndrome. *Rev Esp Enferm Dig* 2012;104(11):615-6.
20. Gola W, Lelonek M. Clinical implication of gastrointestinal bleeding in degenerative aortic stenosis: an update. *Cardiology Journal* 2010, Vol. 17, No. 4: 330-4
21. Love JW. The syndrome of calcific aortic stenosis and gastrointestinal bleeding: resolution following aortic valve replacement. *J Thorac Cardiovasc Surg* 1982; 83: 779-83.
22. Granel B, Serratrice J, Bernit E, et al. Heyde syndrome. *Presse Med* 2002; 31: 1451-3.
23. Massyn MW, Khan SA. Heyde syndrome: a common diagnosis in older patients with severe aortic stenosis. *Age Ageing* 2009 10.
24. Maor NR. Heyde Syndrome: Resolution of Anemia after Aortic Valve Surgery. *Isr Med Assoc J* 2013;15(7): 387-9.
25. Gandhi V, Philip S, Nagral S. Heyde Syndrome. *Tropical Gastroenterology* 2010;31(2):120-1.
26. Baliga RR. From Clinical Observation to Mechanism-Heyde's Syndrome. *N Engl J Med* 2013 7;368(6):579.
27. Loscalzo J. From Clinical Observation to Mechanism-Heyde's Syndrome. *N Engl J Med* 2013 7;368(6): 579-80.
28. Godino C, Lauretta L, Pavon AG, et al. Heyde's syndrome incidence and outcome in patients undergoing transcatheter aortic valve implantation. *J Am Coll Cardiol* 2013 12;61(6):687-9.