

NEUROBRUCELLOSIS

Deniz Tuncel¹, Hasan Uçmak², Mustafa Gokce¹, Uygur Utku¹

Kahramanmaraş Sutcu Imam University Medical Faculty, Departments of Neurology¹ and Clinical Microbiology and Infectious Diseases², Kahramanmaraş, Turkey

In 5-10% of cases of brucellosis may lead to central nervous system manifestation presenting most often as a meningitis or meningoencephalitis. We report three neurobrucellosis who have different presentation. First patient; a 49-year-old-woman who developed diffuse cerebral white matter lesions as leukoencephalopathy associated with neurobrucellosis, presented with gait disturbance, behavior change and seizure. Second patient; 44-year-old man was admitted to our hospital with a complaint of progressive motor weakness in his bilateral legs for four months and headache for one year. The patient's symptoms may be explained with myeloradiculopathy and meningoencephalitis but the clinical picture didn't correlate with imaging findings. Third patient; 23-year-old man was admitted to our hospital with a complaint of transient numbness attacks in his left of face and hand and headache for twenty days. He presented as meningitis which is the most clinical presentation of neurobrucellosis and meningovascular complications. Conclusively, brucellosis is still endemic in Turkey and thus neurobrucellosis should be considered in the unexplained neurological symptoms such as cognitive dysfunction, young transient ischemic attacks, paraparesis and psychiatric symptoms.

Key words: Neurobrucellosis, leukoencephalopathy, transient ischemic attack, paraparesis

Eur J Gen Med 2008;5(4):245-248

INTRODUCTION

Human brucellosis is now a rare disease in countries where eradication programs (especially vaccination) against brucellosis in cattle, sheep, and goats have been successfully implemented. Human brucellosis, however, remains endemic in the Mediterranean basin, Middle East, Western Asia, Africa, and South America. The disease is mainly transmitted to humans through the ingestion of raw milk or non-pasteurized cheese contaminated with one of the four *Brucella* species pathogenic to humans. The clinical presentation can vary from asymptomatic infection with seroconversion to a full-blown clinical picture of fever, night sweats and joint manifestations; rarely, there is hepatic, cardiac, ocular or central nervous system involvement (1, 2).

Neurobrucellosis occurs in 5–10% of cases of brucellosis and affects the central (CNS) or peripheral nervous system (PNS). These manifestations are diffuse

encephalopathy/meningoencephalitis, inflammatory peripheral neuritis/radiculitis, inflammatory demyelinating syndromes, papilledema or papillitis without other focal features, meningomyelitis, posterior fossa (ataxic or brainstem) syndromes, and neuropsychiatric syndromes (3-10).

We report three neurobrucellosis who have different presentation, and than discuss with literature.

CASE 1

A 49-year-old-woman presented with gait disturbance, behavior change and seizure. In past history, the first symptoms developed postpartum third month in 2003 with nausea, vomiting and vertigo. She gradually weight lost and then had seizures consisting of tonic-clonic movements in February 2004. Tinnitus occurred in the last month of 2004 and then partial hearing loss developed. The patient has experienced a gradual, slowly progressive neurocognitive decline such

Correspondence: Deniz Tuncel, MD
Kahramanmaraş Sutcu Imam University, Faculty of Medicine, Department of Neurology, Kahramanmaraş, Turkey, 46060
Tel: 903442212760, Fax: 903442212371
E-mail: tuncedeniz@yahoo.com

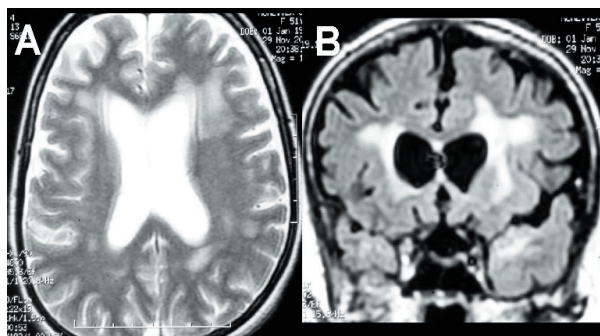


Figure 1. T2-weighted cranial MR (A) and FLAIR MRI (B) showed frontoparietal cortical atrophy, arachnoid cyst on the right parietal vertex and diffuse, bilateral T2-hyperintense lesions which like leukoencephalopathy.

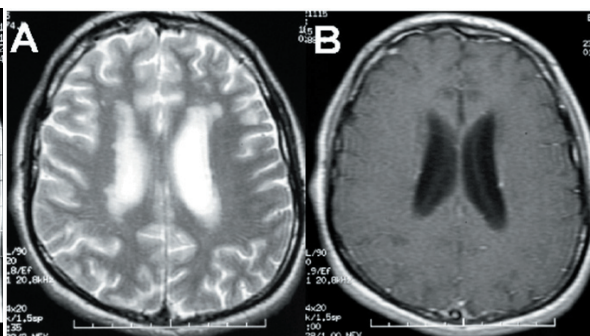


Figure 2. T2-weighted cranial MRI (A) and FLAIR MRI (B) revealed that cortical atrophy and hyperintense lesions in the centrum semiovale and corona radiata.

amnesia and difficulty performing activities of daily living, and gait disturbance for two years. General physical examination was normal. Vital parameters were normal. Neurologically, she was conscious, but uncooperative. There were cognitive impairment in verbal fluency, loss of recent memory, copying of written figures, attention and calculation (MMSE: 16/30), dysarthria, ataxia, bilateral sensorineural hearing loss, weakness of upper proximal extremities (MRC grade: 4/5). The deep tendon reflexes were hyperactive and Mayerson and Snout reflexes were positive. Hemogram revealed mild leucopenia. Biochemistry and erythrocyte sedimentation rate (ESR) were normal. Serologic studies for known autoimmune and hematological disorders, Anti HIV, hepatitis C, A, B surface antigens and anti-hepatitis B surface antibodies were negative. Lumbar puncture yielded xanthochromic cerebrospinal fluid (CSF) at normal opening pressure with low glucose (38mg/dl) and elevated protein at 526mg/dl. Spinal fluid showed few leukocytes. Brucella (capt test) tube agglutinin was positive at 1/2560 titers in blood and positive at spot and 1/2560 titers in CSF. The electrocardiogram and echocardiography were normal. Electroencephalogram was generalized moderate slow. Cranial magnetic resonance imaging (MRI) revealed frontoparietal cortical atrophy, arachnoid cyst on the right parietal vertex and diffuse, bilateral T2-hyperintense lesions which like leukoencephalopathy. The

lesions were not enhanced (Figure 1). She had experienced epileptic seizures controlled with phenytoin sodium (oral 300mg/daily). The patient was empirically treated with ceftriaxone 2x1g/day by intravenously. Rifampicin (600mg/daily), doxycycline (200mg/daily) and trimethoprim/sulfamethaxazole (320/1600mg/daily) were added to antibiotic regimen. The ceftriaxone ceased at 14th day of treatment, combined treatments were continued. In the control examination after two weeks and one month, her mental status (respectively; MMSE: 19/30, 27/30) and physical performance were gradually partly improved.

CASE 2

The patient, 44-year-old man was admitted to our hospital in 2005 with a complaint of progressive motor weakness in his bilateral legs for four months and headache for one year. In his past medical history, he has chronic psychosis diagnosis for 15 years and used olanzapine. His behavioral disturbance increased during last months. His physical examination was normal. His temperature was 37°C. He was conscious, but uncooperative and has significant behavioral abnormalities such as distractibility, impulsivity, loss of insight, personal and social awareness, disinhibition and impaired cognitive functions. Neurological examination revealed significant reduction of speech, bilateral lower leg motor weakness (MRC grade: 3-4/5), bilateral Babinski's sign, hyperactive deep tendon reflexes and

ambulatory walking. Routine hematological and biochemical parameters were normal. Erythrocyte sedimentation rate (ESR) was 18mm in 1 hour. The hepatic markers, anti HIV, VDRL were negative. PPD was 10mm and CSF on admission showed xanthochromia, $64\text{cells}/\text{mm}^3$ (mostly lymphocytes), glucorrachia/glycemia of 26/99mg/dL, and a protein concentration of 306,9mgr/dL. CSF pressure was 140mmHg. The brucella Wright agglutinin was positive at 1/2560 titers in blood. CSF brucella wright test titer was 1/320. Brucella spot and IgM-ME were positive in CSF. T2-weighted cranial MRI showed that cortical atrophy and hyperintense lesions in the centrum semiovale and corona radiata (Figure 2). The spinal MRI without contrast agent was normal range. The ceftriaxone treatment was given 2x2g/day for 14 days. Rifampicin (900mg/daily), doxycycline (400mg/daily) and trimethoprim/sulfamethaxazole (320/1600mg/daily) were added to antibiotic regimen and continued. But, the patient did not use his drugs regularly and reduced titer, still serologically brucella positive.

CASE 3

The 23-year-old man was admitted to our hospital with a complaint of transient numbness attacks in his left of face and hand and headache for twenty days. This numbness attacks were lasting at most one hour. The headache was severe, bifrontal and including neck pain, accompanied by nausea and phonophobia, and could be triggered by physical exercise. The headache duration was approximately one hour. His physical examination was normal. Neurological examination revealed hypoesthesia on the left mental region of face and increased deep tendon reflexes. Laboratory tests including the complete blood count, erythrocyte sedimentation rate, biochemical tests, urine analysis, and serologic studies for known autoimmune and hematological disorders were normal. The thyroid function tests and vitamin B12 were within normal range. The homocysteine level was normal. Cerebrospinal fluid (CSF) examination revealed increased pressure ($300\text{mmH}_2\text{O}$), xanthochromia with microscopically few dense leucocytes and lymphocytes, low glucose (8mg/dl) and elevated protein at 555mg/dl. The

tuberculosis PCR was negative in the CSF. The brucella wright agglutinin and antihuman globulin were positive in CSF (respectively; 1/60 titers, 1/160 titers). The electrocardiogram and echocardiography were normal. Cranial magnetic resonance imaging (MRI) revealed periventricular and meningeal enhancement with edema, and mildly hydrocephaly. The hyperintense lesion was seen in the right periventricular white matter. Rifampicin (600mg/daily), doxycycline (200mg/daily) and trimethoprim/ sulfamethaxazole (320/1600mg/daily) were started. In the control examination after one month, his headache and numbness were completely improved.

DISCUSSION

Brucellosis is an endemic zoonosis in Southern Turkey (5). Our three patients had a history of fresh cheese consumption and accidental contamination from infected animals or animal products and live in endemic region of Turkey. Neurobrucellosis is a rare complication of brucellosis and sometimes neurological symptoms may be the only symptoms. The criteria for definite diagnosis of neurobrucellosis are 1-neurological dysfunction not explained by other neurological diseases, 2-abnormal CSF indicating lymphocytic pleocytosis and increased protein, 3-positive CSF culture for *Brucella* organisms or positive *Brucella* IgG agglutination titer in the blood and 4-CSF, response to specific chemotherapy with a significant drop in the CSF lymphocyte count and protein concentration (4, 5, 8). We presented three different clinic forms of neurobrucellosis which fulfilled all the diagnostic criteria. The first patient developed diffuse cerebral white matter lesions as leukoencephalopathy associated with neurobrucellosis. Her symptoms were weakness, bilateral sensorineural hearing loss, progressive neurocognitive decline and seizure. Neurobrucellosis very rarely involves the white matter and causes demyelination. The cause of these lesions is still controversial. Seidel et al. (11) reported that direct cytotoxic damage could mediate some of the observed white matter changes in cases of chronic disease. The organism may act directly or indirectly through its endotoxins (11). In the chronic forms, immune mediated demyelination has been proposed (7, 11).

Our patients give a good response to the treatment and cognitive functions and weakness started to improve.

Second patient's symptoms may be explained with myeloradiculopathy and meningoencephalitis. He has chronic psychosis diagnosis and the behavioral disturbance increased for few months. The leg weakness was occurred for four months. The psychiatric manifestations in neurobrucellosis were depression, psychosis, agitation, personality disorder and euphoria (2, 5, 6). His present psychotic symptoms may be gradually increased by neurobrucellosis. An addition, his cognitive functions were severely declined. The spinal cord or nerve root may secondarily be involved by brucella due to spondylitis, vasculitis and arachnoiditis (2, 4). Our patient's spinal MRI was normal but due to lack of contrast study and technical causes, may not be evaluated properly. T2-weighted cranial MRI showed hyperintense lesions. Al Sous et al. showed that the imaging does not always correlate with the clinical picture as our present case (2).

The third patient presented as meningitis which is the most clinical presentation of neurobrucellosis and meningovascular complications (8-10, 13). His cranial MRI showed that meningeal enhancement with periventricular edema which seen on brain imaging in the early phase of brucellar meningitis. He had experienced headache and transient ischemic attacks with numbness in the left of body. The pathogenesis of ischemic attacks still remains unknown. Vasospasm and infectious vasculitis may be the cause. An additional differential diagnosis includes recurrent emboli from brucella endocarditis (6). Other causes of TIA including hypercoagulability, systemic vasculitis and cardiac embolism were excluded in our patient. The patient's attacks and headache discontinued with the treatment.

There are no specific antibiotic regimens and duration of treatment for neurobrucellosis. The duration of treatment varies from 8 weeks to 2 years. Rifampicin, doxycycline and trimethoprim/sulfamethaxazole have been found effective and good central nervous system penetration and synergistic actions (1, 3, 5). We have used these antibiotics and the duration of treatment was selected

depending upon individual cases.

In conclusion, brucellosis is still endemic in Turkey and presents a major public health, clinical, and diagnostic problem. Neurobrucellosis should be considered in the unexplained neurological symptoms such as cognitive dysfunction, transient ischemic attacks in a young, paraparesis and psychiatric symptoms.

REFERENCES

1. Young EJ. Brucella species. In: Mandell GL et al., editors. Principles and Practice of Infectious Diseases, Philadelphia: Churchill Livingstone; 2000. p. 2386-93
2. Al-Sous MW, Bohlega S, Al-Kawi MZ, Alwatban J, McLean D. Neurobrucellosis: clinical and neuroimaging correlation. *Am J Neuroradiol* 2004;25:395-401
3. Bouza E, Torre MG, Parras F, Guerrero A, Rodriguez-Creixems M, Gobernado J. Brucellar meningitis. *Rev Infect Dis* 1987;9: 810-22
4. Pascual J, Combarros O, Polo JM, Berciano J. Localized CNS brucellosis: report of 7 cases. *Acta Neurol Scand* 1988;78:282-9
5. Bodur H, Erbay A, Akıncı E, Çolpan A, Çevik MA, Balaban N. Neurobrucellosis in an endemic area of brucellosis. *Scand J Infect Dis* 2003;35:94-7
6. Eren S, Bayam G, Ergönül Ö and et al. Cognitive and emotional changes in neurobrucellosis. *J Infection* 2006;53:184-9
7. Koussa S, Chernaly R. Neurobrucellosis presenting with diffuse cerebral white matter lesions. *Eur Neurol* 2003;50:121-3
8. Bingöl A, Togay-Işıkay C. Neurobrucellosis as an exceptional cause of transient ischemic attacks. *Eur J Neurol* 2006;13:544-8
9. Ghosh D, Gupta P, Prabhakar S. Systemic brucellosis with chronic meningitis. *Neurol India* 1999;47:58-60
10. Banerjee TK, Pal AK, Das S. Neurobrucellosis presenting as acute meningoencephalitis. *Neurol India* 1999;47:160
11. Seidel G, Pardo CA, Newman-Toker D, Olivi A, Eberhart CG. Neurobrucellosis presenting as leukoencephalopathy. *Arch Pathol Lab Med* 2003;127:374-7
12. Vjramani GV, Nagmoti MB, Patil CS. Neurobrucellosis presenting as an intramedullary spinal cord abscess. *Ann Clin Microbiol Antimicrob* 2005;4:1-5
13. Adaletli I, Albayram S, Gurses B and et al. Vasculopathic changes in the cerebral arterial system with neurobrucellosis. *AJNR* 2006;27:384-6