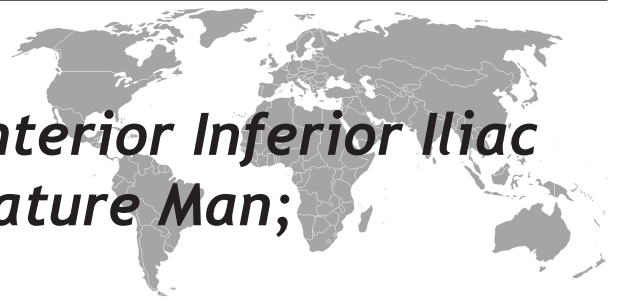

# Avulsion Fracture of Anterior Inferior Iliac Spine in a Skeletally Mature Man; Mimicking Pathologic Bone Lesion



Cüneyt Tamam<sup>1</sup>, Düzgün Yıldırım<sup>2</sup>

Kasımpasa Military Hospital, Departments of Orthopaedics and Traumatology,<sup>1</sup> and Radiology<sup>2</sup>, Istanbul, Turkey

Eur J Gen Med 2011;8(1):82-4

Received: 29.05.2010

Accepted: 17.08.2010

## ABSTRACT

Avulsion fractures of the pelvis occur in both the skeletally immature and adult patient populations the patho-mechanism is the sudden forceful contraction of the related muscle. The case reported here is an overlooked case of anterior inferior iliac spine avulsion fracture in a 25-year-old man, misinterpreted as malignant pathology. Avulsion fractures of the anterior inferior iliac spine can be diagnosed with medical history and radiological methods. The physician must be cautious during the assessment of the patient with complaint in his/her groin and keep in mind the possibility of an anterior inferior iliac spine fracture.

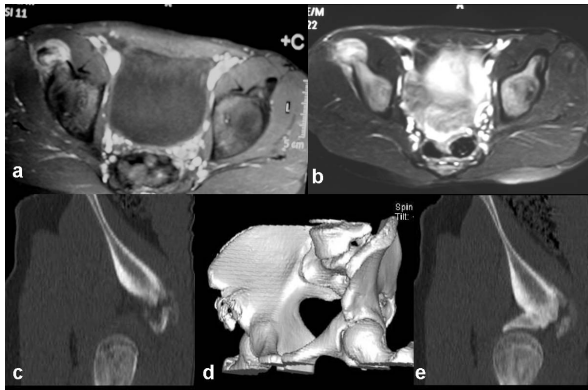
**Key words:** Avulsion fracture, pathologic bone lesion, anterior inferior iliac spine

## Erişkin Bir İnsanda Anterior Inferior İliyak Vertebra'nın Avulsiyon Kırığı

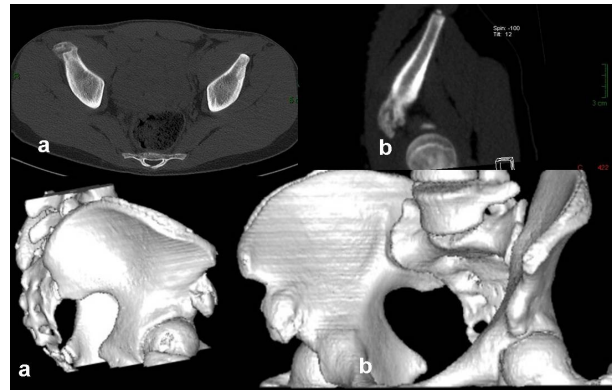
Erişkin ve ergen hasta gruplarında oluşan meydana gelen pelvis avulsiyon kırıklarının oluşum mekanizması ilgili kasların ani olarak şiddetli kasılmasıdır. Bu olgu sunumunda 25 yaşında erkek hastada gözden kaçmış bir anterior inferior iliyak avulsiyon kırığının, malignite olarak değerlendirilmesini sunduk. Anterior inferior iliyak avulsiyon kırığına doğru yaklaşım ile tıbbi öykü ve radyolojik yöntemlerle tanı konulabilir. Kasık ağrılarında hasta dikkatli değerlendirilmeli ve pelvik avulsiyon kırıkları göz önünde bulundurulmalıdır.

**Anahtar kelimeler:** Avulsiyon kırığı, patolojik kemik lezyonu, anterior inferior iliyak vertebra

**Correspondence:** Cüneyt Tamam,  
Kasımpasa Military Hospital Istanbul /  
Turkey  
Tel: +90 532 5998569  
E-mail: ctamam@yahoo.com



**Figure 1.** a) MRI T2w/ axial image shows a hyper intense globular soft tissue thickening in contact with AIIS. b) Thick peripheral contrast enhancement after administration of intravenous Gd-DTPA. c) CT shows an avulsion of the AIIS apophysis with a 6mm gap on the saggital reformatted image.



**Figure 2.** Control CT examination after 2 months. Axial CT section shows the near complete fusion of the previously displaced fragment by partially ossified callus. Multiprojection 3D images also show the fusion through the healing period.

## INTRODUCTION

Avulsion fractures of the pelvis occur in both the skeletally immature and adult patient populations, as a result of trauma or overuse. They often most occur in the young active athlete between 14 and 23 years of age with the same mechanism of injury that would result in a musculotendinous injury in the skeletally mature athlete (1). The patho-mechanism of avulsion fractures is the sudden forceful contraction of the related muscle (2). Unlike avulsion fractures of the anterior superior iliac spine, the iliac crest and the pubic bone, fractures of the anterior inferior iliac spine (AIIS) are rarely encountered. Avulsion fractures of the anterior inferior iliac spine are most commonly associated with sprinting activity, causing a sudden pull of rectus femoris muscle during forceful extension of the hip (2). Avulsion fractures of the anterior inferior iliac spine can be diagnosed with medical history and radiological methods. The physician must be cautious during the assessment of the patient with complaint in his/her groin and keep in mind the possibility of AIIS fracture. We report an overlooked case of anterior inferior iliac spine avulsion fracture misinterpreted as malignant pathology.

## CASE

A 25-year-old man was referred to our clinic with a 3-week history of persistent right groin pain. The onset

of pain was sudden during a forceful game of soccer. In his medical history, he had referred to a clinic just after the onset of the symptoms. He had a groin pain radiating to his thigh. No x-ray was taken. The diagnosis ‘muscle rupture’ was based on physical examination. He was treated with rest, analgesia and physiotherapy. He continued to have pain in his groin. The pain worsened and started to be nocturnal by time. Inspection of his lower extremities and pelvis revealed no pathological findings. Range of movement of both hips was within normal limits. Muscular weakness was seen during flexion of the hip and extension of the knee. Considering the history, malignancy was suspected and magnetic resonance imaging (MRI) was applied. Axial T2 weighted MRI images showed a hyper intense globular soft tissue thickening in contact with AIIS (Figure 1a). Axial T1 weighted MRI images demonstrated a heterogeneous lesion with contrast enhancement including located in the anterior inferior iliac spine after administration of intravenous Gd-DTPA (Figure 1b). To eradicate malignancy (parosteal osteosarcoma) computerized tomography scan was applied. Pelvic CT revealed a bone fragment displaced inferiorly about 6mm from the right anterior inferior iliac spine on 3D image irregularity is seen besides the avulsion of the AIIS apophysis (figure 1c). Conservative treatment consisted of a nonsteroidal anti-inflammatory drug and limited weight bearing with crutches was employed. Passive-assisted range-of-motion exercises

were started as soon as pain allowed. After 8 weeks a control computerized tomography was taken. Axial CT section revealed the fusion of the fragment with ossified callus formation eradicating malignancy (figure 2). The patient was informed that data from the case would be submitted for publication, and gave his consent.

## DISCUSSION

Avulsion fractures of the anterior inferior iliac spine are less frequent than other pelvic avulsions with an incidence of 14.8-22.1%, possibly because of early apophyseal closure of the others (3). They usually occur in adolescents between the ages of 14 and 23 when the ratio of muscular strength to physeal strength is greatest (1-2). The mechanism of AIIS avulsion fractures is due to the pull of the straight head of the rectus femoris muscle. The pull may involve either concentric or eccentric muscular contraction of the straight head of the rectus femoris muscle. Concentric contraction of the rectus femoris occurs during push-off (acceleration), whereas eccentric contraction occurs during deceleration. Injuries due to concentric muscular contraction such as sprinting are more common than injuries resulted from eccentric motions, such as slipping (2). The diagnosis of AIIS fractures is generally established with distinctive medical history, physical examination and AP radiograph of pelvis. The age of our case is a potential diagnostic pitfall. It is unlikely to think the possibility of AIIS fracture in a skeletally mature patient in the first place. This situation may have led the physician to overlook the medical history of the patient. On physical examination the avulsed fragment of AIIS may not be palpated because AIIS lies deep near the sartorius and iliopsoas muscles (4). Thus it is difficult to localize the pain and the exact area of the pathology. The characteristic of the pain in AIIS fracture is another condition that mislead the physician to consider a musculotendinous injury. It is generally persistent and radiates to the thigh. In this case, the persistency and the nocturnal character of pain resembled malignancy more than an avulsion of AIIS. The AIIS avulsion fracture must be differentiated from os acetabuli (an accessory ossicle at the superior rim of the acetabulum), traumatic myositis ossificans (calcification of the straight head of rectus femoris) and bony tumours (2).

The diagnostic radiological method in detecting AIIS fracture is AP radiograph of pelvis or computerized to-

mography. In our case, AP radiograph was not taken in initial examination which led to misdiagnosis. The AP radiograph of the pelvis should be interpreted with caution and the effected side should be compared with the other side since the avulsed fragment is generally minimally displaced inferiorly with the pull of the reflected head of rectus femoris (2). It may also be difficult to detect avulsion of AIIS on AP radiographs of the pelvis if the fracture fragment diameter is fewer than 2 cm. Oblique views of the pelvis may demonstrate a non-displaced or minimally displaced fracture fragment better (5). In our case pelvic computerized tomography revealed a bone fragment displaced inferiorly about 6mm from the right anterior inferior iliac spine. Although Ouellette et al stated that the magnetic resonance image findings underscore the importance of MR imaging in detecting rectus femoris originated injuries in the acute setting; the acute MRI findings of our case resembled a pathological lesion (6). Since osteosarcoma may present as a pathologic fracture, the presence of a sports-related injury still does not rule out the possibility of an underlying malignancy. To confirm the diagnosis, follow-up computed tomography is indicated (7). Thus, during the evaluation of the groin pain, clinical and radiological findings should be assessed together with the patient's history, and avulsion of AIIS should be kept in mind even in patients skeletally mature.

## REFERENCES

1. Rajasekhar C, Kumar KS, Bhamra MS. Avulsion fractures of the anterior inferior iliac spine: the case for surgical intervention. *Int Orthop* 2001;24:364-5.
2. Gomez JE. Bilateral anterior inferior iliac spine avulsion fractures. *Med Sci Sports Exerc* 1996;28:161-4.
3. Yildiz C, Yildiz Y, Ozdemir MT, Green D, Aydin T. Sequential avulsion of the anterior inferior iliac spine in an adolescent long jumper. *Br J Sports Med* 2005; 39:e31.
4. Atalar H, Kayaoglu E, Yavuz OY, Selek H, Uraş I. Avulsion fracture of the anterior inferior iliac spine. *Emergency Surgery J (Turkish)* 2007;13(4):322-5.
5. Sanders TG, Zlatkin MB. Avulsion Injuries of the Pelvis. *Semin Musculoskelet Radiol* 2008;12: 42-53.
6. Ouellette H, Thomas BJ, Nelson E, Torriani M. MR imaging of rectus femoris origin injuries. *Skeletal Radiol* 2006; 35:665-72.
7. Resnick JM, Carrasco CH, Edeiken J, Yasko AW, Ro JY, Ayala AG. Avulsion fracture of the anterior inferior iliac spine with abundant reactive ossification in the soft tissue. *Skeletal Radiol* 1996;25:580-4.