




A near miss case of placenta percreta at primary care: A case report

Nornadia Suhaimi¹ , Azlina Ishak^{1*} , Noraini Mohammad² 

¹Department of Family Medicine, School of Medical Sciences, Universiti Sains Malaysia, Kelantan, MALAYSIA

²School of Dental Sciences, Universiti Sains Malaysia, Kelantan, MALAYSIA

*Corresponding Author: drzalinakk@usm.my

Citation: Suhaimi N, Ishak A, Mohammad N. A near miss case of placenta percreta at primary care: A case report. *Electron J Gen Med.* 2023;20(1):em438. <https://doi.org/10.29333/ejgm/12691>

ARTICLE INFO

Received: 26 Sep. 2022

Accepted: 26 Oct 2022

ABSTRACT

We present a case of severe placenta percreta in a 33-year-old woman, gravida 9 para5+3, who presented to the health clinic with gross hematuria for three days at 16 weeks gestation. She had a history of multiple cesarean deliveries and uterine curettage. The diagnosis was suspected, and an urgent referral was made. Ultrasonography findings done by an obstetrician in a tertiary hospital confirmed the diagnosis. Unfortunately, the pregnancy had to be terminated as her condition deteriorated. Primary care practitioners should have high clinical suspicion to recognize this rare and life-threatening condition.

Keywords: first trimester, hematuria, placenta percreta

INTRODUCTION

Placenta accreta spectrum (PAS) disorders refer to the abnormal invasion of the trophoblastic tissue into the underlying uterus. Three types of PAS depend on the degree of invasion: placenta accreta, placenta increta, and placenta percreta. Trophoblastic tissue invasion in the placenta percreta involves the serosa and adjacent pelvic organs such as the urinary bladder, ureter, fallopian tube, or abdominal cavity [1]. Placenta percreta is a rare type of PAS that accounted for only 5% of all cases [2] and the incidence of urinary bladder bleeding is caused by placenta percreta is very low (0.36%) [3]. Urinary bladder bleeding due to placenta percreta has a poor prognosis as maternal and fetal mortality rates can increase as high as 9.5% and 2.4%, respectively [4]. Hence, early diagnosis and timely planned management are important. However, there are only limited case reports worldwide regarding urinary bladder bleeding due to placenta percreta, and none highlighting issues with regard to management in a primary care setting.

Therefore, we presented a near-miss case of atypical presentation of severe placenta percreta in primary care requiring urgent referral for evaluation and management to subsequently reduce maternal morbidity and mortality.

CASE REPORT

A 33-year-old housewife, G9P5+3 at 16 weeks gestation, presented to our health clinic with gross hematuria for three days. It was associated with painful micturition and suprapubic pain. The pain was episodic in nature, non-radiating, and had no obvious aggravating factors. She denied having vaginal bleeding, diarrhea, vomiting, fever, or trauma. There was no

history of passing sandy urine, having increased urinary frequency, or incomplete voiding. Before the current presentation, she already had three episodes of asymptomatic microscopic hematuria detected during her recent antenatal check-up, however, she was reassured and not investigated as it was claimed to be due to a poor urine collection method.

She has underlying non-transfusion-dependent beta-thalassemia, which was diagnosed ten years ago. Her obstetric history was marked by one early neonatal death due to anencephaly 11 years ago. Subsequently, she had three consecutive miscarriages within two years, requiring dilatation and curettage. She then had four cesarean deliveries, the last one was three years ago. Otherwise, there were no complications following deliveries such as post-partum hemorrhage, retained placenta, or endometritis. She was advised for bilateral tubal ligation during the third and fourth cesarean delivery, however, she refused. She has never practiced any contraception methods before.

Clinically, she was pale and afebrile. Her blood pressure was 112/69 mmHg, and her pulse rate was 98 beats/min. The pain score was 7/10. Her abdomen was soft with a uterus of 18 weeks size. There was tenderness at the suprapubic region but no tenderness at the pfannenstiell scar. Speculum examination revealed no significant findings. Other system examinations were unremarkable. An urgent full blood count test was sent, which showed a hemoglobin level of 7.1 g/dL with a hematocrit of 27.2%. Urinalysis revealed hematuria with no evidence of pyuria. Ultrasonography of the abdomen conducted at the health clinic revealed an anterior low-lying placenta with a viable fetus. All fetal parameters corresponded to the gestational age (**Figure 1**).

Based on clinical history and ultrasonography findings, urinary bladder bleeding secondary to PAS was highly suspected. Thus, she was immediately referred to a tertiary center for admission and assessment.

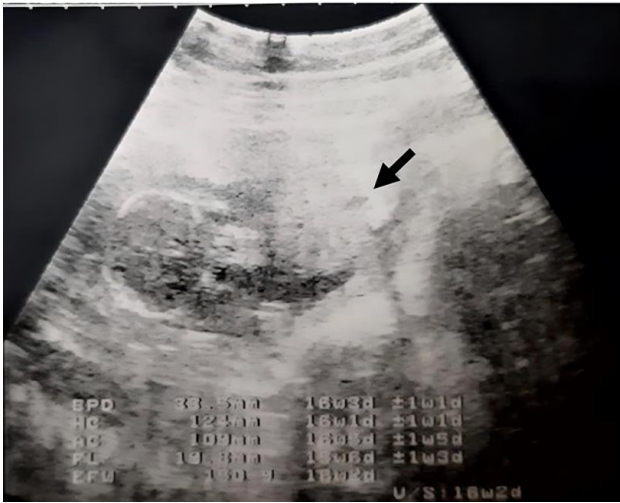


Figure 1. Grayscale ultrasonographic image showing anterior low-lying placenta (black arrow) (reprinted with permission of the patient)

At the tertiary center, detailed abdominal ultrasonography revealed anterior placenta tissue invasion into the bladder mucosa with blood clots within the urinary bladder. A cystoscopy performed by a urologist revealed a hyperemic urinary bladder with massive feeder vessels located over the anterior and lateral wall of the urinary bladder. At this stage, the diagnosis of placenta percreta was strongly suspected. Conservative management was initiated including continuous urinary bladder irrigation for blood clots evacuation, oral analgesic for pain control, and blood transfusion for her symptomatic severe anemia. The intravenous antibiotic was started on day three of admission to treat urinary tract infection and weekly fetal monitoring by ultrasonography was conducted.

Despite conservative management, her clinical condition deteriorated. A multidisciplinary conference was conducted, and the option of management was discussed. Post-optimization of her condition and blood parameters, termination of pregnancy, and hysterectomy with placenta in-situ concomitant with bilateral tubal ligation were arranged. Intraoperatively, the whole placenta, which had occupied the lower part of the uterus had embedded into the myometrium and invaded up to the left side of the urinary bladder with tortuous blood vessels. Hence, the diagnosis of placenta percreta was confirmed. Postoperatively, she recovered well and was discharged a week later. She was given a follow-up for intravenous methotrexate chemotherapy and weekly monitoring of serum beta-human chorionic gonadotrophin (β -hCG).

Upon follow-up at six weeks post-surgery, she developed symptomatic anemia secondary to gross hematuria. Serial serum β -hCG monitoring showed an increment from 64.9 milli-international units per milliliter (mIU/mL) to 656.6 mIU/mL. MRI pelvis was arranged and showed a placenta bulk measuring 4.4 centimeters (cm) width \times 4.3 cm length \times 2.5 cm depth with hypervascularity area extending from the anterior uterine wall until urinary bladder dome suggestive of the failure of chemotherapy. Thus, she was indicated for total abdominal hysterectomy and partial cystectomy. The uterine and placenta tissue was sent for histopathological examination. She was discharged well on day seven post-

operation. Later, a histopathological report, which came back later confirmed the diagnosis of placenta percreta.

DISCUSSION

Placenta percreta is the most severe and a very rare form of PAS [5]. Previous cesarean delivery is an essential contributing factor in placenta percreta, apart from uterine curettage, grandmultiparity, and myomectomy scar, which pose a certain risk for developing placenta percreta [2, 4]. The key particularity of our case is the existence of more than one previous cesarean section, uterine curettage for missed miscarriage, and grandmultiparity. The commonest clinical presentation of placenta percreta is painful antepartum hemorrhage (72%) and postpartum hemorrhage (68%). Accompanied abdominal pain is due to abruptio placenta or a warning sign of uterine rupture, a consequence of placenta percreta [6]. Meanwhile, hematuria is present only in 5% of patients [7]. Due to its atypical presentation, misdiagnosis, and delayed referral might occur as illustrated in our case during her initial antenatal visit. Thus, it was recommended that placenta percreta with bladder invasion should be suspected in any pregnant woman presenting with gross hematuria and a history of previous cesarean sections [7].

Even though diagnosing placenta percreta in the first trimester is difficult [8], it was emphasized the importance of patient surveillance to make a diagnosis beforehand as an early referral and appropriate management can be done to prevent catastrophic complications [9]. The scoring system with the combination of specific ultrasonography findings and maternal high-risk characteristics provides high sensitivity (93.4%) and specificity (82.3%) to diagnose the disease as early as 11 to 14 weeks [9]. One of the specific transvaginal ultrasonography findings suggestive of placenta percreta in the first trimester is anterior low implantation of the gestational sac [9]. However, with regards to our case, which presents in the first trimester at primary care setting, a few limitations are recognized including lack of accessibility to transvaginal ultrasonography and poor transabdominal ultrasonography quality, which make interpretation of the findings during her initial visit difficult.

In the case of placenta percreta, termination of pregnancy must be tailored to the individual circumstances. The likelihood of a hysterectomy, the dangers of severe hemorrhage that could lead to maternal death, and treatment options for the patient and spouse should all be discussed. After knowing that the pregnancy could not be prolonged as it may endanger the mother's life, the patient and her spouse reacted as expected.

There are two major management options for placenta percreta with bladder invasion including cesarean hysterectomy with conservative management and cesarean hysterectomy [4]. In our case, the patient and the spouse agree with the idea of cesarean hysterectomy with placenta left in situ and methotrexate chemotherapy as they are keen on future childbearing. However, given the facts and knowledge about the nature of the disease, preserving fertility for this patient may threaten the patient's life and worsen her morbidity [10], thus bilateral tubal ligation was the best choice of permanent contraception as they already completed their family with 5 living children. In our case, she experienced delayed hemorrhage following conservative management and

methotrexate chemotherapy, which required a secondary hysterectomy. Limited studies demonstrated similar outcomes, which require further research on this matter [11].

CONCLUSION

In conclusion, despite its rarity, urinary bladder hemorrhage due to placenta percreta must be suspected in a pregnant woman presenting with hematuria, previous cesarean deliveries, and has a specific ultrasonography finding especially in primary care setting. Early detection and appropriate management may save the patient's life.

Author contributions: All authors have sufficiently contributed to the study and agreed with the results and conclusions.

Funding: No funding source is reported for this study.

Acknowledgements: The authors would like to thank the patient for her participation.

Ethical statement: Authors stated that ethical approval was not required for the case report. Informed consent was obtained from the patient. Authors further stated that they have not exposed any particulars of the patient that can be identified and ensured that the information was for educational purposes only.

Declaration of interest: No conflict of interest is declared by authors.

Data sharing statement: Data supporting the findings and conclusions are available upon request from the corresponding author.

REFERENCES

1. Silver RM, Barbour KD. Placenta accreta spectrum: Accrete, increta, and percreta. *Obstet Gynecol Clin North Am.* 2015;42(2):381-402. <https://doi.org/10.1016/j.ogc.2015.01.014> PMID:26002174
2. Jauniaux E, Chantraine F, Silver RM, Langhoff-Roos J. FIGO Placenta Accreta Diagnosis and Management Expert Consensus Panel. FIGO consensus guidelines on placenta accreta spectrum disorders: Epidemiology. *Int J Gynecol Obstet.* 2018;140(3):265-73. <https://doi.org/10.1002/ijgo.12407> PMID:29405321
3. Zhao H, Zhao X, Liu C, Tao Y, Zhou Y. Bladder bleeding due to placenta percreta: Report of four cases and management discussion. *Matern-Fetal Med.* 2021;3(4):285-91. <https://doi.org/10.1097/FM9.000000000000120>
4. Tillu N, Savalia A, Patwardhan S, Patil B. Placenta percreta with bladder invasion: The armamentarium available in its management. *Urol Ann.* 2019;11(3):324-7. https://doi.org/10.4103/UA.UA_84_18 PMID:31413516 PMCid:PMC6676855
5. Chavan N, Mirza H, Venkateswaran S, Changede P. Placenta percreta: A rare presentation of obstetric emergency in second trimester. *Int J Reprod Contracept Obstet Gynecol.* 2020;9(10):4295-9. <https://doi.org/10.18203/2320-1770.ijrcog20204327>
6. Wang Y-L, Weng S-S, Huang W-C. First-trimester abortion complicated with placenta accreta: A systematic review. *Taiwan J Obstet Gynecol.* 2019;58(1):10-4. <https://doi.org/10.1016/j.tjog.2018.11.032> PMID:30638461
7. Koukoura O, Lialios G, Garas A, et al. Macroscopic hematuria due to placenta percreta: Report of two cases and short review. *Case Rep Obstet Gynecol.* 2017;2017:9863792. <https://doi.org/10.1155/2017/9863792> PMID:28698813 PMCid:PMC5494060
8. De Gennaro E, Orsaria M, Driul L. Placenta accreta in the first trimester: A case report. *Clin Case Rep.* 2021;9(9):e04615. <https://doi.org/10.1002/ccr3.4615> PMID:34512978 PMCid:PMC8423128
9. Sahin E, Madendag Y, Eraslan Sahin M, Col Madendag I, Kirlangic MM. Evaluation of the diagnostic accuracy of a combination of first-trimester ultrasound and maternal demographic characteristics for detecting abnormally invasive placenta. *Eur J Obstet Gynecol Reprod Biol.* 2022;268:1-6. <https://doi.org/10.1016/j.ejogrb.2021.11.006> PMID:34788719
10. Atallah D, Abou Zeid H, Moubarak M, Moussa M, Nassif N, Jebara V. "You only live twice": Multidisciplinary management of catastrophic case in placenta Accreta Spectrum-a case report. *BMC Pregnancy Childbirth.* 2020;20(1):135. <https://doi.org/10.1186/s12884-020-2817-2> PMID:32111175 PMCid:PMC7048027
11. Ou J, Peng P, Teng L, Li C, Liu X. Management of patients with placenta accreta spectrum disorders who underwent pregnancy terminations in the second trimester: A retrospective study. *Eur J Obstet Gynecol Reprod Biol.* 2019;242(11):109-113. <https://doi.org/10.1016/j.ejogrb.2019.09.014> PMID:31580962