











Patterns of superficial antecubital veins observed by near-infrared light technique: A community-based study

Sanket D Hiware¹ , Suliman K Abuhaimeed² , Khalid S Alshahrani² , Nafie A Alrubaish² ,
Abdulrahman I Alsahan¹ , Abdullah H Alameer² , Kamaluddin Motawei¹ , Syed Rehan Hafiz Daimi¹ ,
Rashid A Aldahhan¹ , Mohammed T Al-Hariri^{3*} 

¹Department of Anatomy, College of Medicine, Imam Abdulrahman Bin Faisal University, P.O. Box 2114, Dammam 31451, SAUDI ARABIA

²College of Medicine, Imam Abdulrahman Bin Faisal University, P.O. Box 2114, Dammam 31451, SAUDI ARABIA

³Department of Physiology, College of Medicine, Imam Abdulrahman Bin Faisal University, P.O. Box 2114, Dammam 31451, SAUDI ARABIA

*Corresponding Author: mtalhariri@iau.edu.sa

Citation: Hiware SD, Abuhaimeed SK, Alshahrani KS, Alrubaish NA, Alsahan AL, Alameer AH, Motawei K, Hafiz Daimi SR, Aldahhan R, Al-Hariri MT. Patterns of superficial antecubital veins observed by near-infrared light technique: A community-based study. *Electron J Gen Med.* 2023;20(1):em441. <https://doi.org/10.29333/ejgm/12737>

ARTICLE INFO

Received: 06 Oct. 2022

Accepted: 04 Dec. 2022

ABSTRACT

Background: The area of the cubital fossa contains the main superficial veins, including the basilic, cephalic, median cubital, and median antebrachial veins, and their innominate small tributaries. For this reason, it is the area most preferred by medical practitioners to access the circulatory system for various clinical applications.

Objective: The aim of this study was to address the prevalence of different types of antecubital fossa superficial vein patterns observable among Saudi subjects by applying a tourniquet and using a VeinViewer®.

Materials and methods: Over the period from September 2020 to April 2021, a cross-sectional study was carried out in the Eastern Province of Saudi Arabia. The 151 study subjects were randomly chosen from the emergency department of King Fahad University Hospital. A total of 302 venous patterns were obtained; 55 were excluded due to the presence of scar tissues over the antecubital fossa, obesity, or thick subcutaneous tissue. Four classes of cubital venous patterns were established according to other studies, and a VeinViewer® and a tourniquet were used to visualize the venous patterns.

Results: Of the 151 people, 21 were female and 130 were male. Among the included 247 venous patterns, the predominant type was type 2 (52.2%), characterized by a branching off the median cubital vein from the cephalic vein and an upward progression to join the basilic vein.

Conclusion: Type 2 appears to be the dominant pattern, with no significant relation to the origins of the parents, in the Saudi population. Gender does not influence the venous patterns. Further studies are needed outside the restrictions of the COVID-19 pandemic to obtain a larger sample.

Keywords: venous patterns, anatomical variations, antecubital fossa, vein illuminator

INTRODUCTION

The cubital fossa is the most preferred site for common medical procedures that are critical in medical practice, such as venipuncture, infusion, or transfusion due to accessibility and easy availability of superficial veins in the region [1-4]. The area of the cubital fossa contains the main superficial veins, including the basilic, cephalic, median cubital, and median antebrachial veins, as well as their innominate small tributaries. As these veins are superficial and not paired with arteries, they provide easy and safe access to obtain blood and are clear to view and identify [5, 6]. Knowledge of the patterns of the superficial veins in the cubital fossa and their surrounding structures (including the underlying major arteries, major nerves, and accompanying cutaneous nerves) is therefore important for daily safe clinical and paraclinical practice [1-4, 7]. However, the anatomical locations and relations of these superficial veins are highly variable. Poor

understanding of their anatomical variations can consequently lead to iatrogenic complications, such as hematoma, bruising, and nerve injury, during different medical and paramedical procedures [8, 9].

Literature revealed up to eight types and subtypes of anatomical variations of the superficial veins in the cubital fossa. However, many of these studies were cadaveric dissections with limited numbers of subjects [10]. Due to recent advances in imaging techniques, the superficial veins can now be studied by contrast venography, ultrasonography, magnetic resonance imaging, computed tomography imaging, and vein viewer devices that use infrared light to highlight the veins on the skin surface [11-13]. A previous study reported the use of a non-invasive vein illuminator and infrared reflection to visualize veins and assess their patterns [14]. This device has optimized the peripheral venipuncture procedure and increased the success rate for the location of the vein in first attempt compared to the traditional way [15-17]. The

VeinViewer® (4.0 vision 2 by Christie) is one of this type of device and is commercially available in Saudi Arabia.

Nevertheless, the variations in the superficial venous patterns that can be observed by a vein illuminator device are less well understood than the patterns derived from cadaveric or angiographic studies. Hence, prior knowledge of the anatomical variations that are revealed by this type of device is an essential prerequisite for examining an individual using this device. Some studies have investigated the anatomical variations of the superficial cubital veins in particular communities [7, 18-22], but the cubital venous patterns in the Saudi population have not yet been identified. The aim of the present single-center study was to use an infrared vein finder to establish the prevalence of different variations of cubital superficial veins among Saudi individuals. The ultimate goal was to assist healthcare providers in performing safe venipuncture or other medical procedures that require access to the blood via the superficial cubital veins.

MATERIALS AND METHODS

Study Design and Participants

Over the period from September 2020 to April 2021, a convenience sample of a cross-section study was carried out in the Eastern Province of Saudi Arabia. The independent variables in this study were gender and geographic origin, whereas the dependent variable was the pattern of superficial veins in the cubital fossa. The controlled variables were pathologically thick subcutaneous tissue, scars, surgical procedures on the forearm, radiation to the skin, and multiple venipuncture procedures in the cubital fossa area. The in-flow of people in hospitals was less and we also faced as issue to get more female volunteers due to cultural issue as all our data collectors were male students. Hence, we have tried our best to get considerable sample size of female volunteers. We have documented the venous patterns of 131 males and 20 females.

Inclusion and Exclusion Criteria

Volunteers above 18 years visiting the King Fahd University Hospital and Family and Community Medicine Center and volunteers of Saudi origin whose parents are Saudi nationals were included in the study. The study has excluded volunteers with the age above 65 years, significantly missing hospital data, thick subcutaneous tissue, wounds in the region of the cubital fossa, history of operations, venipuncture, fractures, radiotherapy in the region of cubital fossa and highly obese patients in whom the superficial veins in the cubital fossa are not clearly visible

Data Collection Tools

A tourniquet was used to restrict the blood flow in the superficial veins so that they become more prominent for visibility. The VeinViewer® was then used to highlight these superficial veins. It is a hand-held device, which uses the near-infrared technique. It works on the principle of difference in absorption of light by the blood in superficial veins and their surrounding tissue, which ultimately highlights these blood vessels more as compared to the other tissue. It is a calibration tool with high accuracy and was calibrated once a day before starting the checkup of volunteers for research related data collection.

Data Collection Procedures

Participants were selected on the basis of multi-purpose sampling method from the visitors, staff, and patients of King Fahad University Hospital in Al-Khobar, Saudi Arabia. All participants were informed about the relevant details of the research study, and all provided written consent. All limbs were evaluated by placing a tourniquet 10 cm proximal to the crease at the cubital fossa to make the veins prominent, aided by making active movements distal to the elbow joint. The VeinViewer® was then focused on the area of the cubital fossa up to the tourniquet. Different venous patterns were captured with a digital camera. The observed venous patterns were then drawn manually on the consent forms by the data collectors. Classification of the cubital venous patterns was done according to [3, 14], as follows:

1. Type 1: The “Y” or “M” pattern, known as the classical pattern, where the median antebrachial vein is dominant. It joins the basilic vein (BV) and the cephalic vein (CV) by its two terminal branches in the cubital fossa.
2. Type 2: This pattern is also known as the (N) or (H) pattern. It is characterized by a poorly developed median antebrachial vein ending to median cubital vein, which connects the cephalic and basilic veins in the cubital region.
3. Type 3: In this pattern, the development of the brachial cephalic vein is poor, or the vein is missing, and the median antebrachial vein or median cubital vein drains into the basilic vein.
4. Type 4: In this pattern, the communicating branch between the BV and CV is absent.

Data Analysis

IBM statistical package for the social sciences (SPSS) version 23 was used to analyze the data. Descriptive data are presented as frequencies (percentages) for discrete variables and as means (standard deviation [SD]) or medians (interquartile range [IQR]) for continuous variables. The differences between groups of patients were assessed using Student's t-test for continuous variables as appropriate and the χ^2 -test or Fisher's exact test for discrete variables.

RESULTS

A total of 302 cubital fossae of both upper limbs were visualizing for venous pattern. Of the total of 302 upper limb patterns, 55 were excluded from the study based on exclusion criteria, such as the presence of scar tissues over the antecubital fossa, obesity, or thick subcutaneous tissue (**Figure 1**).

151 individuals (131 males and 20 females) volunteered for our study as subjects (**Table 1**).

All the subjects were local Saudi citizens between 18 to 65 years of age. Most of our subjects were from the eastern region of Saudi Arabia (43.7%), followed by the southern region (26.5%), central region (13.2%), western region (9.3%), and northern region (7.3%) (**Table 1**).

Ethnicity was noted by asking the volunteers about the origins of both parents. Of the 151 participants, 145 claimed

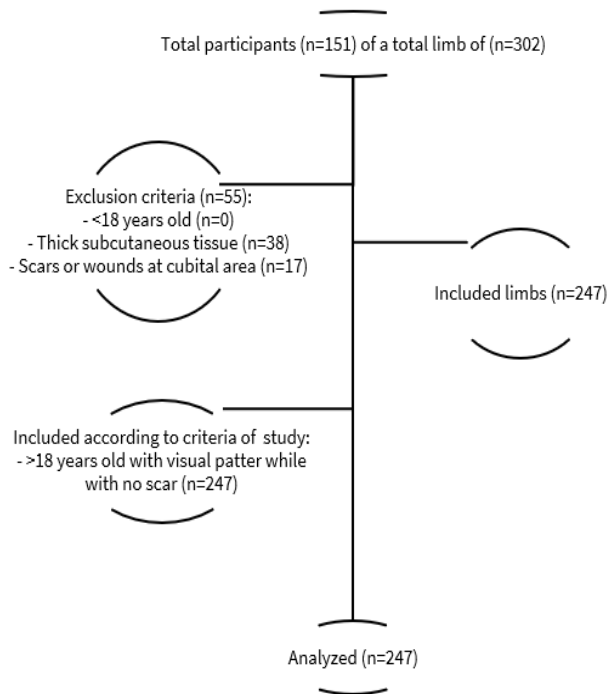


Figure 1. Illustration of the participants flow-chart (Source: Authors' own elaboration)

Table 1. Classification of subjects according to the studied dependent variables

Variables	Frequency	Percentage
Gender		
Female	21	13.9
Male	130	86.1
Geographical descent (within KSA)		
Central region	20	13.2
Eastern region	66	43.7
North region	11	7.3
South region	40	26.5
Western region	14	9.3
Ethnicity: Are both parents Saudi?		
Yes	145	96.0
No	6	4.0
Age groups		
18-25	101	66.9
26-35	33	21.9
36-45	8	5.3
46-55	3	2.0
56-65	6	4.0
Total	151	100.0

that both parents were Saudi, while the remaining six had one Saudi parent (**Table 1**).

Most of our participants fell within the 18-25 year age group (66.9%), followed by 21.9% in the 26-35 year age group; the fewest participants (2%) were from the age group between 46 and 55 years (**Table 1**).

Visualization of the antecubital superficial vein patterns using VeinViewer® revealed four pattern types (**Figure 2** and **Figure 3**). Among the 247 included upper limbs, the dominant venous pattern was type 2, detected in 129 (52.2%) upper limbs, followed by type 1 in 80 upper limbs (32.3%), type 3 in 21 upper limbs (8.5%), and type 4 in 16 upper limbs (6.4%).

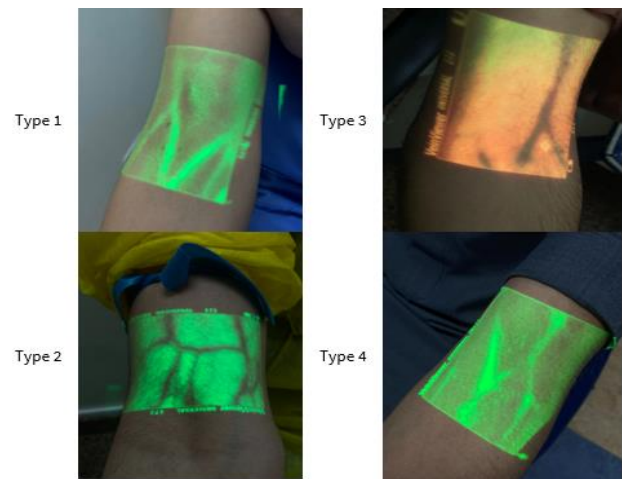


Figure 2. Photographs of 4 main patterns of superficial veins in cubital fossa after visualized by Vein Viewer®

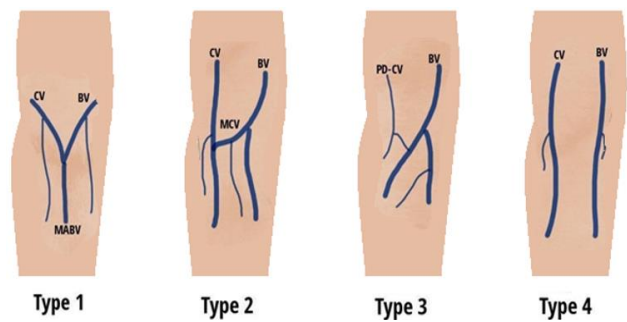


Figure 3. Illustration of the common patterns of the superficial veins in the cubital fossa (BV: Basilic vein; CV: Cephalic vein; MABV: Median antebrachial vein; MCV: Median cubital vein; & PD-CV: Poorly developed cephalic vein) [5, 14]

Only one unusual venous pattern was found in the right upper limb of a patient, whose left upper limb had a regular pattern (**Figure 2** and **Table 2**).

Comparison of the left and the right upper limbs in relation to gender revealed that the left limb had an equal distribution of type 1 (38.09%) and type 2 (38.09%) patterns in females, whereas males showed a predominance of type 2 (50%). The right limb showed a predominance of the type 2 pattern in both males (58.65%) and females (45%) (**Table 3**).

The correlation between gender and the different venous patterns on the left and right upper limbs was not statistically significant ($p>0.05$).

Among the participants who had one non-Saudi parent, type 2 was the only observed venous pattern in the right upper limbs, while the left upper limbs showed type 2 (80%) and type 1 (20%) patterns. Type 2 was the most common pattern on the left (46.6%) and right (55%) upper limbs in participants who had two Saudi parents. However, no association statistically significant association was found between the venous patterns and the parents' origin ($p>0.05$).

DISCUSSION

The present study is the first to report the presence of four types of superficial cubital venous patterns in the Saudi population. The type 2 pattern (characterized by a poorly developed median antebrachial vein that drains into the

Table 2. Limb-wise frequencies of different pattern-types of cubital superficial veins among studied Saudi population group

Venous pattern	Limb side					
	Right limb		Left limb		Both right & left limbs	
	Frequency	Percent	Frequency	Percent	Frequency	Percent
Type 1	35	28.2	45	36.6	80	32.4
Type 2	70	56.5	59	48.0	129	52.2
Type 3	10	8.1	11	8.9	21	8.5
Type 4	8	6.5	8	6.5	16	6.5
Type 5	1	0.8	0	0.0	1	0.4
Total	124	100.0	123	100.0	247	100.0

Table 3. Gender and limb side effects on frequencies of different pattern-types of cubital superficial veins among studied Saudis population group

Venous pattern	Left limb				Right limb			
	Females		Males		Females		Males	
	Frequency	Percent	Frequency	Percent	Frequency	Percent	Frequency	Percent
Type 1	8	38.09	37	36.28	6	30.00	29	27.88
Type 2	8	38.09	51	50.00	9	45.00	61	58.65
Type 3	3	14.28	8	7.84	3	15.00	7	6.73
Type 4	2	9.52	6	5.88	1	5.00	7	6.73
Type 5	0	0.00	0	0.00	1	5.00	0	0.00
Total	21	100.00	102	100.00	20	100.00	104	100.00

median cubital vein, which connects the cephalic and basilic veins in the cubital region) was the most common type in both males and females in the current study, in agreement with the findings of [7] for Jordanian was also reported that type 2 pattern was the most common pattern in males (49.3%), whereas type 1 (median antebrachial vein dominates and joins BV and CV by its two terminal branches in cubital fossa) was the most common type in females (56.0%) [14]. A comprehensive review concluded that type 2 is the most common, followed by type 1, in accordance with our findings [10].

Type 3 ranked third in distribution in our sample, followed by type 4. Type 3 is characterized by a rudimentary or poorly developed CV, and the median antebrachial vein or median cubital vein drains into the BV. By contrast, it was reported that type 3 is the most common pattern among Colombian women and type 1 among Colombian men [18]. These discrepancies highlight the possible effect of ethnicity and gender on the patterns of cubital superficial veins. However, our findings do not support this hypothesis, as we found no association between the venous patterns and parental origins or between the patterns and gender. The limb side also did not appear to affect the cubital venous pattern in the two sexes. Many other studies have also reported lower frequencies for both type 3 and type 4 than for type 1 and type 2 [17-20].

Studies on cubital superficial venous pattern are crucial for alerting medical practitioners to variations in these patterns and their predominance, as this knowledge will help improve venipuncture practice. As a research tool, topographical dissection of superficial cubital veins in cadavers would be more informative than the vein-viewer technique. Nevertheless, conducting a study on a larger population would still be useful and feasible with the VeinViewer®, as it represents what clinicians face in actual practice. Infrared vein viewing would also provide a strong basis for data collection and classification. Medical procedures like venipuncture have a high success rate when an intravenous illuminator is used, compared to the traditional vein engorgement method using a tourniquet [12-14]. These findings ensure that the classification of venous patterns in the current study is reliable.

The available literature has reported four major superficial cubital venous patterns in different populations [8, 16-20], whereas the majority of recognized anatomy textbooks address only two types [1-3]. The reported prevalence rates of these four types show interesting dispersions in different populations, at 0.7-54% for type 1, 9-98% for type 2, 1.1-37% for type 3, and 1.6-32% for type 4 [10].

CONCLUSION

Type 2 appeared to be the dominant cubital venous pattern in our study population, and neither gender nor parental origin showed a significant relationship with the venous pattern. Larger studies should be conducted in the non-COVID-19 era to confirm the dominant patterns in the Saudi population.

Application

The results of this study can aid educational and medical practice personnel in guiding trainees and students to become more familiarized with the pattern of veins that are abundant in our region. This will increase the success rate of the first venipuncture attempt, as well as providing proper knowledge about anatomical characteristics in our region in cases needing emergency intervention.

Limitations and Recommendations

Due to the COVID-19 circumstances and safety regulations related to it, the target sample had to be reduced, and this might have affected the results of the study. The female sample size was smaller than the male sample size due to a lack of female volunteers in the emergency department when the samples were collected. The study was done using only the VeinViewer®; hence, the findings will be useful for limited superficial procedures. More anatomical variations of superficial veins should be studied by a cadaveric study or venography on a larger sample size and including participants from different regions of Saudi Arabia. Females should be encouraged to volunteer for the study. A comparative study can also be done to determine the type of variations observable by venography and by the VeinViewer® (infrared

reflection) method in the same volunteers. Vascularization may vary in different age groups. Age-grouping could not be done in our study and hence we could not report the incidence of different patterns of superficial veins in different age groups.

Author contributions: SDH & RAA: conceived and designed the project; SDH, SKA, KSA, NAA, AIA, & AHA: analyzed the data; SDH, KM, SRHD, RAA, & MTA: critical review of manuscript; SKA, KSA, NAA, AIA, & AHA: data collection; & SDH, KM, SRHD, RAA, & MTA: critical discussion of data. All authors have agreed with the results and conclusions.

Funding: No funding source is reported for this study.

Ethical statement: Ethical approval was obtained from the Institutional Review Board of Imam Abdulrahman Bin Faisal University, Saudi Arabia (IRB-UGS-2020-01-327).

Declaration of interest: No conflict of interest is declared by authors.

Data sharing statement: The data used to support the findings of this study are included within the article.

REFERENCES

- Moore KL, Dalley AF. Clinically oriented anatomy. Baltimore, MD: Lippincott Williams & Wilkins; 2006.
- Kiray A, Ergur I, Tayefi H, Bagriyanik HA, Bacakoglu AK. Anatomical evaluation of the superficial veins of the upper extremity as graft donor source in microvascular reconstructions: A cadaveric study. *Acta Orthop Traumatol Turc.* 2013;47(6):405-10. <https://doi.org/10.3944/aott.2013.3194> PMID:24509220
- Yamada K, Yamada K, Katsuda I, Hida T. Cubital fossa venipuncture sites based on anatomical variations and relationships of cutaneous veins and nerves. *Clin Anat* 2008;21(4):307-13. <https://doi.org/10.1002/ca.20622> PMID:18428997
- Mikuni Y, Chiba S, Tonosaki Y. Topographical anatomy of superficial veins, cutaneous nerves, and arteries at venipuncture sites in the cubital fossa. *Anat Sci Int.* 2013;88:46-57. <https://doi.org/10.1007/s12565-012-0160-z> PMID:23131916
- Standring S. Gray's anatomy. Edinburgh: Elsevier Churchill Livingstone; 2016.
- Snell RS. Clinical anatomy by regions. Baltimore, MD: Lippincott Williams & Wilkins; 2012.
- AlBustami F, Altarawneh I, Rababah E. Pattern of superficial venous arrangement in the cubital fossa of adult Jordanians. *J Med J.* 2014;48(4):269-74. <https://doi.org/10.12816/0025077>
- Newman BH, Pichette S, Pichette D, Dzaka E. Adverse effects in blood donors after whole-blood donation: A study of 1000 blood donors interviewed 3 weeks after whole-blood donation. *Transfusion.* 2003;43(5):598-603. <https://doi.org/10.1046/j.1537-2995.2003.00368.x> PMID:12702180
- Newman BH, Waxman DA. Blood donation-related neurologic needle injury: Evaluation of 2 years' worth of data from a large blood center. *Transfusion.* 1996;36(3):213-5. <https://doi.org/10.1046/j.1537-2995.1996.36396182137.x> PMID:8604504
- Yamine K, Erić M. Patterns of the superficial veins of the cubital fossa: A meta-analysis. *Phlebology.* 2017;32(6):403-14. <https://doi.org/10.1177/0268355516655670> PMID:27343223
- Goodacre S, Sampson F, Thomas S, van Beek E, Sutton A. Systematic review and meta-analysis of the diagnostic accuracy of ultrasonography for deep vein thrombosis. *BMC Med Imaging.* 2005;5:6. <https://doi.org/10.1186/1471-2342-5-6> PMID:16202135 PMCid:PMC1262723
- Arnoldussen CW, de Graaf R, Wittens CH, de Haan MW. Value of magnetic resonance venography and computed tomographic venography in lower extremity chronic venous disease. *Phlebology.* 2013;28(Suppl 1):169-75. <https://doi.org/10.1177/0268355513477785> PMID:23482555
- Pan CT, Francisco MD, Yen CK, Wang SY, Shiue YL. Vein pattern locating technology for cannulation: A review of the low-cost vein finder prototypes utilizing near infrared (NIR) light to improve peripheral subcutaneous vein selection for phlebotomy. *Sensors (Basel).* 2019;19(16):3573. <https://doi.org/10.3390/s19163573> PMID:31426370 PMCid:PMC6719195
- Lee H, Lee SH, Kim SJ, Choi WI, Lee JH, Choi IJ. Variations of the cubital superficial vein investigated by using the intravenous illuminator. *Anat Cell Biol.* 2015;48(1):62-5. <https://doi.org/10.5115/acb.2015.48.1.62> PMID:25806123 PMCid:PMC4371182
- Hess HA. A biomedical device to improve pediatric vascular access success. *Pediatr Nurs.* 2010;36(5):259-63.
- Kaddoum RN, Anghelescu DL, Parish ME, et al. A randomized controlled trial comparing the AccuVein AV300 device to standard insertion technique for intravenous cannulation of anesthetized children. *Paediatr Anaesth.* 2012;22(9):884-9. <https://doi.org/10.1111/j.1460-9592.2012.03896.x> PMID:22694242
- Kim MJ, Park JM, Rhee N, et al. Efficacy of VeinViewer in pediatric peripheral intravenous access: A randomized controlled trial. *Eur J Pediatr.* 2012;171(7):1121-5. <https://doi.org/10.1007/s00431-012-1713-9> PMID:22415409
- Corzo Gomez EG, Gomez Diaz OL, Nino ME, Ramirez Vargas LM, Zarate Sierra LM. Distribution pattern of the veins of the cubital fossa in a sample of people born in the Department of Santander, Colombia. *Int J Morphol.* 2014;32(1):221-6. <https://doi.org/10.4067/S0717-950220140001000037>
- Gomez Diaz OL, Corzo Gomez EG, Rey Triana RJ, Nino ME, Pedraza L. Distribution pattern of the veins of the cubital fossa in a sample of people born in Bucaramanga, Colombia. *Int J Morphol.* 2010;28(4):1011-8. <https://doi.org/10.4067/S0717-95022010000400005>
- Halim A, Abdi HM. Superficial venous patterns in the cubital region of Indians. *Anat Rec.* 1974;178(3):631-5. <https://doi.org/10.1002/ar.1091780310>
- Hamzah AA, Ramasamy S, Adnan AS, Khan AH. Pattern of superficial venous of the cubital fossa among volunteers in a tertiary hospital. *Trop Med Surg.* 2014;2(2):164. <https://doi.org/10.4172/2329-9088.1000164>
- Singh JD. Patterns of superficial veins of the cubital fossa in Nigerian subjects. *Acta Anat (Basel).* 1982;112(3):217-9. <https://doi.org/10.1159/000145513> PMID:7102247