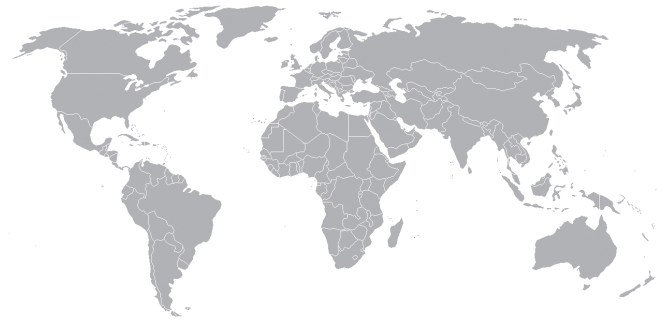

Prevalence of Fibularis Tertius Muscle in Southeastern Indian Population: a Surface Anatomical Study

Bhagath Kumar Potu¹, Vinod Kumar², Sucharitha Annam², Abdel Halim Salem¹, Marwan Abu-Hijleh³

ABSTRACT

Background: Fibularis tertius (FT) is a variant muscle of the anterior compartment of leg which involves in dorsiflexion and eversion of the foot. Literature shows that the reported prevalence of FT ranges from 49-100%. This study investigates the prevalence of FT in South-eastren population of India using surface anatomy techniques in living subjects and comparing it with the studies available in the literature.

Material and methods: Study included the evaluation of 195 subjects from Year 1 & 2 medical students (102 females and 93 males) which correspond to 390 feet in total. The average age of the sample was 17.9 years, with lower and upper limits of 17 and 20 years, respectively. The presence of FT was identified with a standard palpation technique that determines the presence of muscle on the basis of the progression tests called F1, F2, and F3.

Results: The total FT prevalence was found to be 52% of the sample. On the right foot, FT was found to be 26.5% in males and 24.4% in females and on the left foot, it was 26.5% in males and 25.5% in females. FT palpation criterion showed 0 (zero) cases for F1, 31 cases for F2 and 172 cases for F3.

Conclusion: This surface anatomical study reports for the first time the FT prevalence in South-eastren population of India. Further studies on prevalence of FT are needed to understand its role in biomechanics and reconstructive surgeries of the ankle and foot.

Keywords: Fibularis Tertirus muscle, Prevalence, South-eastern India, Surface anatomy

INTRODUCTION

The fibularis tertius muscle (FTM) conventionally known as peronues tertius is a muscle of the anterior compartment of leg region. The classical anatomy text books described it as a fifth tendon of the extensor digitorum longus muscle (EDLM) (1, 2). A few morphologico -functional studies conducted in the past have identified FTM arising from the lower third of the lateral surface of fibula (Figure 1) and the adjoining anterior aspect of the interosseous membrane and inserting into the base of the fifth metatarsal (2, 3, 4, 5). Variable insertion of the FTM was reported such as in the shaft of the fifth metatarsal, fourth interosseous space, the shaft of the fourth metatarsal (5), and at the base of the fourth metatarsal (6). Its strategic location in anterior leg compartment is known to cause dorsiflexion of the foot along with other anterior compartmental leg muscles. It also acts with fibularis longus and brevis muscles as a strong evorter of the foot and prevents hyper-inversion. It has been reported that the FTM helps in transmitting body weight to the lateral longitudinal arch during the stance phase of walking and in the contribution to the swing phase of bipedal mode of locomotion (7, 8).

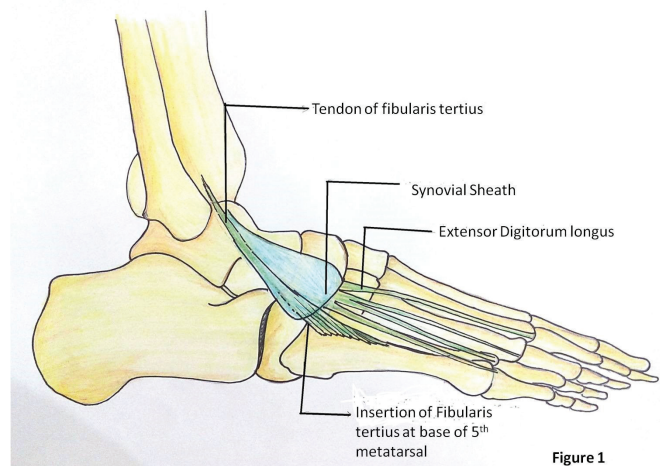


Figure 1: Schematic diagram showing the origin, course and insertion of the fibularis tertius muscle.

Department of Anatomy, College of Medicine & Medical Sciences, Arabian Gulf University¹, Manama, Kingdom of Bahrain.
Department of Anatomy, Saphthagiri Institute of Medical Sciences & Research Center, Bangalore, India. Department of Anatomy, College of Medicine, Qatar University³, Qatar.

Received: 30.11.2015, Accepted: 07.01. 2016

Correspondence: Abdel Halim Salem
Department of Anatomy,
College of Medicine & Medical Sciences,
Arabian Gulf University, P.O. Box 22979,
Manama, Kingdom of Bahrain

E-mail: abdelhalim@agu.edu.bh

Despite of its described variant anatomy, its prevalence is not yet studied in many populations across the world. Although, several studies reported its prevalence from 49-100% in cadaveric dissections and surface anatomical evaluations of different populations (4, 5, 9-16), there is no surface anatomical study conducted on Indian population till date. The knowledge of the surface evaluation of FTM may be very important to clinicians, foot surgeons and for successful tissue grafting procedures. This prompted us to assess the prevalence of FTM in south-eastern population of the India through a surface anatomical evaluation of the foot in young adult medical students using a standardized protocol adopted from Ramirez et al. (10).

MATERIALS AND METHODS

Sample size and its source

This study was conducted at Sapthagiri Institute of Medical Sciences & Research Centre, Bengaluru, Karnataka State, Republic of India and included the evaluation of 195 subjects from Year 1 & 2 medical students (102 females and 93 males) which correspond to 390 feet in total. The average age of the sample was 17.9 ± 0.66 years and the study was conducted over the period of four months between the months of August and December, 2014.

Data Collection

A standard tabulation was made including age, gender, presence and absence of FTM on each limb (left and right). If FTM present, the degree to which it can be palpated and also the past record of any ankle injuries/sprains and congenital anomalies in both limbs were recorded.

Surface evaluatory procedure of FT tendon

To identify the FTM accurately, we have done a series of pilot studies using an evaluation techniques described by Tixa (17), Kendal et al. (18) and Ashaolu et al. (9). Each foot of the subjects was examined for 90 seconds by two evaluators. In this study, the subjects were seated and their knees were flexed at approximately 100° . The evaluators were squatting in front of the subjects fixing their legs on the ankle joint to palpate FT tendon (Figure 2). Palpation of FT was carried out on the following criteria.

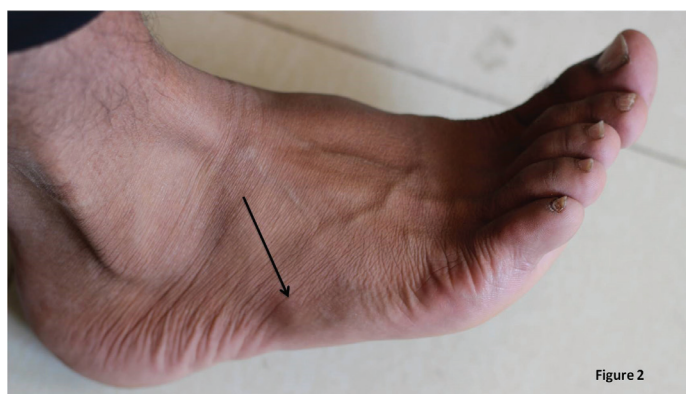


Figure 2: Showing the surface evaluation of fibularis tertius muscle in living subject (Arrow showing the muscle)

FT palpation criteria

Criteria 1: Palpate the FT tendon on its way to the fifth metatarsal without any muscular tension. If any tendon palpated in this criteria, we named it as F1. If no tendon was palpated, we moved to criteria 2.

Criteria 2: The subjects were asked to dorsiflex and evert the foot. If FT tendon was identified on the same course of criteria 1, we named it as F2. If nothing was seen or felt here, we moved to criteria 3.

Criteria 3: This included the same procedure of criteria 2, but manual resistance was applied to the lateral border of the foot at the fifth metatarsals; if the tendon is visualized or palpated, we named it as F3.

RESULTS

Out of the total of 390 legs we studied, FTM was found present on 100 right legs and 103 left legs making a total of 203 occurrences which equals to 52.05% of the sample population studied (Table 1). From our study, we found that on the right foot, FTM presence was more in males (26.6 %) than females (24.6%), and on the left foot, FTM presence was 27.2% in males and 25.6% in females. Both male and female prevalence's on right and left side were almost equal (Table 2). Percentage distribution of FTM studied among 195 subjects revealed that the FTM was present only on right side in 10.25% (20 cases); on left side was 11.79% (23 cases); and on both sides was 41% (80 cases). FTM was absent on both sides in 36.9% (72 cases) (Table 3).

Table 1: Prevalence of FTM on both sides of 195 samples studied

FTM on right (n=195)		FTM on left (n=195)	
Present n= 100 51%	Absent n=95 49%	Present n= 103 52.82%	Absent n=92 47.17%

Table 2: Showing the prevalence of FTM as per gender

	Right side (195)		Left side (195)	
	Male	Female	Male	Female
Number	52	48	53	50
Percentage	26.6%	24.6%	27.2%	25.6%

Table 3: Showing the percentage distribution of FTM studied among 195 subjects

FTM present only on right side	FTM present only on left side	FTM present on both sides	FTM absent on both sides
20 cases 10.25%	23 cases 11.79%	80 cases 41.03%	72cases 36.92%

The total numbers of past ankle injuries observed in 390 limbs of the 195 subject samples studied were only 11(eleven). Six ankle injuries were recorded on the right foot and five were recorded on the left foot (Table 4). However, throughout the procedures of palpation, 0 (zero) cases were recorded with the F1, 31 cases were recorded with the F2 and 172 cases with the F3 (Table 5). Our findings were also compared with the FTM prevalence's available in the literature (Table 6).

Table 4: Showing the FTM occurrence in ankle injuries of the subjects studied

	No of ankle injuries occurred	% of ankle injuries occurred	FTM occurrence no & %
Right side	6	54.5%	5 (83.3%)
Left side	5	45.5%	3 (60%)

Total number of ankle injuries occurred = 11

Table 5: Prevalence studies of FTM reported in the literature

Population	Author	Year	Sample	Type of Study	FTM prevalence %
Austria	Krammer et al. (16)	1979	169	Cadaveric dissection	93
France	Bertelli & Khoury (15)	1991	44	Cadaveric dissection	90
Cambridge, UK	Stevens et al.(14)	1993	40	Cadaveric dissection	95
La Paz, Bolivia	Larico & Jordan (13)	2005	46	Cadaveric dissection	100
Swansea, UK	Rourke et al. (5)	2005	41	Cadaveric dissection	94
Brazil	Marin et al. (12)	2006	32	Cadaveric dissection	94
Poland	Domagala et al.(11)	2006	193	Cadaveric dissection	83
Maharashtra, India	Joshi et al. (4)	2006	110	Cadaveric dissection	90
Belgium	Witvrouw et al. (8)	2006	200	Surface anatomy	82
Talca, Chile	Ramirez et al.(10)	2010	168	Surface anatomy	49
Iwo, Nigeria	Ashaolu et al.(9)	2013	200	Surface anatomy	63
Karnataka, India	Present study	2014	390	Surface anatomy	52

DISCUSSION

This study was conducted to estimate the prevalence of fibularis tertius muscle in the population of the southern-eastern Karnataka State, India. We are reporting 52% prevalence of the muscle in the studied population. A study conducted on cadavers over the period of 5 years by Joshi et al. (4) in 2006, reported the prevalence of FTM from the region of Maharashtra, India to be 90%. Our findings are far less from what they have reported which could be attributed to differences in sample size and study design. To the best of our knowledge, our work is the first one to be reported from Indian population using the surface anatomy examination of the prevalence of FTM. Our findings reveal that the FTM prevalence is slightly less on the right limb (51.28%) (Table 1).

Of 195 subjects we examined, 10.2% had FTM present only on right side, 11.7% FTM present only on left side, 41.2% FTM present on both sides and 36.9% having FTM absent on both sides (Table 3). These findings suggest that only 41.2% of FTM has reached success in evolution by showing its simultaneous bilateral occurrence as also observed in the study by Ashaolu et al. (9). In relation with gender, our study clearly showed the greater prevalence of FTM in males than in females (Table 2). Which is close to the prevalence's reported by Ramirez et al. (10) and Witvrouw et al. (8) in Chilean and Belgian populations, respectively. In our study, most of the cases were found to belong to the F3 type category (83 right, 89 left). F2 cases were found to be 17 right and 14 left, while F1 cases reported were absolutely nil (Table 5). Jungers et al. (19) in their study postulated that the morphological features of FTM are always related to the development and evolution of the extensor digitorum longus muscle. The variant degrees of embryological separation of fibularis tertius from the extensor digitorum longus muscle until the final insertion in the lateral border of the foot may explain the variant palpated cases of the FTM observed in our study. Many authors have reported the variant anatomy

of FTM (20-23). A unique variation of the FTM was found in a 75-year-old male cadaver originating from the extensor hallucis longus (20). Few authors have reported its absence (7, 21, 22), while one case of FTM showing three tendinous insertions was reported (23).

The FTM absentia is reported to be more common in the apes and monkeys but its occurrence increases in the gorillas (24). This variability of the muscle reported suggests that the FTM absentia may be a primitive condition for anthropoids (19). As evolution advanced, the frequency of the FTM has increased and perhaps this is the reason why it might be found more in human population (24).

A study by Morimoto et al. (25) suggests that the exercising of FTM is genetically controlled by a single pair of autosomal genes with variable expression and/or reduced dominance. Domagala et al. (11) reported that the relatively high presence of FTM in adolescents and adults and its lower incidence in fetuses could be due to a fact that the development of the muscle is directly depending on the physical activity happening along with the age. This may explain, the fact why FTM prevalence is more (81.5%) in young athletes sample of Witvrouw et al.(8) when compared to the prevalence of our study (52%) and the study by Ramirez et al.(10) (49.11%) (Table 6), both studies have included the individuals without significant physical activity and therefore with reduced muscle development.

We also have noticed that the prevalence rate of the FTM is lower in the reported surface anatomical studies (49-82%) (8-10) compared to percentages reported from cadaveric dissection studies (83-100%) (4, 5, 11-16). Despite of various reports on FTM in literature, we anatomists firmly believe that the FTM is important both functionally and clinically. Functionally the FTM works with the muscles of anterior compartment of leg during the swing phase of gait to maintain level of foot and prevent the toes from dragging on the ground (19). Clinical reports have been published on usage of FTM flap to fill lower limb soft tissue defects to treat osteomyelitis (26). By filling a dead space with vascularized muscle such as FTM, surgeons can improve the delivery of oxygen, nutrients, and components of the immune system to healing tissues. Its tendon has been also used to correct ligamentous injuries of ankle joint (27) and normalize claw foot deformity by transposition of its insertion (28). FTM tendon graft has been even used to reconstruct a ruptured tibialis anterior tendon (29). Further studies on its prevalence in other populations and its biomechanical role in foot stability could be warranting.

In conclusion, this study could be of relevance for anatomists, physiotherapists, and orthopedic surgeons due to the high variability and significant influence of the FTM on the shape and biomechanics of the foot. We suggest that the traditional description of FTM palpation is no more standard in clinical practice due to its diversified morphology ranging from complete absentia to differential origin and insertions. It is warranted that the analysis of the prevalence of FTM using a gold standard imaging techniques could be essential in the future to deal with its role in biomechanics and surgeries of the foot.

REFERENCES

1. Snell RS. Clinical anatomy for medical students, 7th edition, Lippincott Williams & Wilkins, Baltimore, 2000, 561-562.
2. Williams PL, Bannister LH, Berry MM, Collins P, Dyson M, Dussek JE, Ferguson MWJ. (eds), Gray's Anatomy. The anatomical basis of medicine and surgery, 38th edition, Churchill Livingstone, Edinburgh, 1995, 883.
3. Latarjet M, Ruiz-Liard A. Anatomía Humana. 3rd Ed. Madrid, Panamericana, 1999. Volume 1. p.863.
4. Joshi SD, Joshi SS, Athavale S A. Morphology of peroneus tertius muscle. Clin. Anat 2006;19(7):611-4.
5. Rourke K, Dafydd H, Parkin IG. Fibularis tertius: revisiting the anatomy. Clin. Anat 2007;20(8):946-9.
6. De Los Reyes MR, Vicentin AD, Sosa RA, Leiva F. Insercion distal del Musculo Peroneo Anterior. Universidad nacional del Noreste, Comunicacione scientificasy tecnologicas, 2005. Disponible en: www.unne.edu.ar/Web/cyt/com2005/3-Medicina/M-029.pdf
7. Das S, Haji Suhaimi F, Abd Latiff A, Pa Pa Hlaing K, Abd Ghafar N, Othman F. Absence of the Peroneus tertius muscle: cadaveric study with clinical considerations. Rom J Morphol. Embryol 2009; 50(3):509- 11.
8. Witvrouw E, Vanden K, Marieke T, Huysmans J, Broos E, De Clercq D. The significance of peroneus tertius muscle in ankle injuries. Am. J. Sports Med 2006; 34(7):1159.
9. Ashaolu JO, Olorunyomi OI, Opabunmi OA, Ukwanya VO, Thomas MA. Surface anatomy and prevalence of fibularis tertius muscle in a south-western Nigerian population. Forensic Medicine and Anatomy Research 2013; 25-29.
10. Ramirez D, Gajardo C, Caballero P, Zavando D, Cantin M, Suazo GI. Clinical evaluation of fibularis tertius muscle prevalence. Int J Morph 2003; 28:759-764.
11. Domagala Z, Gworys B, Kreczynska B, Mogbel S. A contribution to the discussion concerning the variability of the third peroneal muscle: an anatomical analysis on the basis of foetal material. Folia Morphol. (Warsz) 2006;65(4):329-36.
12. Marin L, Barbosa FR, Andrade O, Bazanelli AC, Ruiz C R, Pereira LA, Wafaea N. Estudo anatomico do musculo fibular terceiro em humanos. Arq. Méd. ABC 2006; 31(1):23-6.
13. Larico I, Jordan L. Frecuencia del musculo peroneo tertius. Rev.Inv. e Info. Salud 2005; 1(1):29-32.
14. Stevens K, Platt A, Ellis H. A cadaveric study of the peroneus tertius muscle. Clin. Anat 1993;6: 106-110.
15. Bertelli J, Khoury Z. The peroneus tertius island muscle flap. Surg. Radiol. Anat 1991; 13(3):243-4.
16. Krammer EB, Lischka MF, Gruber H. Gross anatomy and evolutionary significance of the human Peroneus III. Anat. Embryol. (Berl) 1979; 155(3):291-302.
17. Tixa S. Atlas de Anatomía Palpatória. 2nd Ed. Barcelona, Masson, 2006.
18. Kendall E, Kendal E, Geise P. Kendall's músculos, pruebas, funciones y dolor postural. 4th Ed. Madrid, Marban, 2000.
19. Jungers WL, Meldrum DJ, Stern JT Jr, The functional and evolutionary significance of the human peroneus tertius muscle, J Hum Evol, 1993; 25:377-386.
20. Yıldız S, Yalcin B. A unique variation of the peroneus tertius muscle. Surg Radiol Anat 2012; 34(7):661-63.
21. Newton BW. Unilateral absence of an extensor digitorum longus muscle and variations of toe tendons. Int J Anat Var 2014; 7: 42-44.
22. Saxena A, Ray B, Mishra S, Perumal V. A cadaveric report of unilateral fibularis tertius in absentia: a clinical perspective. Int J Anat Var 2013;6: 20-21.
23. Sirasanagnadla SR, Bhat KMR, Nayak SB, Shetty PS, Thangarajan R. A rare case of variant morphology of Peroneus tertius muscle. Journal of Clinical and Diagnostic Research 2014; 8(10): AD01 - AD02.
24. Kimura K, Takashashi Y. The peroneus tertius muscle in the crab-eating monkey (*Macaca fascicularis*), Okajimas Folia Anat Jpn 1985;62(3-4):173-185.
25. Morimoto I, Yasaki H, Katagiri S. The incidence and familial nature of genesis of the peroneus tertius muscle. Med. J. Shinshu Univ 1959; 4:259-68.
26. Arnold PG, Yugueros P, Hanssen AD, Muscle flaps in osteomyelitis of the lower extremity: a 20-year account, Plast Reconstr Surg 1999;104(1):107-110.
27. Sammarco GJ, Henning C. Peroneus tertius muscle as a cause of snapping and ankle pain: a case report. Am. J.Sports Med 2007; 35(8):1377-9.
28. Brody PJ, Grumbine N. Peroneus tertius reconstruction for Xexible clawtoes associated with cavus deformity: a preliminary report. J Foot Surg 1984; 23(5):357-361.
29. Gaulrapp H, Heimkes B. Peroneus tertius tendon repair following old traumatic rupture of the anterior tibial tendon (casuistry). Unfallchirurg 1997; 100(12):979-983.