

Effect of Estrogen Replacement Treatment on VEGF in Serum and Retina in Rats

Harun Yüksel¹, Fethiye Gülden Turgut², Fatih M. Türkcü¹, Zeynep Özkurt¹, Muhammed Şahin¹, Hatice Yüksel², Gül Türkcü⁴, Kurşat Cingu¹, İhsan Çaça¹

ABSTRACT

Vascular endothelial growth factor (VEGF) is a molecule implicated in the pathogenesis of several eye diseases. In this experimental study, we planned to evaluate the effects of surgical menopause and hormone replacement therapy on VEGF levels. Thus, we studied the effects of treatments involving estrogen, estrogen and progesterone (E/P) in combination, and genistein, which is a selective estrogen modulator, on serum VEGF levels and the expression of VEGF in the retinas of rats with surgical menopause. The rats were randomly divided into five groups. Bilateral ovariectomy (OVX) was performed in all groups except for the sham-operated group. Estrogen, E/P, genistein or water (sham and control groups) treatments were given for 8 weeks through the orogastric catheter. Serum VEGF level and immunohistochemical staining of VEGF in retinal tissue were analyzed in each group. Serum VEGF levels were significantly higher in the OVX + estrogen and OVX + genistein groups than in the control and sham groups. It was also higher in the OVX + E/P group than in the sham and control groups; however, in this case, the difference was not statistically significant. The OVX + estrogen, OVX + E/P, and OVX + genistein groups exhibited increased VEGF staining in comparison with the control and sham groups. However, the difference was not statistically significant. The current study demonstrated that estrogen replacement treatment (ERT) leads to an increase in serum VEGF levels and progesterone plays a protective role in this increase. The ERT used in this study had no effect on VEGF expression in the retina.

Key words: VEGF, estrogen, genistein, retina, progesterone

Ratlarda Östrojen Replasman Tedavisinin Serum ve Retina VEGF Üzerine Etkisi

ÖZET

Vasküler endotelial büyüme faktörü (VEGF) bir çok retinal hastalığın patogeneğinde suçlanan bir moleküldür. Bu deneysel çalışmada, cerrahi menapoz ve hormon replasman tedavisinin VEGF düzeyine etkisi araştırılmak istenmiştir. Bu nedenle cerrahi olarak menapoz sokulmuş ratlarda östrojenin, östrojen ve progesteron kombinasyonunun ve selektif bir östrojen modülatörü olan genisteinin serumda VEGF seviyesine ve retinal dokuda VEGF ekspresyonuna bakılmıştır. Ratlar randomize olarak 5 gruba ayrıldı. Şam operasyonu yapılan grup hariç bütün ratlara bilateral ovariektomi (OVX) yapıldı. Bütün ratlara 8 hafta boyunca, orogastrik kateter yoluyla östrojen, progesteron, E/P veya su (şam ve kontrol grupları) tedavileri verildi. Her grupta serum VEGF düzeyi ve retinal dokuda immünohistokimyasal boyama ile VEGF analizi yapıldı. Serum VEGF seviyesi OVX + Östrojen ve OVX + Genistein grubunda kontrol ve şam grubundan daha yüksek bulundu. Serum VEGF düzeyi OVX + E/P grubunda da kontrol ve şam grubundan yüksek bulundu fakat fark istatistiksel olarak anlamlı saptanmadı. OVX + Östrojen, OVX + Progesteron ve OVX + E/P gruplarında VEGF boyanması diğer gruplardan daha fazla olmasına rağmen aradaki fark istatistiksel olarak anlamlı değildi. Bu çalışma göstermiştir ki ovariektomize ratlarda östrojen replasman tedavisi (ERT) serum VEGF seviyesini arttırmıştır, ve progesteron bu artışta koruyucu rol oynamıştır. Bu çalışmada ERT retinal dokuda VEGF ekspresyonu üzerine etkili bulunmamıştır.

Anahtar kelimeler: VEGF, östrojen, genistein, retina, progesteron

¹Dicle University Faculty of Medicine, Department of Ophthalmology, Diyarbakir, Turkey, ²Diyarbakir Training and Research Hospital, Department of Ophthalmology, Diyarbakir, Turkey, ³Dicle University Faculty of Medicine, Department of Medical Biochemistry, Diyarbakir, Turkey, ⁴Dicle University Faculty of Medicine, Department of Pathology, Diyarbakir, Turkey

Correspondence: Harun Yüksel
Dicle Üniversitesi Tıp Fakültesi, Sur/Diyarbakir, Turkey
Tel: 90 412 2488001/4461 Fax: 90 412 2488523
E-mail: drharunyukse@gmail.com

INTRODUCTION

Vascular endothelial growth factor (VEGF) is a molecule implicated in the pathogenesis of several eye diseases. In many studies in recent years, the effect of VEGF has been shown in ocular diseases such as age-related macular degeneration (AMD), retinal vein occlusion (RVO), diabetic retinopathy (DR), retinopathy of prematurity and corneal neovascularization. Lately, anti-VEGF drugs used widely in the treatment of the aforementioned ocular diseases (1-4). Many multicenter clinical trials showed the effectiveness of anti VEGF treatments (5-7).

Investigation of factors affecting VEGF will open new horizons in understanding the pathogenesis and treatment of the retinal diseases. In some epidemiological studies, it was reported that prevalence of AMD is greater in females than in males (8,9). In this experimental study, we planned to evaluate the effects of surgical menopause and hormone replacement therapy on VEGF levels. Thus, we studied the effects of treatments involving estrogen, estrogen and progesterone in combination (E/P), and genistein, which is a selective estrogen modulator (SEM), on serum VEGF levels and the expression of VEGF in the retinas of rats with surgical menopause.

MATERIAL AND METHODS

Animals and care and nutrition

This study was performed at the Dicle University Health Sciences Practice and Research Center with the approval Dicle University Animal Ethical Committee. In the present study, 50 female Sprague-Dawley rats weighing approximately 250-300 g. were used. The estrous cycle of the rats was determined by vaginal smear 10 days before the ovariectomy (OVX). Rats were kept at room temperature (22 Celsius degrees); a 12 hour day and 12 hour night cycle was maintained.

Experimental procedure

The rats were randomly divided into five groups (10 rats in each group). Rats were anesthetized with 50 mg/kg ketamine (Ketalar®, Eczacıbası, Istanbul, Turkey) + 5 mg/kg of xylazine (Rompun®, Bayer AG, Leverkusen, Germany). A midline abdominal incision was made at the pelvic level under general anesthesia in all groups and bilateral OVX was performed in all groups except for the sham-operated group.

Groups

Sham group: In this group, the same surgical procedure was performed except for OVX. The rats were given water for 8 weeks by orogastric catheter. No other medication was given.

Control group: Ovariectomy was performed. Orogastric water was given for 8 weeks through the catheter. No other medication was given.

Ovariectomy + estrogen group (OVX + estrogen): Ovariectomy was performed; 0.014 mg/kg/day of 17- β estradiol was administered for 8 weeks with the orogastric catheter.

Ovariectomy + estrogen + progesterone group (OVX + E/P): Ovariectomy was performed; 0.014 mg/kg/day of 17- β estradiol and 0.028 mg/kg/day of drospirone were given for 8 weeks with an orogastric catheter.

Ovariectomy + genistein group (OVX + genistein): Ovariectomy was performed. Genistein 10 mg/kg/day was administered for 8 weeks with an orogastric catheter.

Orogastric treatments were initiated 1 week after the surgical procedure. At the end of the experiment, all rats were euthanized under ketamine anesthesia. In ovariectomized rats, uterine atrophy was verified as indicative of the successful removal of both ovaries. The right eyeball of each rat was enucleated and fixed with 10% formalin.

Immunohistochemical procedure

After fixation in 10% formalin, enucleated eyes were processed for routine light microscopy. Paraffin blocks were prepared and blocks were sliced at a thickness of 3-4 mm thickness; a standard immunohistochemical technique was performed using a Ventana BenchMark XT immunostainer with a mouse monoclonal antibody to VEGF (SC-53462; Santa Cruz Biotechnology, Santa Cruz, CA) at a dilution of 1:50. All specimens were examined and photographed under light microscopy (Axiophot microscope, Zeiss, Germany) by a pathologist blinded to the study groups. The retinal vascular structure was evaluated for each specimen. Immunohistochemical staining was scored semi-quantitatively by an experienced investigator (GT), who was blind to the samples, as follows: 0, absent; 1, weak; 2, moderate; and 3, intense (10).

Biochemical measurements

Rat blood samples were immediately centrifuged and serum was kept at -80°C until laboratory testing. Serum

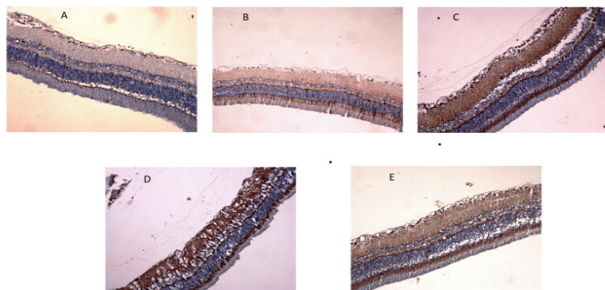


Figure 1. The immunohistochemical staining of VEGF in the retina (HE, X200). Brown staining indicates the immunohistochemical VEGF staining in the retina. A: Sham group, B: Control group, C: Ovariectomy + estrogen group (OVX + E), D: Ovariectomy + estrogen + progesterone group (OVX + E/P), E: Ovariectomy + genistein group (OVX + G). The OVX + E, OVX + E/P, and OVX + G groups exhibited increased VEGF staining in comparison with the control and sham groups. However, the difference was not statistically significant.

VEGF levels were determined using a commercially available quantitative sandwich immunoassay technique (Sun Red Biotechnology Company, Shanghai, China).

Statistical analysis

Statistical analysis was carried out using SPSS 15.0 (Statistical Packages for Social Sciences; SPSS Inc., Chicago, IL, USA). The Kruskal-Wallis test was used for variance analysis and a p value of less than 0.05 was considered statistically significant. The data obtained from the study groups were compared using the non-parametric Mann-Whitney U test with Bonferroni correction; a p value less than 0.005 was considered statistically significant.

RESULTS

For the immunohistochemical staining of VEGF in the retina, the sham and control groups exhibited similar staining patterns. Meanwhile, the OVX + estrogen, OVX + E/P, and OVX + genistein groups exhibited increased VEGF staining in comparison with the control and sham groups. However, the difference was not statistically significant (Figure 1).

Blood VEGF levels are given in Table 1. We found that blood VEGF levels were significantly higher in the OVX + estrogen and OVX + genistein groups than in the control and sham groups. It was also higher in the OVX + E/P group than in the sham and control groups; however, in this case, the difference was not statistically significant.

DISCUSSION

In the present study, estrogen and genistein therapies were shown to significantly increase VEGF levels in the serum of ovariectomized rats. There were no statistically significant differences in VEGF expression in the retina among the groups.

Many studies showed that VEGF was increased in retinal vascular diseases such as AMD, DR, and RVO (7,11,12). The incidence of AMD in females was reported to be greater than that in men in the same age group in many publications (9,8,13-15), although some others were reported that there is no gender difference (16). In addition, some ocular disease has been reported to worsen during pregnancy, including DR (17). In an experimental study, Heidman et al. showed that estrogen supplementation in ovariectomized rats increased the severity of experimental choroidal neovascularization (CNV) (18). Tanemur et al. reported that laser-induced CNV is more frequent in female rats than in male rats (19). These findings suggest that VEGF levels may be affected by estrogen levels.

The effect of estrogen in physiological vascularization is

Table 1. Serum VEGF levels of the groups.

Groups	Sham	Control	OVX + E	OVX + E/P	OVX + G
Serum VEGF (ng/L)	292 ±20	311±19	394±17 ^{a,b}	385±25 ^{c,d}	407±14 ^{e,f}

OVX + E: Ovariectomy + estrogen group, OVX + E/P: Ovariectomy + estrogen + progesterone group, OVX + G: Ovariectomy + genistein group, a statistically significant when compared with sham group (p=0,001), b statistically significant when compared with control group (p=0,004), c not statistically significant when compared with sham group according to the Bonferroni correction (p=0,007), d not statistically significant when compared with sham group according to the Bonferroni correction (p=0,023) e statistically significant when compared with sham group (p<0,001), f statistically significant when compared with control group (p=0,001)

known by its role in vasculogenesis in the endometrium in the menstrual cycle (20). Estrogen also plays an important role in pathological neovascularization, such as in breast cancer and endometriosis (21).

Genistein is an SEM which is found in the soybean. In the literature, clinical and experimental studies have reported the effects of genistein in estrogen deficiency (22-24). In this study, genistein also increased serum VEGF levels in ovariectomized rat and acted like estrogen.

The relationship between estrogen and VEGF has been shown in many experimental studies. Araujo et al. demonstrated that estrogen replacement therapy (ERT) in ovariectomized rats increased the expression of VEGF in thyroid tissue (6). In Suzuma et al.'s study, estrogen increased VEGF and the VEGF receptors in bovine retinal capillary cell culture (4). Dundar et al. examined the expression of VEGF in the retina and choroid when ERT was or was not given to ovariectomized rats; however, they did not see a statistically significant difference between the groups (3). In their study, estrogen was given alone and they did not analyze serum VEGF levels. In our study, there were groups treated with estrogen or genistein alone and another group treated with estrogen combined with progesterone; progesterone addition has been shown to have a protective effect when serum VEGF levels are increased. Similar to the results of Dundar et al.'s study, here in all groups, VEGF expression in the retina was not different from the control group.

In our study, we did not detect a difference between the control and sham groups in terms of VEGF in serum. We suggest that estrogen deficiency did not change the level of VEGF in ovariectomized rats; however, the exogenous estrogen led to an increase in the level of VEGF in the other groups. It may be that the dose of exogenous estrogen and the deficiency of the other ovarian hormones caused this result.

The limitation of this study is that serum VEGF levels were not measured before the ovariectomy. If we had measured it, we could have analyzed the difference; even so we found a difference in the VEGF levels at the end of the experimental procedure among the groups.

In conclusion, the current study demonstrated that ERT leads to an increase in serum VEGF levels and progesterone plays a protective role in this increase. The ERT used in this study had no effect on VEGF expression in the retina. Although we need large population based clinical

studies in this topic, these results suggest that in women using ERT clinicians should be aware of VEGF related retinal diseases.

This study was financially supported by Dicle University Research Fund Project (Project no: DUBAP-12-TF-03)

REFERENCES

1. Kim LA, D'Amore PA. A Brief History of Anti-VEGF for the Treatment of Ocular Angiogenesis. *Am J Pathol* 2012;181:376-9.
2. Türkcü FM, Cinar Y, Türkcü G, et al. Topical and subconjunctival ranibizumab (lucentis) for corneal neovascularization in experimental rat model. *Cutan Ocul Toxicol* 2013; doi:10.3109/15569527.2013.813030
3. Sahin A, Sahin M, Cingü AK, et al. Intravitreal Bevacizumab Monotherapy in Retinopathy of Prematurity. *Pediatr Int Off J Jpn Pediatr Soc* 2013;55:599-603
4. Yüksel H, Türkcü FM, Sahin A, et al. One year results of anti-VEGF treatment in pigment epithelial detachment secondary to macular degeneration. *Arq Bras Oftalmol* 2013;76:209-11.
5. Rofagha S, Bhisitkul RB, Boyer DS, Sadda SR, Zhang K. Seven-year outcomes in ranibizumab-treated patients in ANCHOR, MARINA, and HORIZON: A multicenter cohort study (SEVEN-UP). *Ophthalmology* 2013;120:2292-9.
6. Lang GE, Berta A, Eldem BM, et al. Two-year safety and efficacy of ranibizumab 0.5 mg in diabetic macular edema: interim analysis of the RESTORE extension study. *Ophthalmology* 2013;120:2004-12.
7. Heier JS, Campochiaro PA, Yau L, et al. Ranibizumab for macular edema due to retinal vein occlusions: long-term follow-up in the HORIZON trial. *Ophthalmology* 2012;119:802-9.
8. Mitchell P, Smith W, Attebo K, Wang JJ. Prevalence of age-related maculopathy in Australia. The blue mountains eye study. *Ophthalmology* 1995;102:1450-60.
9. Klein R, Klein BE, Linton KL. Prevalence of age-related maculopathy. The beaver dam eye study. *Ophthalmology* 1992;99:933-43.
10. Dundar SO, Ozcura F, Cetin ED, Beder N, Dundar M. Effects of estrogen replacement therapy on vascular endothelial growth factor expression in choroidal and retinal vasculature. *Bratisl Lekárske Listy* 2010;111(9):473-6.
11. Rosenfeld PJ, Brown DM, Heier JS, et al. Ranibizumab for neovascular age-related macular degeneration. *N Engl J Med* 2006;355:1419-31.
12. Bandello F, Berchicci L, La Spina C, Battaglia Parodi M, Iacono P. Evidence for Anti-VEGF treatment of diabetic macular edema. *Ophthalmic Res* 2012;48:16-20.
13. Ambati J, Ambati BK, Yoo SH, Ianchulev S, Adamis AP. Age-related macular degeneration: etiology, pathogenesis, and therapeutic strategies. *Surv Ophthalmol* 2003;48:257-93.

14. Evans JR. Risk factors for age-related macular degeneration. *Prog Retin Eye Res* 2001;20:227-53.
15. Javitt JC, Zhou Z, Maguire MG, Fine SL, Willke RJ. Incidence of exudative age-related macular degeneration among elderly Americans. *Ophthalmology* 2003;110:1534-9.
16. Miyazaki M, Kiyohara Y, Yoshida A, Iida M, Nose Y, Ishibashi T. The 5-year incidence and risk factors for age-related maculopathy in a general Japanese population: The Hisayama Study. *Invest Ophthalmol Vis Sci* 2005;46:1907-10.
17. Schultz K, Birnbaum A, Goldstein D. Ocular disease in pregnancy. *Curr Opin Ophthalmol* 2005;16:308-14.
18. Espinosa-Heidmann DG, Marin-Castano ME, Pereira-Simon S, Hernandez EP, Elliot S, Cousins SW. Gender and estrogen supplementation increases severity of experimental choroidal neovascularization. *Exp Eye Res* 2005;80:413-23.
19. Tanemura M, Miyamoto N, Mandai M, et al. The role of estrogen and estrogen receptorbeta in choroidal neovascularization. *Mol Vis* 2004;10:923-32.
20. Losordo DW, Isner JM. Estrogen and Angiogenesis A Review. *Arterioscler Thromb Vasc Biol* 2001;21:6-12.
21. Applanat MP, Buteau-Lozano H, Herve MA, Corpet A. Vascular endothelial growth factor is a target gene for estrogen receptor and contributes to breast cancer progression. *Adv Exp Med Biol* 2008;617:437-44.
22. Evsen MS, Ozler A, Gocmez C, et al. Effects of estrogen, estrogen/progesterone combination and genistein treatments on oxidant/antioxidant status in the brain of ovariectomized rats. *Eur Rev Med Pharmacol Sci* 2013;17:1869-73.
23. Marini H, Polito F, Altavilla D, et al. Genistein aglycone improves skin repair in an incisional model of wound healing: a comparison with raloxifene and oestradiol in ovariectomized rats. *Br J Pharmacol* 2010;160:1185-94.
24. Polito F, Marini H, Bitto A, et al. Genistein aglycone, a soy-derived isoflavone, improves skin changes induced by ovariectomy in rats. *Br J Pharmacol* 2012;165:994-1005.