

A Giant Hamartoma of Tuber Cinerium: Conventional MR Imaging and MR Spectroscopy Findings

Mustafa Koplay¹, Hasan Erdoğan¹, Mesut Sivri¹, Cengiz Erol¹, Asuman Varoğlu², Yahya Paksoy¹

ABSTRACT

Hypothalamic hamartoma is a developmental malformation in the region of tuber cinereum and mamillary bodies. It presents the most commonly detectable lesion in patients with precocious puberty and is associated with gelastic seizures. As well as, it can be completely silent to be found only incidentally. Computed tomography (CT) and magnetic rezonans (MR) imaging are preferred imaging modalities in diagnose of hypothalamic hamartomas. The aim of this study is to present the radiologic imaging findings of a rare hypothalamic hamartoma case.

Key words: Hypothalamic hamartoma, giant, tuber cinereum, MR imaging, spectroscopy

Tuber Sineryumun Dev Bir hamartomu: Konvansiyonel MR ve MR Spektroskopisi Bulguları

ÖZET

Hipotalamik hamartoma tuber sineryum bölgesinde ve mamilalar cisimciğinin bir gelişimsel anomalisidir. Bu yaygın olarak puberte öncesi dönemde saptanabilmekte ve gelastic nöbetler ile ilişkilidir. Tamamen sessiz olabilir. ve tesadüfen tespit edilebilir. Bilgisayarlı tomografi (BT) ve manyetik rezonans (MR) görüntüleme hipotalamik hamartomların tanısında görüntüleme yöntemleri olarak tercih edilmektedir. Bu çalışmanın amacı nadir bir hipotalamik hamartomu olgusunun radyolojik görüntüleme bulgularını sunmaktır.

Anahtar kelimeler: Hipotalamik hamartom, dev, tuber sineryum, MR bulguları, spektroskopisi

INTRODUCTION

Hypothalamic hamartomas (HH) are rare, congenital, nonneoplastic heterotopias that are originating from tuber cinereum and mamillary bodies. Prevalence of HH is between 50,000 to 100,000 (1). The characteristic clinical symptoms are precocious puberty, gelastic seizure, cognitive and behavioral abnormalities in children and, generalize seizure accompanying with tonic, atonic and other convulsions in adults (2). The radiological presentation can also vary. HH usually determined in the form of a suprasellar, non-enhanced mass in the hypothalamus. Epilepsy in patients with HH is usually resistant to medical treatment, therefore surgery should always be considered in treatment. The largest HH that was reported is 5 cm dimension (3). The aim of this study is to present the radiologic imaging findings with huge dimension of a rare HH case.

CASE

A 17 year old boy presented with generalized tonic-clonic seizures since the age of 1 year. Neuroimaging findings were atypical, showing the large tumor (maximum diameter, 56 mm) with a cystic component and calcification. In physical examination, there are no findings other than speech aphasia and assisted walking. Brain magnetic resonance (MR) imaging revealed that, 5,6x4x2 cm dimension, isointens with grey matter on T1 and T2 weighted images, no contrast enhancement mass in tuber cinereum is present (Figure 1). The lesion pressed to 5, 6. and 8. cranial nerves because of its localization. On Diffusion MR imaging, it's seen that, lesions signal characterization is similar to neural parenchyma (Figure 2). The imaging findings are compatible with hamartoma. In single-voxel proton MR spectroscopy of the mass lesion, metabolic distribution revealed

¹Department of Radiology, Medical Faculty, Selcuk University, Konya, Turkey, ²Department of Neurology, Medical Faculty, Selcuk University, Konya, Turkey

Received: 29.10.2013, Accepted: 11.12.2013

Correspondence: Mustafa Koplay M.D.
Selcuk University, Medical Faculty Department of Radiology The Central Campus,
42100, Konya, Turkey
Tlf: +90-332-2243800- 44930
E-mail: koplaymustafa@hotmail.com

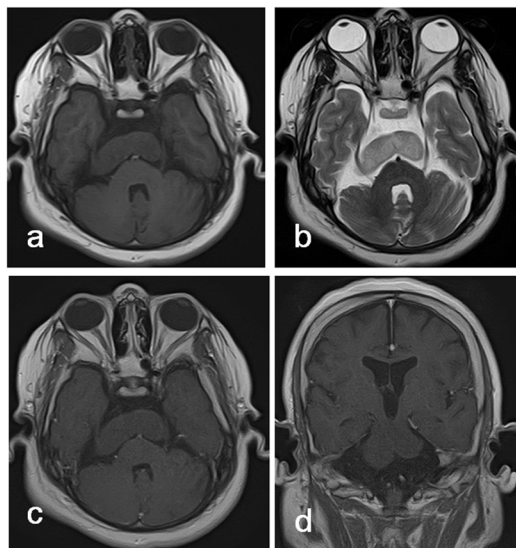


Figure 1. In axial T1W (a), axial T2W (b), postcontrast axial (c) and coronal (d) T1 weighted images show that giant mass in tuber cinerium. It seems to be isointense with

decreased N-acetylaspartate (NAA), increased myo-inositol (MI), and slightly elevated choline (Cho) (Figure 3). The patient is followed with medical treatment, surgical treatment was not considered.

DISCUSSION

Hypothalamic hamartomas are relatively rare, non-neoplastic congenital malformations. They may be pedunculated, adjacent to the mammillary bodies or tuber cinerium by a thin stalk, or sessile (4). The character-

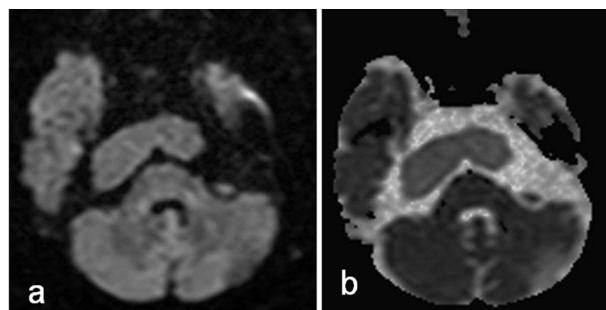


Figure 2. In diffusion weighted images show that lesion signal characterization is similar to neural parenchyma.

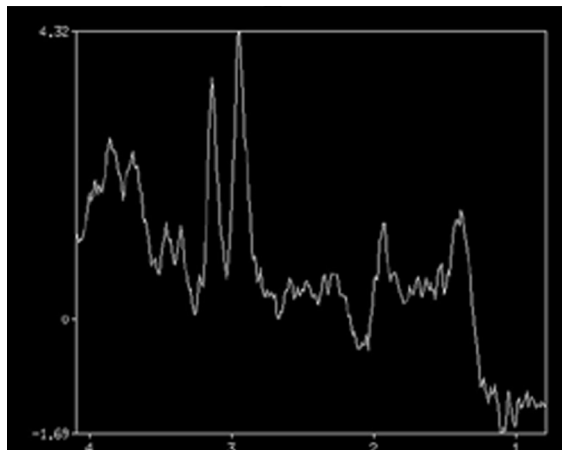


Figure 3. MR spectroscopy of the mass shows metabolic distribution decreased NAA, increased MI, and slightly elevated Cho.

istic clinical symptoms are precocious puberty, gelastic seizure, cognitive and behavioral abnormalities generalize seizure accompanying with tonic, atonic and other convulsions (5). Seizure is the main neurologic manifestation of HH and gelastic seizures beginning early in life are the classical epileptic presentation. Gelastic seizures are epileptic events characteristic by bouts of laughter and they are rarely diagnosed at onset. They may be mistaken for normal laughter (6).

Computed tomography (CT) and MR imaging are used to diagnose of HH. CT is not sensitive to the presence of the HH. MR imaging is the study of choice for patients with clinical suspicion of HH. These lesions have typically been described as isointense to gray matter on T2-weighted and T1-weighted images (7). The characteristic location, isointensity to normal brain, lack of contrast enhancement of the solid compartment of the mass, the absence of hemorrhage and calcification and absence of change in size and morphology of the mass at the follow-up. In MR spectroscopy, metabolic distribution shows decreased NAA, increased MI, and elevated Cho levels. In literature, the largest HH size is 5 cm (3). HH in our patients is size of 5,6 cm. Classification of the lesion is important for treatment and accurately predict of its prognosis. Also type and size of the lesion is important. Precocious puberty is more common in the pedunculated type and <1 cm size of lesion. On the other hand gelastic seizures are more common in the sessile

type and >1 cm size of lesion (8). Differential diagnosis of HH may include craniopharyngioma, chiasmatic/ hypothalamic astrocitoma, optic/hypothalamic astrocitoma, Rathke cleft cyst ectopic posterior pituitary, germinomas, langerhans cell histiocytosis and lipoma (1-8). Treatment options in HH are surgical or medical. Medical treatment contains use GnRH analogue or antagonists until puberty. Surgical treatment is considered in young children, whereas in children close to puberty, surgical treatment is not required. In conclusion, typical clinical presentation, uncommon location and characteristic conventional MR imaging and MR spectroscopy findings help the diagnosis of HH. Early diagnosis and treatment, the seizures are improved and the reduction in their cognitive abilities are avoided.

REFERENCES

1. Branberg G, Raininko R, Eeg-Olofson O. Hypothalamic hamartoma with gelastic seizures in Swedish children and adolescents. *Eur J Paediatr Neurol* 2004;8:35-44.
2. Ng SM, Kumar Y, Cody D, Smith CS, Didi M. Cranial MRI scans are indicated in all girls with central precocious puberty. *Arch Dis Child* 2003;88:414-41.
3. Yamaguchi S, Suzuki SO, Matsuo Y, et al. Large hypothalamic hamartoma with calcification and cystic components in an adult-case report. *Neurol Med Chir* 2010;50:495-8.
4. Boyko OB, Curnes JT, Oakes WJ, Burger PC. Hamartomas of the tuber cinereum: CT, MR, and pathologic findings. *AJNR Am J Neuroradiol* 1991;12:309-14.
5. Berkovic SF, Andermann F, Melanson D, Ethier RE, Feindel W, Gloor P. Hypothalamic hamartomas and ictal laughter: evolution of a characteristic epileptic syndrome and diagnostic value of magnetic resonance imaging. *Ann Neurol* 1988;23:429-39.
6. Alkan O, Kizilkilic O, Karsantiozu T. Clinical Manifestations and MR Imaging Features In Hypothalamic Hamartomas. *J Neurol Sci [Turk]* 2009;26:335-342
7. Shah P, Patkar D, Patankar T, Shah J, Srinivasa P, Krishnan A. MR imaging features in hypothalamic hamartoma: a report of three cases and review of literature *J Postgrad Med* 1999; 45:84-6.
8. Boudreau EA, Liow K, Frattali CM, et al. Hypothalamic hamartomas and seizures: distinct natural history of isolated and Pallister-Hall syndrome cases *Epilepsia* 2005;46:42-7