

Diverticulitis of Cecum Mimicking Plastron Appendicitis: A Diagnostic and Therapeutic Dilemma

Zulfu Arikanoglu¹, Fatih Taskesen¹, Murat Kapan¹, Hatice Gümüş², Ibrahim Halil Tacyildiz¹

ABSTRACT

Cecal diverticulitis is an unusual condition that presents clinically similar to appendicitis. Although it is usually asymptomatic, it may cause inflammation, bleeding, or perforation. The diagnosis is not always easy and in the majority of cases, the diagnosis is usually made at laparotomy. There have been various controversies in the literature regarding the optimal management of cecal diverticulitis. The aim of this study is a detailed description of this rare cause of acute abdomen. A 40-year-old female patient presenting with acute onset pain in the right lower abdominal quadrant, nausea and fever had mild leukocytosis. Abdominal ultrasonography and computed tomography revealed findings suggestive of plastron appendicitis. The diagnosis of cecal diverticulitis was established during the surgery. The patient underwent diverticulectomy and appendectomy operations. Cecal diverticulitis is rare clinical entity that should be considered in the differential diagnosis of emergency patients admitted with the complaint of pain in the right lower abdominal quadrant.

Key words: Cecal diverticulitis, plastron appendicitis, surgical treatment

Blastron Apendisitisi Taklit Eden Çekum Divertiküliti

ÖZET

Çekal divertikülit klinik olarak apendisite benzeyen nadir bir durumdur. Genellikle asemptomatik olmasına rağmen, inflamasyon, kanama ve perforasyona sebep olabilir. Vakaların çoğunluğunda tanı zordur ve genellikle laparatomide tanı konulur. Literatürde çekal divertikülitin tedavisi ile ilgili çeşitli tartışmalar mevcuttur. Bu yazının amacı akut karının nadir bir nedeni olan çekal divertiküliti detaylı bir şekilde incelemektir. Akut sağ alt kadranda ağrısı, bulantı ve ateşi olan 40 yaşında kadın hastanın hafif lökositozu vardı. Abdominal ultrasonografi ve tomografide plastron apendisiti düşündürülen bulgular mevcuttu. Çekal divertikülit tanısı operasyon esnasında konuldu. Hastaya divertikülektomi ve apendektomi yapıldı. Çekal divertikülit, sağ alt kadranda ağrısı olan acil vakalarda ayrıca tanıda düşünülmesi gereken nadir görülen bir durumdur.

Anahtar kelimeler: Çekal divertikülit, blastron apendisit, cerrahi tedavi

INTRODUCTION

As a rare clinical entity, the cecal diverticulitis is of no certain etiology. The true prevalence of cecal diverticulosis is difficult to ascertain, however, the reported frequency is about 1 in 300 appendectomies (1). Although generally asymptomatic, they are likely to become symptomatic in the presence of complications like inflammation, perforation and bleedings. Making

definitive diagnosis is challenging due to symptoms resembling those of acute appendicitis (1, 2). Imaging modalities like ultrasonography (US) and computed tomography (CT) can be implemented in diagnosis. Due to low sensitivity of US, CT appeared to become the most useful imaging method in the preoperative period. In spite of the information provided by US or CT scans, a correct preoperative diagnosis is still difficult (3). The suffering patient is usually operated on under

¹Department of Surgery Dicle University Faculty of Medicine, 21280, Diyarbakir, Turkey, ²Department of Radiology, Dicle University Faculty of Medicine, 21280, Diyarbakir, Turkey

Received: 16.03.2012, Accepted: 17.12.2012

Correspondence: Zulfu Arikanoglu, Dicle University Faculty of Medicine Department of General Surgery 21280, Yenisehir, Diyarbakir, Turkey
Phone: +90 412 248-8001 (4754) Fax: +90 412 248-8523
E-mail: zulfuarikanoglu@gmail.com

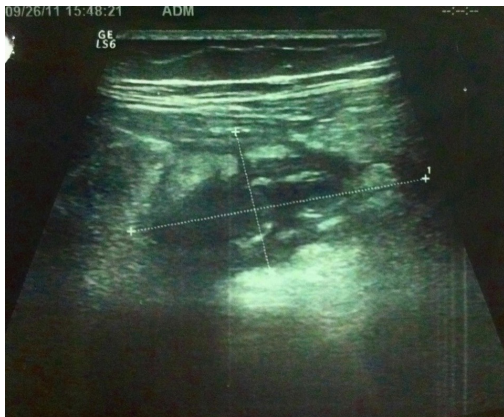

Figure 1. An abdominal US shows pericecal focal fluid that surrounding with omentum.

emergency conditions due to rapid onset of the symptoms, for which reason the definitive treatment is made during operation. No robust consensus is achieved over the treatment modalities. The management described in the literature contains a large amount of variations ranging from implementation of a simple antibiotherapy to a sophisticated right hemicolectomy (4).

We report a case of cecal diverticulitis mimicking plastrone appendicitis on preoperative diagnosis and perform a literature review.

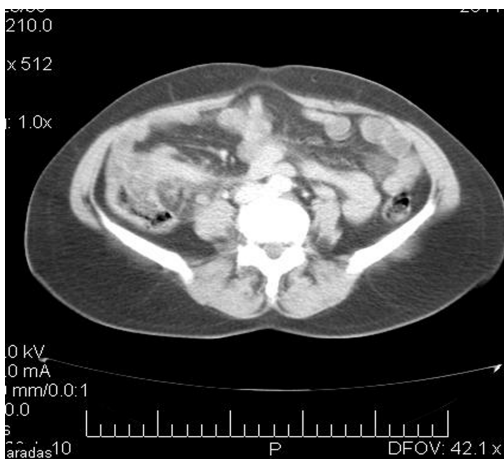


Figure 2. An axial abdominal CT image shows inflammatory changes of the cecum and pericecal fat tissue.

CASE

A 40-year-old woman admitted to the Emergency Department with a five-day history of continuous right-lower quadrant pain, nausea and fever. There was no history of vomiting. The body temperature, the pulse and the blood pressure were measured to be 38.5 0C, 94 beats/min and 140/90 mmHg, respectively. On physical examination, right lower quadrant tenderness and firm mass measuring approximately 4x4 cm were noted. Rectal examination was unremarkable. The physical examination findings related to the other organ systems are normal. Except for leukocytosis (15200/mm³), other laboratory values were in normal ranges.

An abdominal US showed pericecal focal fluid that surrounding with omentum in right lower quadrant (Fig. 1). An abdominal CT with contrast revealed a thickened cecal wall and inflammatory changes of focal pericecal fat tissue (Fig. 2). Taking the clinical, the laboratory and the radiological findings together, the definitive diagnosis of plastrone appendicitis was made clear in the patient. Responding well to conservative treatment, the patient was discharged from the hospital, planning a further elective surgery under elective conditions. Two month later, a diverticle of 10 mm diameter stemming from the anterior surface of the caecum was detected during laparotomy and diverticulectomy and incidental appendectomy were performed. The patient had an uneventful recovery, was discharged on the postoperative 6th day and she did not take any additional therapy. The lesion was interpreted as solitary cecal diverticulitis in the pathologic examination.

DISCUSSION

Cases with cecal diverticulosis constitute 1-5% of those with diverticular disease. The mean age of the patients is around 40 years, with male predominance of 60%. The exact cause of cecal diverticulitis is unknown. The area which is approximately 2.5 cm from the ileo-cecal junction is the area from which eighty percent of all cecal diverticula stem. Moreover, half of the diverticula tend to lie anterior to the cecal wall (4). Cecal diverticula's can remain asymptomatic for years. Only did they produce symptoms in the presence of complications like inflammation or perforation. The most frequent clinical manifestations of cecal diverticulitis include abdominal pain in the right lower quadrant, fever, and leukocytosis

and with these symptoms a differential diagnosis should be established not only with acute appendicitis (2, 3). The pain induced by cecal diverticulitis, as distinct from acute appendicitis, commences in the right lower quadrant and remains localized to that region. Persistence of pain in the right lower quadrant for longer durations, presence of less frequent nausea and vomiting, and less severe toxic condition may help differentiate clinically the right colonic diverticulitis (5). The differential diagnosis should include the tumors giving rise to pain in the right lower abdominal quadrant, solitary cecal ulcer, Crohn's disease, tuberculosis, tubo-ovarian disease, cholecystitis, actinomycosis, amebiasis (3, 6).

Rarity of cecal diverticulitis and resemblance of the symptoms to those of acute appendicitis confer a great amount of challenge to establishing definitive diagnosis in the preoperative period. The role of laboratory analysis in making the definitive diagnosis is limited (7), since that yields no significant result other than moderate-degree leukocytosis. The clinical findings and the laboratory results of our case bear resemblance to those of acute appendicitis. Radiologic investigations prove the most beneficial methods for accurate diagnosis in the preoperative period. Although plain x-rays and abdominal US yield nonspecific findings for the most part, CT is fairly useful in the diagnosis. Abdominal X-rays may reveal a fecalith in up to 50% of cases, and opaque enema may contribute to diagnosis by defining the diverticulum (3). Cecal diverticulum appears as a hypoechoic out pouching, which stems from a broadened segment colonic wall in US. CT imaging can be used in the diagnosis of acute appendicitis, showing equal sensitivity and specificity of 98%. Thinning of the colonic wall, pericolic fatty infiltration, abscess formation and presence of extraluminal air might be observed in abdominal CT, which may also be evident in plastron appendicitis, though (3). Even if colon barium graphy can ascertain the diagnosis, this diagnostic modality performed in every cases is hardly due to the fact the clinic in these cases generally mimic that of acute appendicitis, thereby necessitating emergency surgery in most of the cases (8). The definitive diagnosis of cecal diverticulitis is most commonly made clear intra-operatively during exploration for suspected appendicitis (9). We had already suspected from acute plastron appendicitis in our case with no history of prior appendectomy based on the evaluation of nonspecific findings from US and CT together with the clinical findings and laboratory analysis, yet the defini-

tive diagnosis was only established intraoperatively. The management to be applied is subject to change on the basis of intraoperative findings. However, debates as to which one of the treatment methods, namely the conservative and radical surgical treatments, remain alive. When the diagnosis is made before the operation, some authors have advocated nonoperative management with antibiotic therapy (9). Furthermore, a conservative treatment can be planned if carcinoma managed to be ruled out or in the absence of widespread inflammation (5). Some surgeons recommend surgical treatment, claiming that cecal diverticulitis does not usually resolve with medical therapy and has a high rate of recurrence with complications (9). In contrast, other authors favor conservative treatment, stating that it is a safe and effective treatment regimen with a low recurrence rate (9). Harada and et al (10), recommended also performing an appendectomy to eliminate the appendix as a future source of confusion. In our case, diverticulectomy together with appendectomy was performed on the elective condition.

In conclusion, cecal diverticula are an asymptomatic and relatively rare clinical condition. However, cecal diverticulitis should be included in the differential diagnosis of the cases with pain in the right lower quadrant. The definitive diagnosis cannot always be made, although patient's clinical condition, laboratory findings and imaging methods are jointly evaluated. Preoperative diagnosis of cecal diverticulitis is important in order to decide how to manage to this condition.

REFERENCES

1. W.Schummer, C.Schummer, E.Hoffmann. *Chylothorax nach Anlage eines zentralvenösen Katheters. Anaesthesist* 2003;52:919-24.
2. Frassinelli P, Pasquale MD, Cipolle MD, Rhodes M. *Utility of chest radiographs after guide wire exchanges of central venous catheters. Crit Care Med* 1998;26:611-5.
3. Moyers JR. *Application of the basic physical examination to intraoperative monitoring. In: Morgan GE, Mikhail MS, Murray MJ, editors. Clinical anesthesiology. 4th ed. New York: McGraw-Hill Medical; 2006. pp. 148-69.*
4. David LR, Mittnacht JCA, Manecke GR, Kaplan JA. *Monitoring of the heart and vascular system. In: Kaplan JA, Reich DL, Savino SJ, editors. Cardiac Anesthesia. 6th ed. Philadelphia: W.B. Saunders, 2010. pp. 416-50.*
5. Yilmazlar A, Bilgin H, Korfali G, Eren A, Ozkan U. *Complications of 1303 central venous catheterizations. J Roy Soc Med* 1997;90:319-21.

6. Berman W Jr, Fripp RR, Yabek SM, Wernly J, Corlew S. Great vein and right atrial thrombosis in critically ill infants and children with central venous lines. *Chest* 1991;99:963-7.
7. Demirhan R, Cevik A, Kucuk HF, Altintas M, Kurt N. Traumatic chylothorax: case report Turkish j thorac cardiovasc surg 2003;11:50-1.
8. Hui-Fang Hsu, Yi-Hung Chou, Chao-Ran Wang, Shu-Chuan Wu. Catheter-Related Superior Vena Cava Syndrome Complicated by Chylothorax in a Premature Infant *Chang Gung Med J* 2003;26:782-6.
9. Berkenbosch JW., Monteleone PM, and Tobias JD. Chylothorax Following Apparently Spontaneous Central Venous Thrombosis in a Patient With Septic Shock *Pediatric Pulmonology* 2003;35:230-3.
10. Wu ET, Takeuchi M, Imanaka H, Higuchi T, Kagisaki K. Chylothorax as a complication of innominate vein thrombosis induced by a peripherally inserted central catheter. *Anaesthesia* 2006;61:584-6.