

# Disintegration of a Balloon-Expandable Stent in the Iliac Artery Upon Delivery

Fuat Ozkan<sup>1</sup>, Bora Peynircioglu<sup>2</sup>, Murat Canyigit<sup>3</sup>, Onur Ergun<sup>4</sup>, Barbaros Erhan Cil<sup>2</sup>, Saruhan Cekirge<sup>2</sup>

## ABSTRACT

Although there are still some controversies on the choice of ideal stent as well as balloon-expandable versus self-expanding stents for aorto-iliac disease; iliac stenting is widely accepted procedure for focal atherosclerotic iliac artery stenosis. Herein, we present an unusual unilateral iliac stenting complication caused by disintegration struts of balloon-expandable stent which was successfully handled by means of kissing stents. 62-year-old woman presented with complaints of severe claudication of the right lower extremity. Short segment stenosis of the proximal right common iliac artery was detected. Balloon-expandable stent was deployed and stent delivery catheter was then exchanged uneventfully for the pigtail catheter followed by a control arteriogram which demonstrated the fractured and elongated stent into the distal aorta centrally. Then, two self-expandable nitinol stents were deployed in bilateral common iliac artery in order to compress the fractured stent struts against the aortic wall. Control arteriogram was obtained showing excellent result with no residual stenosis. However, stent fractures involving balloon-expandable stents in the iliac arteries are extremely rare, this unusual stent fracture type should be considered before implantation of a stent in the iliac artery.

**Key words:** Complications, stents, iliac artery

## İlyak Arter Stentleme Esnasında Balon İle Genişleyebilen Stent Strutlarının Bozulmasının Endovasküler Tedavisi

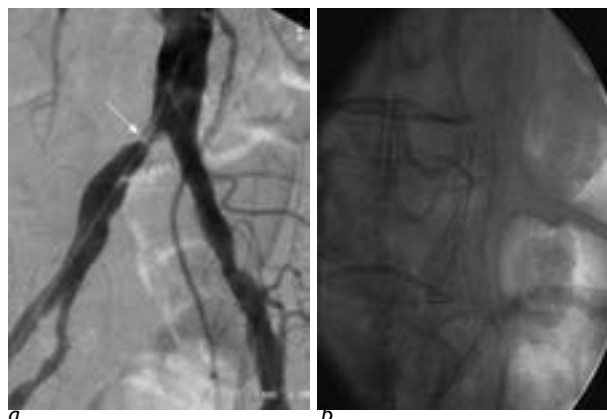
### ÖZET

İlyak stentleme, fokal aterosklerotik iliyak arter stenoz tedavisinde kabul edilen tedavi yöntemi olmakla birlikte stent seçimi önemli rol oynamaktadır. Bu olguda nadir bir iliyak stent komplikasyonu olan balon ile genişleyebilen stent strutlarının bozulmasının kissing stent tekniği ile tedavisini sunuyoruz. Sağ bacağına şiddetli klodikasyon şikayeti olan 62 yaşındaki hastanın yapılan tetkiklerinde proksimal sağ ana iliyak arterde kısa segment darlık saptandı. Sorunsuz yerleştirilen balon ile genişleyebilen stent sonrası elde olunan kontrol anjiyografilerde stentin strutlarının dağılarak stent boyunun uzadığı distal aortaya doğru yer değiştirdiği görüldü. Bunun üzerine strutları damar duvarına yaslamak için kissing tekniği ile bilateral kendiliğinden genişleyen nitinol stent yerleştirildi. Kontrol anjiyografide rezidüel stenoz saptanmadı. Sonuç olarak iliyak arter stentlemede bu tip nadir komplikasyonlar göz önünde bulundurulmalıdır.

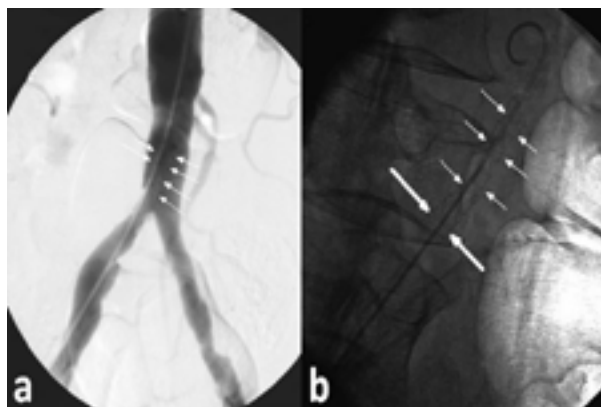
**Anahtar kelimeler:** Komplikasyon, stent, iliyak arter

<sup>1</sup>Kahramanmaraş Sutcu Imam University, Faculty of Medicine, Department of Radiology, Kahramanmaraş, <sup>2</sup>Hacettepe University, Faculty of Medicine, Department of Radiology Sıhhiye, Ankara, <sup>3</sup>Ankara Atatürk Training and Research Hospital, Department of Radiology, 06800 Bilkent, Ankara, <sup>4</sup>Sincan State Hospital, Radiology Clinic, Sincan, Ankara, Turkey

**Correspondence:** Fuat Ozkan, Kahramanmaraş Sutcu Imam University, Faculty of Medicine, Department of Radiology 46050 Yörükselim mah. Hastane cad. No:32, Kahramanmaraş, Turkey  
Phone : 903442212337/ Ext189, Fax: 903442212371  
E-mail: drfozkan@yahoo.com



**Figure 1.** a. The diagnostic angiogram showed 90% stenosis at proximal segment of the right common iliac artery. b. Control arteriogram was obtained showing excellent result with no residual stenosis



**Figure 2.** Control arteriogram after deployment of the balloon expandable stent demonstrates fractured and elongated stent in to the distal aorta (a). Oblique projection shows fractured stent struts (thin arrow) and normal part of the stent segment (thick arrow) (b).

## INTRODUCTION

Balloon angioplasty and stent placement is a well-established treatment method used in the treatment of common iliac artery stenoses in patients with peripheral vascular disease. Balloon-expandable stents have been used in straighter segments and shorter lesions, whereas, self-expandable stents being more often used in tortuous and longer segments (1). Although stents have several advantages over balloon angioplasty, inherent risks of stenting including the complication of stent fracture can be occurred. Stent deployment in arteries crossing flexion points, such as the common femoral artery (CFA) and the popliteal artery, are well known to fracture (2). In comparison to the femoral artery, the iliac artery is subjected to less external stress, stenotic lesions within the iliac artery tend to be shorter. These factors may result in a lower rate of stent fracture in the iliac artery (2). Although stent fractures involving balloon-expandable stents in the iliac arteries are extremely rare, to the best of our knowledge this is the first case with unusual type of stent fracture observed in balloon-expandable stent.

We present an unusual stenting complication and its management which demonstrates how a routine procedure can be more complicated within few seconds. Although this complication was successfully handled with a satisfactory result; it may not be tolerated if such a complication occurred in other arterial territories such as renals or supraaortic arterial system.

## CASE

A 62-year-old woman presented with a severe claudication on the right leg for which she underwent a lower extremity arteriogram 3 months back at an outside hospital showing more than 75% short segment stenosis at the proximal right common iliac artery. She was referred to our center for further evaluation and treatment. Past medical history was only significant for diabetes mellitus with no history of smoking. Physical examination revealed hardly palpable right femoral arterial pulse and nothing distally at popliteal, tibialis anterior or dorsalis pedis arteries. Considering the short segment proximal common iliac artery stenosis, endovascular treatment with unilateral single stent placement was planned.

Under local anesthesia, using micropuncture set under sonographic guidance, a 7F 25cm sheath (Terumo Co, Tokyo, Japan) was introduced via the right common femoral artery. Magic Torque guidewire (Boston Scientific, Watertown, MA, USA) was advanced gently through the stenosis into the aorta, which was followed by a pelvic angiography with 4F pigtail catheter (Terumo Co, Leuven, Belgium). The diagnostic angiogram showed 90% stenosis at proximal segment of the right common iliac artery (Figure 1). Stent size was chosen in accordance with the nominal diameter of the target artery and landing zone. Then over a Superstiff Amplatz wire (Boston Scientific, Miami, FL, USA), an 8x26mm pre-mounted balloon-expandable stent (Paramount, EV3, St. Paul, MN, USA) was placed across the stenosis under

roadmap guidance. Then, balloon was inflated up to 6 atmospheres to deploy the stent (Balloon nominal pressure: 10 mmHg, rated burst: 10 mmHg). The stenosis was effaced at 6 ATM easily and deflation and removal of the stent delivery catheter was uneventful. Stent delivery catheter was then exchanged uneventfully for the pigtail catheter followed by a control arteriogram which demonstrated the fractured and elongated stent into the distal aorta centrally (Figure 2 a-b). The stent was now measured 37 mm in length extending into the distal aorta. On the other hand, distal end of the stent was at the ideal position within the common iliac artery with no evidence of migration, fracture or crush. At this point, decision was made to switch to the kissing stent technique in order to compress the fractured stent struts against the aortic wall at the same session. Afterwards, left main femoral artery was accessed with a Seldinger technique followed by 6F 25cm sheath (Terumo Co, Tokyo, Japan) placement in to the left common iliac artery. Previous stent was bypassed carefully using Terumo glidewire (Terumo Co, Tokyo, Japan). Extreme care was taken not to pass through the mesh of the other stent. Next, two 10 x 40 mm self-expandable nitinol stents (Protege, EV3, St. Paul, MN, USA) were advanced via both groin accesses and deployed in a "kissing" fashion into the aortoiliac arteries at the same level. Control arteriogram was obtained showing excellent result with no residual stenosis (Figure 1 b). The stent on the right side, of course could not be expanded up to 10 mm diameter due to the outer 8mm stent. No post-dilation was needed. Pelvic arteriogram showed simultaneous filling of the both iliofemoral arteries with excellent flow. Physical examination revealed '++' arterial pulses along the right lower extremity immediately after the procedure including popliteal artery, tibialis posterior artery and dorsalis pedis artery.

## DISCUSSION

Percutaneous transluminal angioplasty (PTA) is a safe and effective method in the treatment of aortoiliac occlusive disease. However, complications of the procedure and recurrent stenosis have led to the increased use of intravascular stents (3). The original indications for stents were poor results of PTA and periprocedural complications but these indications have been expanded and stents are now used to treat complex vascular lesions such as long artery occlusions (4, 5).

In recent years, several kinds of stents have been developed, providing the ideal properties such as high radial force/hoop strength to resist recoil, minimal or no induction of intimal hyperplasia or restenosis, high radiopacity for visualization, easy deployment system, MR imaging compatibility, durability, low price, etc. (6).

The balloon-expandable stents have preferred to be appropriate choice for intraluminal treatment of stenoses and occlusive lesions in the iliac arteries owing to have above mentioned properties. Balloon-expandable stents have also advantage over self-expanding stents in terms of precision of placement and radial expansion force especially when treating a calcified, resistant, fibrous, or eccentric lesion (6, 7). However, procedural complications associated with balloon-expandable stent placement in the iliac arteries can have serious consequences, such as distal embolization, arterial rupture, arterial disruption leading to pseudoaneurysm, dissection of an adjacent arterial segment (8). There have been only two reports of stent fractures involving balloon-expandable stents used for treatment of stenoses and occlusive lesions in the iliac arteries. Sawhney et al. (1) reported a case of kissing balloon-expandable stents complicated by stent fracture in a 37-year-old man who performed extensive daily stretching and calisthenics. They speculated that his forceful exercise regimen induced fracture of the stents. Sacks et al. (9) described fracture of a Palmaz stent within the stent-overlapping zone when the stent had been placed in the external iliac artery. A review of the literature found no mention of stent fractures as a periprocedural complication involving the use of balloon-expandable stents in the iliac arteries. Allie et al. have suggested a 4-type classification system for nitinol stent fracture in peripheral vessels, which was later expanded to 5 types by Jaff et al (10). A type I fracture involves only a single strut; type II involves multiple struts that can occur at different sites; type III involves multiple strut fractures resulting in complete transverse fracture without displacement; type IV result in a complete transverse linear fracture with stent displacement; and type V is spiral fracture. However, our case was similar to type V fracture type, proximal two thirds of the struts were cracked in our case. Several studies reported that nitinol stents undergo negative dilation when exposed to body temperature that can stress the already present manufacture-associated microcracks intrinsic to the stent (11). All stents may be exposed to as many as 10 (8) cyclic systolic/

diastolic loads over a designed lifetime of 10 years. This persistent pulsatile loading may result in propagation of these microcracks (12). In our case disintegration of the balloon-expandable stent might be occurred through the similar pathway. According to the manufacturer's guidelines, the expiration date for this device had not been exceeded, and the packaged stents were stored under optimal conditions in our facility.

Although this case could have been treated with kissing stenting initially; we intended to use single balloon expandable stent for short segment stenosis which was then complicated with stent disintegration and eventually ended up kissing stenting with additional 2 self-expandable stents. Central ends of the kissing stents were placed slightly higher than actually desired for kissing stents in order to compress the fractured stent against the aortic wall. However, stent fractures involving balloon-expandable stents in the iliac arteries are extremely rare, this unusual stent fracture type should be considered before implantation of a stent in the iliac artery.

## REFERENCES

1. Sawhney R, Allen D, Nanavati S. Kissing balloon-expandable iliac stents complicated by stent fracture. *J Vasc Interv Radiol* 2008; 19:1519-1520
2. Ichihashi S, Higashiura W, Itoh H, Sakaguchi S, Kichikawa K. Fracture and Collapse of Balloon-Expandable Stents in the Bilateral Common Iliac Arteries Due to Shiatsu Massage. *Cardiovasc Intervent Radiol* Dec 23 2011
3. Palmaz JC, Laborde JC, Rivera FJ, Encarnacion CE, Lutz JD, Moss JG. Stenting of the iliac arteries with the Palmaz stent: experience from a multicenter trial. *Cardiovasc Intervent Radiol* 1992; 15:291-297
4. De Roeck A, Hendriks JM, Delrue F, et al. Long-term results of primary stenting for long and complex iliac artery occlusions. *Acta Chir Belg* 2006; 106:187-192
5. Ozkan U, Oguzkurt L, Tercan F, Gumus B. Endovascular treatment strategies in aortoiliac occlusion. *Cardiovasc Intervent Radiol* 2009; 32:417-421
6. Leung DA, Spinosa DJ, Hagspiel KD, Angle JF, Matsumoto AH. Selection of stents for treating iliac arterial occlusive disease. *J Vasc Interv Radiol* 2003; 14:137-152
7. Grenacher L, Rohde S, Ganger E, Deutsch J, Kauffmann GW, Richter GM. In vitro comparison of self-expanding versus balloon-expandable stents in a human ex vivo model. *Cardiovasc Intervent Radiol* 2006; 29:249-254
8. Reekers JA, Vorwerk D, Rousseau H, et al. Results of a European multicentre iliac stent trial with a flexible balloon expandable stent. *Eur J Vasc Endovasc Surg* 2002; 24:511-515
9. Sacks BA, Miller A, Gottlieb M. Fracture of an iliac artery Palmaz stent. *J Vasc Interv Radiol* 1996; 7:53-55
10. Jaff M, Dake M, Pompa J, Ansel G, Yoder T. Standardized evaluation and reporting of stent fractures in clinical trials of noncoronary devices. *Catheter Cardiovasc Interv* 2007; 70:460-462
11. Stankiewicz JM, Robertson SW, Ritchie RO. Fatigue-crack growth properties of thin-walled superelastic austenitic Nitinol tube for endovascular stents. *J Biomed Mater Res A*. 2007; 81:685-691
12. Adlakha S, Sheikh M, Wu J, et al. Stent fracture in the coronary and peripheral arteries. *J Interv Cardiol* 2010; 23:411-419