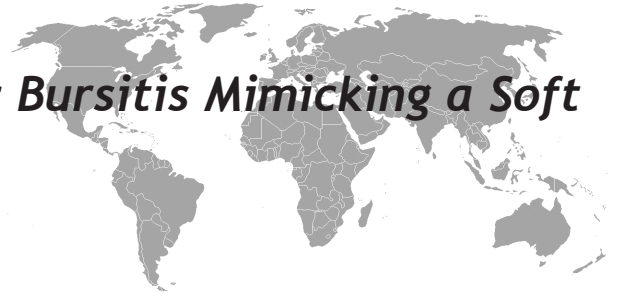

# An Unusual Klebsiella Septic Bursitis Mimicking a Soft Tissue Tumor



Mehmet Ali Acar<sup>1</sup>, Nazım Karalezli<sup>2</sup>, Ali Güleç<sup>3</sup>

## ABSTRACT

Because of its subcutaneous location prepatellar bursitis is frequently complicated by an infection. Gram-positive organisms, primarily *Staphylococcus aureus* account for the majority of cases of septic bursitis. Local cutaneous trauma can lead to direct inoculation of the bursa with normal skin flora in patients with occupations, such as mechanics, carpenters and farmers. A 71-year-old male was admitted to our department with a history of pain and swelling of his right knee over a 20 year period. Physical examination revealed a swollen, suppurative mass with ulceration of the skin and local erythema which mimicked a soft tissue tumor at first sight. Magnetic resonance imaging of the knee revealed a 13\*12\*10cm well-circumscribed, septated, capsulated, fluid-filled prepatellar bursa without evidence of tendinous or muscular invasion. The mass was excised en bloc, including the bursa and the overlying skin. The defect was closed with a split thickness skin graft. The patient had 100 degrees flexion and full extension after 45 days postoperatively, and he continued to work as a farmer.

**Key words:** *Klebsiella*, septic bursitis, haemorrhage, mass

## Yumuşak Doku Tümöre Benzeyen Nadir Klebsiella Septik Bursiti

### ÖZET

ilt altı yerleşiminden dolayı prepatellar bursitlerde enfeksiyon görülmesi sık olur. Gram pozitif mikroorganizmalar, özellikle *stafilokokkus aureus* en sık etkindir. Tamirciler, halıcılar ve çiftçiler gibi travmaya çok maruz kalan meslek gruplarında direk olarak etken cilt florasından bursaya ulaşabilir. 71 yaşında erkek hasta 20 yılı aşan ağrı ve şişlik nedeni ile kliniğimize başvurdu. Diz üstündeki eritemli, ülseratif ve akıntılı kitle ilk bakışta yumuşak doku tümörüne benziyordu. Manyetik Rezonans incelemede 13\*12\*10cm boyutlarında iyi sınırlı, septalı, kapsüle sıvı dolu prepatellar bursanın tendinöz veya kas invazyonu yoktu. Kitle üzerindeki cilt ile beraber çıkartıldı ve defekt kısmı kalınlıkta cilt grefti ile kapatıldı. Hastanın 45 gün sonraki kontrolünde 100 derece fleksiyonu ve tam ekstansiyonu vardı ve eski işini yapabiliyordu.

**Anahtar kelimeler:** *Klebsiella*, septik bursit, kanam, kitle

## INTRODUCTION

Septic bursitis is not common. Prepatellar and subcutaneous infrapatellar bursae are usually affected by bacterial infection because of their superficial location. Local cutaneous trauma can lead to direct inoculation of the bursae with normal skin flora. Some occupations are known to have increased risk factors for direct trauma, such as mechanics, carpenters and farmers. The main pathogen for septic bursitis is coagulase-negative staph-

*lococcus aureus*, which is responsible for around 80% of cases (1). The other reported pathogens are streptococcus species (Group A  $\beta$ -hemolytic streptococcus being the most common), *staphylococcus epidermidis*, *candida*, *escherichia coli*, *enterobacter*, *sporotrichosis* and *enterococcus faecalis* (1-4). MRI shows typical T1 and T2-weighted of fluid within the bursa. Chronic bursitis complicated by haemorrhage and calcification has a more complex and varied appearance on MR im-

<sup>1</sup>Beyhekim State Hospital, Department of Orthopaedic Surgery, <sup>2</sup>Red Crescent Special Hospital, Department of Orthopaedic Surgery <sup>3</sup>University of Selçuk, Meram Medical School, Department of Orthopaedic Surgery

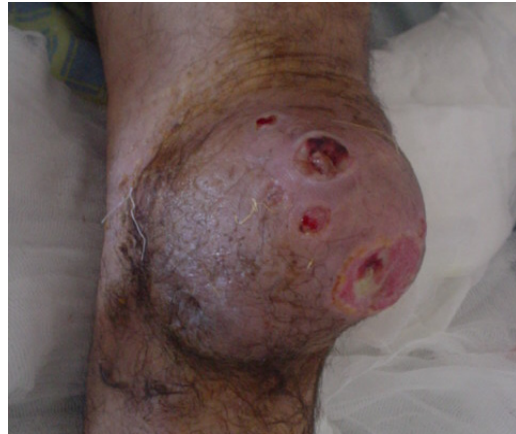Correspondence: Mehmet Ali ACAR  
Beyhekim Devlet Hastanesi Ortopedi ve Travmatoloji Bölümü Selçuklu - Konya-Turkey  
Tel: +90 332 2631237, Fax:+90 332 2631246  
E-mail: dr.mali46@hotmail.com

Received: 27.02.2011, Accepted: 20.04.2011

aging and makes it difficult to distinguish from other soft tissue masses such as a synovial sarcoma (5-9). We report a case of chronic complex septic bursitis due to *Staphylococcus aureus* and *Klebsiella*, located anterior to the knee, mimicking a soft tissue mass. To our knowledge *Klebsiella septic bursitis* has not been reported before.

## CASE

A 71 -year-old male was referred to our orthopaedic clinic with a history of pain and swelling of his right knee which had become progressively more uncomfortable and prominent over the past 20 years. He recalled that a horse bite had started the process. Physical examination revealed an ulcerating and local erythema, 13x12x10 cm, soft tissue mass arising anterior to the patella which mimicked a soft tissue tumour at first sight (Figure 1). The mass appeared to be adherent to deep tissue. He had 30-degree flexion of his right knee and walked with a tentative gait, limited by pain when trying to flex the knee. Several times over the course of 20 years the patient had punctured the lesion with a needle to decompress the cavity in order to feel comfortable. Complete blood count and serum chemistries were within the normal range. Erythrocyte sedimentation rate was 52 mm/hr. He was afebrile. An x-ray of the knee showed a large soft tissue mass arising in the subcutaneous tissue anterior to the patella of the right knee. Magnetic resonance imaging (MRI) of the knee demonstrated a soft tissue mass anterior to the patella. The lesion was isointense with muscle but had heterogeneous areas on T1-weighted, short T1 inversion recovery (Figure 2a). The patellar tendon was displaced posteriorly by the tumour mass. There was no osseous, muscular or tendinous invasion. Contrast enhanced images showed some peripheral and nodular enhancement at the margins of the prepatellar structure without evidence of septic arthritis or osteomyelitis, suggesting inflammatory change at the margins and central necrotic/cyst formation (Figure 2b). This encapsulated rounded mass was excised en bloc, including the bursa and the covering skin. Upon incision of the mass, a haemorrhagic and purulent material filling multilocated cavities was noted. The defect was closed with a split thickness skin graft (Figure 3). Culture from the synovial fluid yielded coagulase-negative *Staphylococcus aureus* and *Klebsiella*. No further evidence of infection was de-

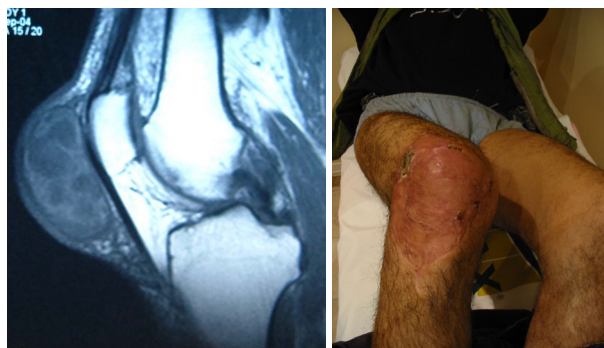

**Figure 1.** Appearance of the knee during the admission. The knee is and erythematic swelled with local ulceration.

tected postoperatively and the patient was discharged 10 days after the operation. The patient had 100 degree flexion and full extension after 45 days postoperatively, and he continued to work as a farmer.

## DISCUSSION

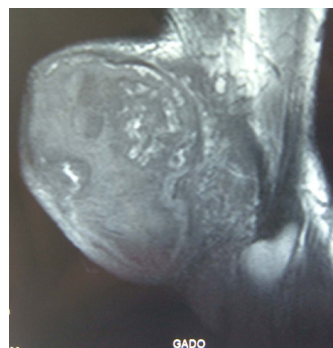
The prepatellar and the subcutaneous infrapatellar bursae are synovial-lined structures which are not connected to the knee joint. They minimize friction between the bone and patellar tendon. The prepatellar bursa is located between the patella and subcutis (10). Subcutaneous infrapatellar bursa is located around the insertion of the patellar ligament. The prepatellar and subcutaneous infrapatellar bursae are not usually visible on MR imaging, because they are collapsed and contain a small amount of fluid. When inflammation of these structures occurs they become oedematous and visible due to the increased water content (11-13). Fluid is demonstrated by low signal intensity on T1-weighted, and high signal intensity on T2-weighted images. Although simple bursitis has a well-defined capsule, the lesion in chronic bursitis can appear less well defined due to the inflammation of the surrounding tissues (11,13). Simple prepatellar bursitis, also known as housemaid's knee, is described as an excessive amount of fluid in the bursal space due to inflammation(10,14). and it is easily diagnosed clinically and by MRI with the typical T1 and T2-weighted of fluid within the bursa. Direct and repeated trauma can result in haemorrhagic bursitis (12). The appearance of haemorrhagic bursitis on MR imaging



**Figure 2a-2b.** Sagittal T-1 weighted MR image of the knee demonstrate an enlarged prepatellar bursa. After administration of intravenous contrast material demonstrates marked inflammatory change at the margins and central necrotic/cyst formation.

differs from that of simple bursitis. The more heterogeneous appearance on MR imaging is due to the constitution of blood and blood products, fluid and inflammatory changes. The authors are unaware of previous reports of septic bursitis associated with haemorrhagic bursitis in English language literature.

Synovial sarcoma is frequently found in close relationship to bursae, tendons and capsules of large joints (9). It is usually associated with pain and functional impairment of the related joint. On radiographs the lesion appears as a well defined round or lobulated soft tissue mass(6,7). The appearance of synovial sarcoma on MR imaging has been described as heterogeneous on T2-weighted imaging with both high and low signals and isointense to muscle on T1-weighted imaging with intermediate signals. High signals on T2-weighted images show a resemblance to haemorrhage and cysts(10,11). Synovial sarcoma may demonstrate a multilocular configuration with internal septation(15). The margins are often poorly defined or infiltrating, but may be well defined(15,16). In our case the size of the lesion, the heterogeneous appearance on MR imaging and the soft tissue oedema with apparent ulceration through the skin surface, was suspicious of a malignant process. Both human and animal bites have a high risk of infection but human bites are more dangerous since human oral flora is rich in aerobic and anaerobic micro-organisms(12,13). However, Klebsiella is not often encountered after either human or animal bites. In our reported case we do not know if Klebsiella was the main pathogen or had entered the lesion within the last 20 years during one



**Figure 3.** Appearance of the lesion 45 days after excision and skin grafting.

of the attempts to puncture the lesion with a needle. Chronic ulcerations may complicate to become squamous cell or basal cell carcinoma over a period of time (16). Pathologic examination of the lesion did not demonstrate carcinoma in our case. Although septic bursitis usually involves prepatellar and infrapatellar bursa, the duration and size of the lesion, the heterogeneous appearance on MR imaging and soft tissue oedema with apparent ulceration through the skin surface together with Klebsiella as a pathogen make the lesion interesting.

#### REFERENCES

1. Valeriano-Marcet J, Carter JD, Vasey FB. Soft tissue disease. *Rheum Dis Clin N Am* 2003;29(1):77-88.
2. Cea-Pereiro JC, Garcia-Meijide J, Mera-Varela A, Gomez-Reino J. A comparison between septic bursitis caused by staphylococcus aureus and those caused by other organism. *Clin Rheumatol* 2001;20(1):10-4.
3. Zimmerman B 3rd, Mikolich DJ, Ho G Jr. Septic bursitis. *Semin Arthritis Rheum* 1995;24:391-410.
4. Raddatz DA, Hoffman GS, Franck WA. Septic bursitis. Presentation, treatment and prognosis. *J Rheumatol* 1987;14(6):1160-3.
5. Canoso JJ, Sheckman PR. Septic subcutaneous bursitis: report of sixteen cases. *J Rheumatol* 1979;6(1):96-102.
6. Garcia-Porrúa C, Gonzalez-Gay MA, Ibanez D, Garcia-Pais MJ. The clinical spectrum of severe septic bursitis in Northwestern Spain: a 10 year study. *J Rheumatol* 1999; 26(3):663-7.
7. Roschmann RA, Bell CL. Septic bursitis in immunocompromised patients. *Am J Med* 1987;83(4):661-5.
8. Sepkowitz D, Maslow M, Farber M, Seleznick M, Walker R. Cryptococcal bursitis. *Ann Intern Med* 1988;108(1):154.

9. Soderquist B, Hedstrom SA. Predisposing factors, bacteriology and antibiotic therapy in 35 cases of septic bursitis. *Scand J Infect Dis* 1986;18(4):305-11.
10. Valverde J, Clavaguera MT, Perez A, Cabo X, Narvaez F, Juanola X. Septic bursitis predisposing factors, clinical and therapeutical features. *Br J Rheumatol* 1996;35(Supl 1):165.
11. Presutti RJ. Bite wounds early treatment and prophylaxis against infectious complications. *Postgrad Med* 1997;101(4):243-44.
12. Kelleher AT, Gordon SM: Management of bite wounds in primary care. *Cleve Clin J Med* 1997;64(3):137-41.
13. Bower MG. Managing dog, cat, and human bite wounds. *Nurse Pract* 2001;26(4):36-8.
14. Baldursson BT, Hedblad MA, Beitner H, Lindelof B . Squamous cell carcinoma complicating chronic venous leg ulceration: a study of the histopathology, course and survival in 25 patients. *Br J Dermatol* 1999;140(6):1148-52.
15. Mello LF, Barcelos MG, Meohas W, et al. Chronic ulceration of the leg following extensive scarring due to a snake bite complicated by squamous cell carcinoma. *Skeletal Radiol* 2000;29(5):298-301.
16. Phillips TJ, Salman SM, Rogers GS. Nonhealing leg ulcers: a manifestation of basal cell carcinoma *J Am Acad Dermatol* 1991;25(1 Pt 1):47-9.