

HYPERBARIC OXYGEN THERAPY IN CALCIUM CHLORIDE EXTRAVASATION INJURIES: AN EXPERIMENTAL ANIMAL STUDY

Seçil Aydınöz¹, Selami Süleymanoğlu¹, Aptullah Haholu², Günalp Uzun³, Ferhan Karademir¹, Şenol Yıldız³, İsmail Göçmen¹

Gulhane Military Medical Academy, Haydarpaşa Teaching Hospital, Departments of Pediatrics¹, Pathology², Undersea and Hyperbaric Medicine³, İstanbul, Turkey

Aim: Parenteral alimentation fluids containing calcium are widely used to treat sick neonates and children. Extravasation of calcium presents with local swelling, erythema, blistering and progresses to skin necrosis and skin loss. Several treatment modalities including hyperbaric oxygen therapy have been used for extravasation injuries. The role of hyperbaric oxygen therapy on extravasation injuries was investigated in this study by an experimental rat model based on facilitating effect of hyperbaric oxygen on wound healing.

Methods: After shaving the dorsal side of 16 female Wistar rats, 1 ml of calcium chloride were injected intradermally. The rats were divided into two groups as control and hyperbaric oxygen. The control group received no treatment while the hyperbaric oxygen group received hyperbaric oxygen therapy for 7 days after injection. At the end of seventh day skin biopsy including all necrotic tissue and surrounding healthy tissue were obtained and histopathologic examination was performed for control and hyperbaric oxygen groups.

Results: Hyperbaric oxygen group showed a statistically significant preservation of epidermis and dermis with minimal necrosing findings of skin injury.

Conclusion: Although further research is required to develop management guidelines, we concluded that in this experimental study, hyperbaric oxygen therapy prevents dermal injury and may decrease the morbidity associated with calcium chloride extravasation injury.

Key words: Extravasation injury, calcium, skin loss

Eur J Gen Med 2007;4(4):186-189

INTRODUCTION

Extravasation of intravenous fluids is a major cause of morbidity in pediatric population. Age is a risk factor for extravasation possibly due to need for smaller catheters and inability to communicate pain as an early warning sign. The prevalence of extravasation injuries resulting in skin necrosis recorded as 38 per 1000 neonates (1). Several factors play role in extravasation injuries including solution osmolality, tissue toxicity, vasoconstrictor properties, infusion pressure and regional anatomical peculiarity (2,3). Peripheral catheters are widely used in sick neonates and children. Variety of commonly used intravenous fluids have been shown to cause significant tissue damage such as antibiotics, chemotherapeutic agents, potassium, sodium bicarbonate, anticonvulsants and calcium (1,4).

Parenteral alimentation fluids containing calcium are widely used to treat sick neonates and children. Calcium chloride is commonly used in parenteral alimentation fluids and may cause local swelling, erythema, blistering and progresses to skin necrosis and skin loss(5). The most important part of extravasation injury is to prevent leakage of infused fluid into surrounding tissue, which may cause damage. The goals of treatment for this condition are early recognition and prevent scarring when extravasation occurs.

Treatment modalities of extravasation injuries include debridement and skin grafting, warm or cold compresses, saline flushout, multiple punctures, hyaluronidase, phentolamine, dapsone and hyperbaric oxygen (HBO) therapy (2,6-8). HBO therapy is a well-established model of medical treatment in which a patient breathes 100% oxygen in a

Correspondence: Secil Aydinoz, MD
GATA Haydarpaşa Teaching Hospital, Department of Pediatrics, Tibbiye Cd 34668 Uskudar İstanbul-Turkey
Phone: 902165422462, Fax : 902163487880
E-mail: saydinoz@gmail.com

Table 1. Histopathologic findings of skin injury

Histopathologic finding	Epidermis		Dermis		
	Ulceration	Fibropurulent exudate	Capillary necrosis	Granulation	Fat necrosis
Control (n=8)	7	8	7	8	8
HBO (n=8)	3	3	0	4	2
p	0,059	0,013	0,001	0,038	0,003

special chamber at 2-3 absolute atmospheres (ATA). HBO can institute a hyperoxic state by increasing dissolved oxygen in plasma even in tissues with hypoperfusion. This hyperoxic state promotes wound healing by neoangiogenesis, interfering with infection, fibroblast replication and collagen production. In this experimental study, we investigated the effect of hyperbaric oxygen therapy on calcium extravasation injuries in rats.

MATERIALS AND METHODS

Sixteen female Wistar rats weighing 160-200 g obtained from the Istanbul University Medical Faculty Experimental Research and Diagnosis Center were used in the study. Approval for the study was secured from Gulhane Military Medical Academy Hospital Ethical Committee. Animals were kept at room temperature in a natural day/night cycle and were permitted to eat standard rat chow and drink tap water ad libitum. Intradermal injections of 1 ml calcium chloride were made on the dorsal side of each rat after shaving the area of injection. The rats were randomly assigned to two groups. The control group (n=8) received no treatment. The hyperbaric oxygen (HBO) group (n:8) received HBO therapy for 60 min. at 2,5 ATA for 7 days after injection. At the end of seventh day skin biopsy including all necrotic tissue and surrounding healthy tissue were obtained and histopathologic examination was performed for control and HBO groups.

Biopsy specimens were fixed in buffered 10% formalin for 12 hours and then embedded in paraffin wax. Four-micron-thick sections were stained with PAS and haematoxylin and eosin (H&E). Histopathologic investigation was performed by a pathologist in a blind manner. Data were analyzed by Chi -square test and a value of $p < 0,05$ was considered statistically significant.

RESULTS

Calcium chloride injection resulted in consistent tissue necrosis, which continued to enlarge 5-7 days. Extension of the damage of calcium chloride through the dermis was assessed by histopathologic examination. Ulceration and fibropurulent exudates were seen after histopathologic examination of epidermis. Microscopic findings of dermis were capillary necrosis, granulation tissue formation and fat necrosis (Figure 1). HBO group showed a statistically significant preservation of epidermis and dermis with minimal necrosing findings of skin injury (Table 1).

DISCUSSION

Extravasation injuries resulted in skin necrosis is an important cause of morbidity in pediatric population. In this experimental rat model of skin injury, our data suggest that HBO may decrease the morbidity associated with calcium chloride extravasation injury. Although it is hard to identify risk factors for extravasation, age is considered the most significant one. Children, especially newborns are known to have more extravasations possibly due to need for smaller catheters and inability to communicate pain as an early warning sign.

Several treatment options have been proposed for extravasation injuries including both surgical and medical methods. Debridement and skin grafting to the area of skin loss have been reported as a successful surgical method in management of nine patients with extravasation injuries whose age ranged from 17 days to 60 years (9). Warm compresses provide a symptomatic relief by reabsorbing infiltrating solutions due to local vasodilatation. Maceration of the skin and subsequent necrosis have been reported as complications of this therapy (4). Yilmaz et al described a successful saline

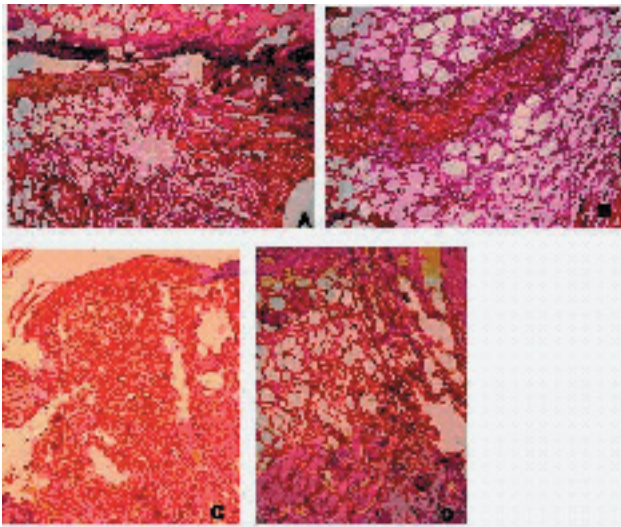


Figure 1. Ulcerated epidermis and seropürülan inflammatory base of the ulceration associated with fat necrosis, granulation tissue (A) and capillary necrosis (B) (Hematoxylen&Eosin, X100). Comparatively normal epidermis (C) and subepidermal minimal inflamatory reaction from HBO treated group (Hematoxylen&Eosin, X100).

flushout method in their experimental study in rats (10). In this technique a blunt-ended canula with side holes is used to inject saline (11). Chandavashu et al performed multiple punctures by using a sterile blood drawing stylet to make perforations over the area of swelling (12). Hyaluronidase is a protein enzyme derived from bovine testicular tissue extracts. It degrades hyaluronic acid which promotes an increase in tissue permeability and absorbtion of fluids through tissues. Successful treatment of extravasation injuries with injection of hyaluronidase have been reported both in experimental animal models and in neonates (13-15). Phentolamine is a nonspecific alpha adrenergic blocker which has been shown to decrease clinical erythema, induration and blanching by inhibiting vasoconstriction and allowing improved blood circulation through the extravasation site (16). The leukocyte inhibitor dapsone has been reported to have little positive effect on healing due to extravasation injury of doxorubicin in a rat model (7).

In our study extension of the damage of calcium chloride through the dermis was assessed by histopathologic examination and HBO group showed a statistically significant preservation of epidermis and dermis with minimal necrosing findings of skin injury. As far as we know, this is the first study investigating the effect of HBO on calcium extravasation injuries. Monstrey et al reported HBO therapy might be deleterious in the early stage of doxorubicin extravasation in an experimental study investigating the free radical tissue injury (6). However Aktas et al reported beneficial effect of HBO in adriamycin-induced skin lesions (17).

Although further research is required to develop management guidelines, we concluded that in this experimental study, HBO therapy prevents dermal injury of calcium chloride extravasation in rats.

REFERENCES

1. Wilkins CE, Emmerson AJ. Extravasation injuries on regional neonatal units. *Arch.Dis.Child Fetal Neonatal* Ed 2004;F274-F275
2. Lynch DJ, Key JC, White RR. Management and prevention of infiltration and extravasation injury. *Surg Clin North Am* 1979;939-49
3. Upton J, Mulliken JB, Murray JE. Major intravenous extravasation injuries. *Am J Surg* 1979;497-506
4. Brown AS, Hoelzer DJ, Piercy SA. Skin necrosis from extravasation of intravenous fluids in children. *Plast Reconstr Surg* 1979;145-50
5. Kumar RJ, Pegg SP, Kimble RM. Management of extravasation injuries. *ANZ J Surg* 2001;285-9
6. Monstrey SJ, Mullick P, Narayanan K, Ramasastry SS. Hyperbaric oxygen therapy and free radical production: an experimental study in doxorubicin (Adriamycin) extravasation injuries. *Ann Plast Surg* 1997;163-8
7. Sommer NZ, Bayati S, Neumeister M, Brown RE. Dapsone for the treatment of doxorubicin extravasation injury in the rat. *Plast Reconstr Surg* 2002;2000-5
8. Tiras U, Erdevé O, Karabulut AA, Dallar Y, Eksioğlu HM. Debridement via collagenase application in two neonates. *Pediatr Dermatol* 2005;472-5

9. Kumar RJ, Pegg SP, Kimble RM. Management of extravasation injuries ANZ J Surg 2001;285-9
10. Yilmaz M, Demirdover C, Mola F. Treatment options in extravasation injury: an experimental study in rats. Plast Reconstr Surg 2002;2418-23
11. Gault DT. Extravasation injuries. Br J Plast Surg 1993;91-6
12. Chandavasu O, Garrow E, Valda V, Alsheikh S, Dela VS. A new method for the prevention of skin sloughs and necrosis secondary to intravenous infiltration. Am J Perinatol 1986;4-5
13. Casanova D, Bardot J, Magalon G. Emergency treatment of accidental infusion leakage in the newborn: report of 14 cases. Br J Plast Surg 2001;396-9
14. Harris PA, Bradley S, Moss AL. Limiting the damage of iatrogenic extravasation injury in neonates. Plast Reconstr Surg 2001;893-4
15. Raszka WV, Jr., Kueser TK, Smith FR, Bass JW. The use of hyaluronidase in the treatment of intravenous extravasation injuries. J Perinatol 1990;146-9
16. Bey D, El Char GM, Bierman F, Valderrama E. The use of phentolamine in the prevention of dopamine-induced tissue extravasation. J Crit Care 1998;13-20
17. Aktas S, Toklu AS, Olgac V. Hyperbaric oxygen therapy in adriamycin extravasation: an experimental animal study. Ann Plast Surg 2000;167-71