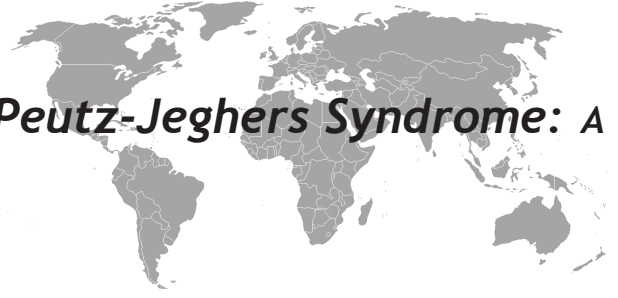


An Unusual Presentation of Peutz-Jeghers Syndrome: A Case of Recurrent Jejunal Intussusception



Tamer Sekmenli¹, Çağatay Evrim Afşarlar², Şule Bakır³

ABSTRACT

Epidemiologic studies show that sleep apnea increases risks for cardiovascular disease independently of individuals' demographic characteristics or risk markers i.e., smoking, alcohol, obesity, diabetes, dyslipidemia, atrial fibrillation, and hypertension. Individuals with severe sleep apnea are at increased risk for pulmonary arterial hypertension. The underlying mechanisms explaining associations between obstructive sleep apnea and pulmonary arterial hypertension are not entirely delineated. Several intermediary mechanisms might be involved including sustained sympathetic activation, intrathoracic pressure changes, and oxidative stress. Other abnormalities such as disorders in coagulation factors, endothelial damage, platelet activation, and increased inflammatory mediators might also play a role in the pathogenesis of pulmonary hypertension and cardiovascular disease. Linkage between obstructive sleep apnea and pulmonary arterial hypertension is corroborated by evidence that treatment of sleep apnea with continuous positive airway pressure reduces systolic blood pressure, improves left ventricular systolic function, and diminishes platelet activation. Several systematic studies are necessary to explicate complex associations between sleep apnea and pulmonary hypertension.

Key words: Peutz-Jeghers syndrome, recurrent intussusception, child

Peutz Jeghers Sendromunun Nadir Bir Görünümü: Tekrarlayan Jejunal İnvajinasyon

ÖZET

Peutz Jeghers sendromu (PJS) otozomal dominant, değişken kalıtmı, gastrointestinal sistemde özellikle ince barsaklarda hamartomatöz polipler ve pigmente mukokütanöz lezyonların görüldüğü ve jejunal invajinasyonun nadir görülen sebeplerinden birisi olan kalıtsal bir bozukluktur. Sunulan olgu alışıldık Peutz-Jeghers sendromundan; ince barsak polibinin invajinasyona yol açması sonrasında tanı alması ve mukokütanöz lezyonlarının olmaması ile farklılık göstermektedir. PJS otozomal dominant bir hastalık olmasına rağmen, olumsuz aile öyküsü olan hastalarda sporadik germline mutasyon olabileceğinden hastalar etkin bir şekilde tetkik edilmelidir. PJS'li hastalarda, multipl cerrahi işlemler ve tekrarlayan komplikasyonlar kısa barsak sendromu ve intestinal yapışıklıklara yol açabilir. Bu nedenle, tedavi yöntemleri minimal invaziv olmayı gerektirir; cerrahi ve endoskopik teknikler tamamlayıcı olarak yapılmalıdır.

Anahtar kelimeler: Peutz-Jeghers sendromu,tekrarlayan invajinasyon, çocuk

¹Diyarbakır Children's Hospital, Department of Pediatric Surgery, Diyarbakır, Turkey, ²Dr. Sami Ulus Children's Hospital, Department of Pediatric Surgery, Ankara, Turkey, ³Diyarbakır Public Hospital, Department of Pathology, Diyarbakır, Turkey

Correspondence: Tamer Sekmenli
Diyarbakır Çocuk Hastalıkları Hastanesi, Çocuk Cerrahisi Kliniği Kat:2 Diyarbakır
Tel: 904122245751-308, Fax: 904122290147
E-mail: dr_sekmenli@hotmail.com

INTRODUCTION

Ileocolic intussusception is one of the most common causes of intestinal obstruction in children aged 3 to 18 months. On the other hand, jejunal intussusception is an uncommon form of the disease. It has a tendency to occur in older children, has a more chronic course, and often has a demonstrable lesion as a lead point for the intussusceptions, and often presents with chronic abdominal pain and weight loss. Jejunal intussusception can be associated with inflammatory bowel disease, cystic fibrosis, polyposis syndromes, and enteric duplication or may have a proven cause. Peutz-Jeghers syndrome (PJS) is an inherited, autosomal dominant disorder with variable inheritance, characterized by hamartomatous polyps in the gastrointestinal tract, mostly in the small bowel, and pigmented mucocutaneous lesions and is one of the uncommon causes of recurrent jejunal intussusceptions (1).

We present a case that had a previous medical history of recurrent intussusceptions, severe anemia, and dramatically once investigated for an abdominal mass in a tertiary medical center, and in which the diagnosis of PJS was made by us following an intussusception caused by a small-bowel polyp.

CASE

A 9-year-old boy was admitted to our hospital with signs and symptoms of acute bowel obstruction. He was complaining of intermittent severe colicky abdominal pain with a history of three years, and bilious vomiting for the last three days. The medical history due to previous medical reports was significant for recurrent intussusception of small bowel and spontaneous reduction, severe anemia (Hb 5.5 mg/dL) which had been treated with oral iron preparations. Interestingly the patient was once investigated for an abdominal mass that had been resolved spontaneously in a tertiary medical center, when the first time he began to complain of abdominal pain.

Physical examination revealed severe abdominal distension and tenderness with a palpable abdominal mass at the site of umbilicus. His plain abdominal radiography was remarkable with sharp air/fluid levels. Blood count analysis indicated leukocytosis (white blood cell 18400/mm³), and anemia (Hb 9 mg/dL). Urine analysis and blood biochemistry were unremarkable. Ultrasonography of the abdomen revealed the typical "target sign" that confirmed the diagnosis of intussusception.

Subsequently laparotomy is justified. A jejuno-jejunal intussusception was found 90 cm distal to the ligament of Treitz (Figure 1). Intussusception is reduced with Hutchinson's maneuver and a polypoid mass in the jejunal lumen was seemed to be the leading point. The intussuscepting segment including the polyp was removed with small bowel resection, because of the poor circulation areas, and end-to-end anastomosis was performed. The postoperative course was uneventful. Histopathological examination of the specimen revealed a 3.5x3 cm of hamartomatous polyp compatible with Peutz-Jeghers syndrome (Figure 2). Although at the time of admission, in his physical examination we couldn't recognize any mucocutaneous pigmentation, after the histopathological intervention revealed PJS, a detailed dermatological examination was repeated, and any pigmented spots was identified. Also the family history was unremarkable for the PJS. His father, mother and also sibling sister aged six years old were asymptomatic. Consequently the patient and his family were referred to a tertiary medical center for further genetic and endoscopic investigations.

DISCUSSION

Peutz-Jeghers syndrome (PJS) is an inherited disorder characterized by hamartomatous polyps in the gastrointestinal tract and pigmented mucocutaneous lesions. It was first reported by Peutz in 1921, and the definitive clinical description of syndrome was written by Jeghers in 1949 (2). The prevalence of PJS differs between studies, estimated incidence has been noted from 1 in 8300 to 1 in 120000 births, and both sexes are almost equally effected (3). Inheritance of the syndrome is autosomal dominant with incomplete penetrance, with some cases arising from spontaneous mutations (4). Nowadays, the only identifiable genetic locus causing PJS appears to be mutations of the STK 11 gene (serine threonine kinase 11), which is a tumour suppressor gene located on band 19p13.3 (5). Mucocutaneous pigmentation caused by melanin aggregation is the characteristic finding of PJS and presented in 93% of PJS patients, but not all. Pigmented lesions are commonly seen on lips, perioral region, conjunctiva, nostrils and buccal mucosa; and sparsely on the fingers, soles of the feet, palms, anal area and intestinal mucosa (2). The patient reported also did not have any pigmented lesions, which is compatible with the incomplete penetrance, and the negative family history suspects a spontaneous or germline mutation of the gene.

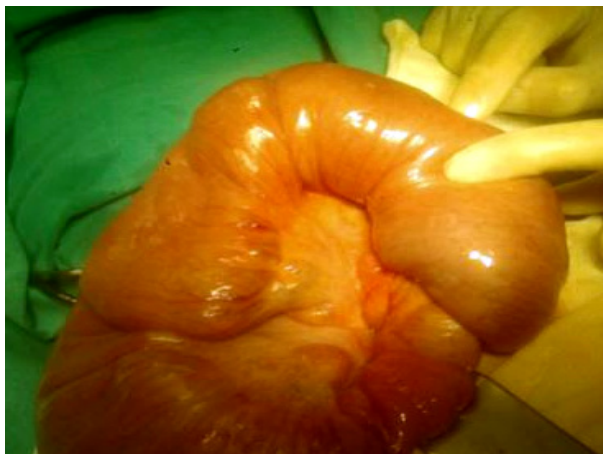

Figure 1. Operative finding of jejuno-jejunal intussusception

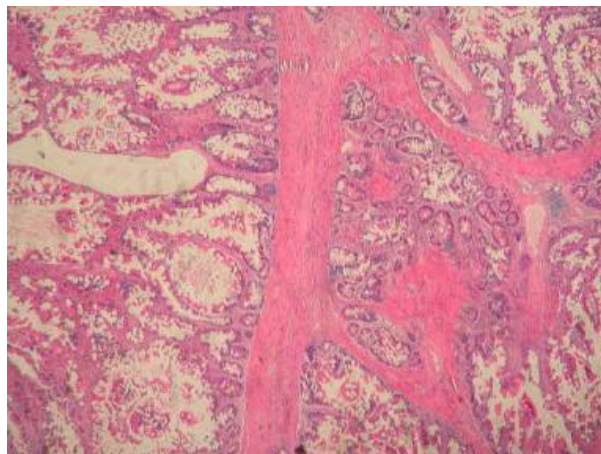


Figure 2. Peutz-Jeghers polyp has a central core of smooth muscle that shows tree like branching. This is covered by the mucosa native to the region, heaped to folds producing a villous, lack of atypia, disorganization of glands (hematoxylin and eosin X40).

Thus, genetic testing is suitable for confirmation of PJS. The predominant clinical features of PJS are the result of gastrointestinal polyposis. The polyps can be found in any part of the alimentary tract, but are mostly in the small bowel (jejunum>ileum>duodenum), followed by the colon and stomach (6). The histological features of PJS polyps are well documented. These polyps are hamartomatous and have specific configuration of smooth muscle cell branches covered by either normal or hyperplastic mucosa native to the involved site (7). Although, PJS polyps are most commonly found in the gastrointestinal system, they can occur in extraintestinal sites such as the kidney, ureter, gallbladder, bronchial tree, and nasal passages (8).

Patients with Peutz-Jeghers syndrome often present with a history of intermittent abdominal pain due to small bowel intussusception caused by the polyps. The size and site of the polyps shape the clinical course. Some intussusceptions spontaneously reduce. Others lead to development of small bowel obstruction. Peutz-Jeghers polyps can also ulcerate, leading to acute blood loss or chronic anemia (4). Although the patient's previous medical history and clinical presentation were compatible with PJS, because of the absence of mucocutaneous pigmentation we couldn't predict the diagnosis preoperatively. Patients with PJS are at an increased risk of developing cancerous lesions in and outside the gastrointestinal tract because

of the specific genetic mutations. Although the hamartomatous polyps are benign lesions, larger hamartomas often contain foci of adenomatous changes with respect to the year of age. Histological evidence of hamartomatous-adenomatous-carcinomatous evolution has been demonstrated for stomach, small bowel, and colorectal polyps in PJS. However, most associated malignancies occur outside the gastrointestinal tract and include lung, breast, uterus, gonads, prostate, thyroid, multiple myeloma, skin, and pancreas (3).

PJS patients require multiple emergency laparotomies and small bowel resections secondary to bleeding or obstruction by intestinal polyps, because recurrence is seen up to 10% of cases (6). Preservation of intestinal length is important not to cause short bowel syndrome. Thus the patients who have precise diagnose of PJS require a special respect at the time of surgery. The goal of treatment is to clear as much polyp as enough, and to avoid resections. Consequently, minimally invasive approaches are recommended and some of the authors advocate both the surgical and endoscopic techniques at the same session that is called "clean sweep" technique, in which the surgery team examines the whole intestinal tract with gastroduodenoscopy, enteroscopy, push endoscopy and remove/destroy the smaller polyps to achieve a polyp free intestinal mucosa. This technique reduces the further need for abdominal surgery and complications (7).

Also, laparoscopic techniques are commonly used as a minimally invasive approach that deals with the acute problem and may prevent adhesion formation.

Nowadays, double balloon enteroscopy (DBE) is a challenging method that allows examination and treatment of the jejunum and ileum, and reduces the need for further surgery. The system consists of a 200-cm enteroscope and 145-cm over-tube which have soft latex balloons at their tips. By using these balloons to grip the intestinal wall, the endoscope can be inserted further without forming redundant loops of intestine. But endoscopic techniques are not recommended for larger polyps, because of the risk of perforation and bleeding, and are not suitable for the sessile polyps either (2). Overall experiences indicate that these treatment methods should be considered complementary but not competitive for proper indications.

All PJS sufferers have to be enrolled for lifelong screening because of the high risk of intestinal and extra-intestinal malignancies. It is necessary to perform consistent screening for possible malignancies in all patients with PJS: colonoscopy, upper endoscopy, if possible wireless capsule endoscopy, CT, MRI or ultrasound of the pancreas, chest X-ray, mammography and pelvic examination with ultrasound in women, testicular examination in men, carbohydrate antigen 19-9 (CA-19-9), and cancer antigen (CA 125) (2). Hence PSJ is an uncommon genetic disorder with various genetic penetrations and clinical presentations, childhood small bowel intussusceptions should be searched vigorously. Thus the PJS patients are facing multiple emergency surgeries; both minimal invasive surgical and endoscopic techniques should be considered as treatment of choice. Close follow up and genetic consulting is essential.

REFERENCES

1. Ozgüner IF, Savaş C, Baykal B. Ileoileal invagination without obstruction in a four-year-old boy. *J Pediatr Surg* 2004;39(10):1595-6.
2. Kopacova M, Tacheci I, Rejchrt S, et al. Peutz-Jeghers syndrome: diagnostic and therapeutic approach. *World J Gastroenterol* 2009;15(43):5397-408.
3. McGarrity TJ, Kulin HE, Zaino RJ. Peutz-Jeghers syndrome. *Am J Gastroenterol* 2000;95(3):596-604.
4. Rufener SL, Koujok K, McKenna BJ, et al. Small bowel intussusception secondary to Peutz-Jeghers polyp. *Radiographics* 2008;28(1):284-8.
5. Jenne DE, Reimann H, Nezu J, et al. Peutz-Jeghers syndrome is caused by mutations in a novel serine threonine kinase. *Nat Genet* 1998;18(1):38-43.
6. Hasegawa S, Sekka T, Soeda J, et al. Laparoscopic treatment of intestinal intussusceptions in Peutz-Jeghers syndrome: case report and review of literature. *Tokai J Exp Clin Med* 2006;31(4):150-3.
7. Oncel M, Remzi FH, Church JM, et al. Benefits of 'clean sweep' in Peutz-Jeghers patients. *Colorectal Dis* 2004;6(5):332-5.
8. Latchford A, Greenhalf W, Vitone LJ, et al. Peutz-Jeghers syndrome and screening for pancreatic cancer. *Br J Surg* 2006;93(12):1446-55.