

Diagnosis of Stafne's Bone Cavity With Dental Computerized Tomography

Doğan Dolanmaz¹, Osman A. Etöz¹, A. Alper Pampu¹,
Erdem Kılıç¹, Yıldırım Şişman²

Selcuk¹, Erciyes² and Karadeniz Technique³ University, Faculty of Dentistry, Departments of Oral and Maxillofacial Surgery^{1,2,3} and Erciyes University, Faculty of Dentistry Oral Diagnosis and Radiology⁴, Konya¹, Kayseri^{2,3} and Trabzon³, Turkey.

Stafne's bone cavity (SBC) is asymptomatic radiolucent lesion of the lower jaw and generally seen incidentally during routine radiographic examinations. Diagnosis of this lesion is essential because of its similarity with other odontogenic pathologies. We present three cases of SBC which was firstly diagnosed with plain radiographs that were confirmed with dental computerized tomography. Asymptomatic radiolucent lesions of the mandible should be confirmed with advanced imaging techniques in order to avoid unnecessary surgery.

Key words: Stafne's bone cavity, dental computerized tomography

Eur J Gen Med 2009; 6(1):42-45

INTRODUCTION

Stafne's bone cavity (SBC) was first described by Stafne in 1942. He reported 35 asymptomatic unilateral radiolucent cavities in the posterior region of the mandible. Lesions were located between mandibular angle and the third molar, below the inferior dental canal and above the mandibular basis (1). Many different terms have been introduced like static bone cyst, lingual mandibular bone defect, idiopathic bone cavity and lingual mandibular bone depression in order to define the lesion (2,3). However the term SBC corresponds to the posterior lingual type which is the most frequent variant of the lesion (4). Anterior lingual type of the lesion is seen 7 times less frequent and usually located between the lower incisor and the premolar areas (5). SBC is generally encountered incidentally on routine plain radiographs and differential diagnosis includes odontogenic cyst and tumor like lesions (6). The aim of this paper was to present three case reports of SBC which were diagnosed with dental computerized tomography.

CASE 1

A 55 year-old male patient was referred to our clinic by his dentist with an asymptomatic radiolucent area which was detected incidentally during routine dental

examination. Panoramic radiograph revealed a unilateral well-defined unilocular radiolucent lesion on the right third molar region below the inferior alveolar canal slightly above the basis mandible (Figure 1A). Dental computerized tomography (DCT) scanning was performed to attain definitive diagnosis. Buccolingual images which revealed a lingual defect at the third molar tooth level, confirmed the final diagnosis of SBC (Figure 2A, C). Patient was informed about the lesion and scheduled for follow-up course. Approximately 4 months after the first appointment, no dimensional alterations were detected in DCT follow-up (Figure 2B, D).

CASE 2

A 58 year-old male patient applied to the department of prosthetic dentistry for dental management. The panoramic view of the patient exhibited a well-defined radiolucent area at the level of third molar on the left mandible which was located below the inferior alveolar canal (Figure 1B). The second left mandibular molar tooth was asymptomatic. The patient was informed about possible odontogenic pathologies and surgical interventions and referred to our clinic. We performed a DCT scan in order to achieve the definitive diagnosis of the lesion. DCT showed a lingual bone depression at the level of the left mandibular third molar region which revealed characteristic features of SBC (Figure 2A, B). Information was given about the lesion and the patient is still in the follow-up course.

Correspondence: Dr Etöz, Department of Oral and Maxillofacial Surgery, Erciyes Universitesi Dis Hekimligi Fakultesi Cerrahi Bolumu, 38039 Melikgazi, Kayseri, Turkey;

Fax: 903524380657, Phone: 903524374937

E-mail: osmanetoz@yahoo.com

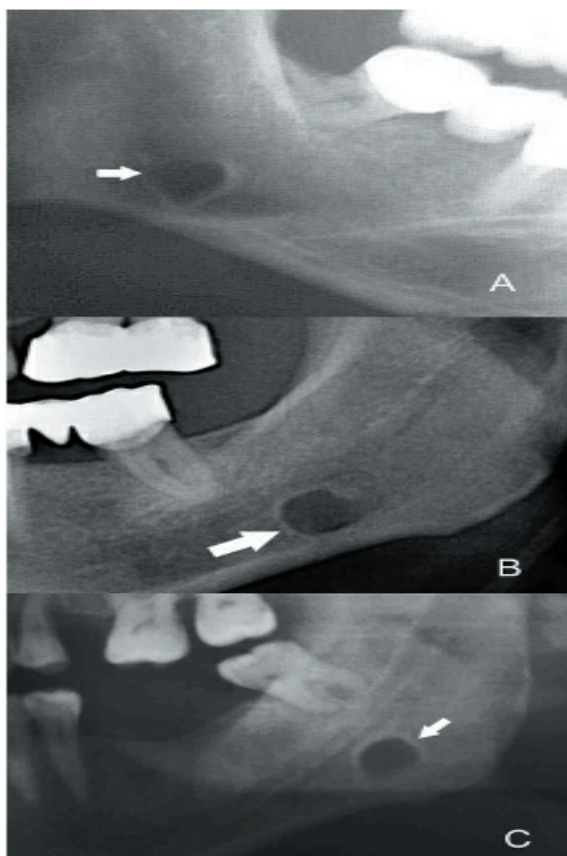


Figure 1. shows conventional panoramic views of the first (A), second (B) and the third (C) patients (white arrows indicate the lesions)

CASE 3

A 46 year-old male patient who were suffering from pain from the right side of his face submitted to our clinic. A well-defined radiolucent area in the left posterior region of the mandible below the inferior dental canal at the level of the third molar was seen on the panoramic view of the patient (Figure 1C). DCT scan revealed that the lesion exhibits typical features of SBC (Figure 3C, D). The patient was notified about the lesion and scheduled for follow-up.

DISCUSSION

SBC is frequently located in the posterior lingual region of the mandible. This common variant of SBC has a quite rare occurrence (0.1% - 0.48%) when diagnosed radiographically. However some cadaver studies revealed that the incidence of the lesion may increase up to 6.06% (2,3,7). This difference may be due to asymptomatic characteristic of the lesion. SBC usually occurs in 5. and 6. decades of life

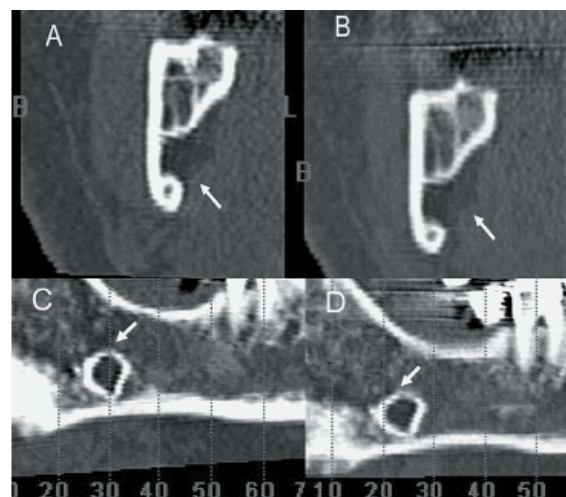


Figure 2. Shows coronal and panoramic sections of dental computerized tomography of the first patient on the first visit (A, C) and follow-up period (B, D). No changes were observed during follow-up (white arrows indicate the lesions)

and more common among males. Philipsen et al. in their comprehensive study, showed a 6: 1 male/female ratio for SBC (2). Gomez et al. also reported 11 cases of SBC in whom 8 were men (4). The patients in the present report were at the 5. decades of their lives and all of them were males.

Despite numerous theories regarding to the etiology of SBC, Stafne proposed the hypothesis that the lingual cavity was occupied by cartilaginous tissue due to bone deposition deficiency (1). On the other hand, the most widely accepted concept is pressure of the glandular tissue on the lingual cortex of the mandible (8). According to this concept submandibular salivary gland is responsible for the posterior lingual variant of the lesion while sublingual gland causes the anterior lingual variant (9). Hence, many investigators have found glandular tissue within the defect (4). Additionally Shibata et al. reported healing of the cavity after removal of the glandular tissue inside the lesion (10). Rare case reports have also been published regarding to muscular, lymphatic or vascular tissues related with the cavity (11,12).

SBC is generally encountered incidentally on routine plain radiographs and differential diagnosis includes odontogenic cyst and tumor like lesions (12). However conventional radiographs may be inadequate for recognition of the lesion and needed to be supported with additional diagnostic techniques. DCT,

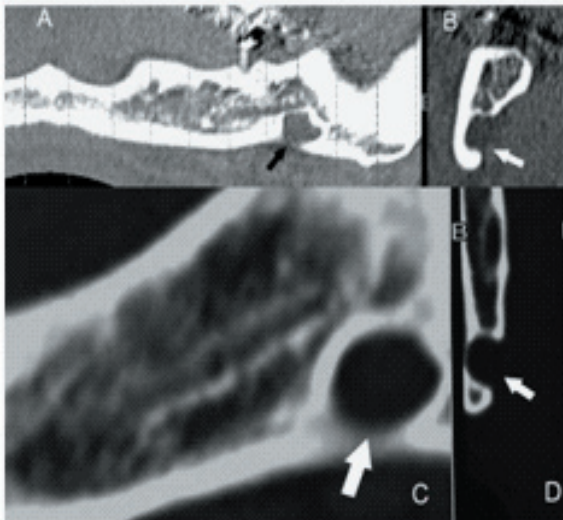


Figure 3 shows panoramic and coronal sections of dental computerized tomography views of the second (A, B) and the third (C, D) patients (arrows indicate the lesions).

Computerized tomography (CT), magnetic resonance imaging (MRI) and sialography techniques have been used to achieve final diagnosis of SBC. Gomez et al. proposed that CT is complementary diagnostic procedure for SBC and other cystic lesions could be distinguished with this method (4). Segev et al. declared that detection of SBC with CT is easier than MRI but they also mentioned that MRI should be considered in order to identify the content of the cavity (6). MRI is suggested for definitive diagnosis of SBC and reported to have less radiation exposure than CT (13). For CT images, larger cavities of SBC may be perceived smaller than they were and contents of cavities were uncertain (13). MRI has also some disadvantages like cost, discomfort to patient and possible image distortion.

Sialography is also a diagnostic technique to determine whether glandular tissue exists in the cavity. However this procedure is invasive and uncomfortable for patient (14). DCT procedure is reported as a noninvasive easy method (15). It allows definitive diagnosis and can be used in follow-up period. Thus, radiographic follow-up is recommended management for SBC instead of surgery (16).

In summary, the present report is probably the first in which asymptomatic bony defects were identified via DCT images. Lingual bone depression is evident in DCT which is the distinctive aspect of SBC. Thus DCT scans

provide detailed information about definitive diagnosis of SBC. Panoramic radiographs may ensure somewhat initial opinion regarding to the diagnosis of SBC for experienced practitioners and might be used for follow-up of SBC cases. Clinician should be aware of suspicious radiolucent lesions of the mandible and should apply multiple imaging modalities in order to avoid unnecessary surgery.

REFERENCES

1. Stafne E. Bone cavities situated near the angle of the mandible *J Am Dent Assoc* 1942;29: 1969-72
2. Philipsen H, Takata T, Reichart P, Sato S, Sueti Y. Lingual and buccal mandibular bone depressions: A review based on 583 cases from a world-wide literature survey, including 69 new cases from Japan *Dentomaxillofac Radiol* 2002;31:281-90
3. Slasky B, Bar-Ziv J. Lingual mandibular bony defects: CT in the buccolingual plane *J Comput Assist Tomogr* 1996;20:438-43
4. Quesada-Gomez C, Valmaseda-Castellon E, Berini-Aytes L, Gay-Escoda C. Stafne bone cavity: a retrospective study of 11 cases *Med Oral Patol Oral Cir Bucal* 2006;11:277-80
5. Barker G. A radiolucency of the ascending ramus of the mandible associated with investid parotid salivary gland material and analogous with a Stafne bone cavity *Br J Oral Maxillofac Surg* 1988;26:81-4
6. Segev Y, Puterman M, Bodner L. Stafne bone cavity - Magnetic resonance imaging *Med Oral Patol Oral Cir Bucal* 2006;11:345-7
7. Grellner T, Frost D, Brannon R. Lingual mandibular bone defect: Report of three cases *J Oral Maxillofac Surg* 1990;48:288-96
8. Tsui SH, Chan FF. Lingual mandibular bone defect: case report and review of the literature *Aust Dent J* 1994;39:368-71
9. de Courten A, Kuffer R, Samson J, Lombardi T. Anterior lingual mandibular salivary gland defect (Stafne defect) presenting as a residual cyst *Oral Surg Oral Med Oral Pathol Oral Radiol Endod* 2002;94:460-4
10. Shibata H, Yoshizawa N, Shibata T. Developmental lingual defect of the mandible: report of a case *Int J Oral Maxillofac Surg* 1991;20:328-9
11. Ariji E, Fujiwara N, Tabata O, et al. Stafne's bone cavity: Classification based on outline and content determined by computer tomography *Oral Surg Oral Med Oral Pathol* 1993;76:375-80
12. Barrer G. Xeroradiography in relation to a Stafne bone cavity *Br J Oral Maxillofac Surg* 1988;26:32-5
13. Branstetter BF, Weissman JL, Kaplan SB. Imaging of a Stafne Bone Cavity: What MR Adds and Why a New Name Is Needed. *Am J Neuroradiol* 1999;20:587-9
14. Oikarinen VJ, Wolf J, Julku M. A stereosialographic study of developmental

- mandibular bone defects (Stafne's idiopathic bone cavities) *Int J Oral Surg* 1975;4:51-4
15. Slasky BS, Bar-Ziv J. Lingual mandibular bony defects: CT in the buccolingual plane *J Comput Assist Tomogr* 1996;20:439-43
 16. Katz J, Chaushu G, Rotstein I. Stafne's Bone Cavity in the Anterior Mandible: A Possible Diagnostic Challenge *Journal Of Endodontics* 2001;27:304-7