

Diagnostic Accuracy of 0.2 Tesla Open MR Imaging Unit in Detecting Meniscal Tears: Correlation with Arthroscopy

Mustafa Koplay¹, Elif Aksakallı², Serdar Toker³, Seda Özbek¹, Ali Sami Kıvrak¹

¹Selcuk University, Selcuklu Medical Faculty, Department of Radiology Konya,

Dumlupınar University, Medical Faculty, Departments of Physical Medicine and Rehabilitation², and Orthopedics and Traumatology³, Kütahya, Turkey

Eur J Gen Med 2011;8(1):31-35

Received: 21.08.2010

Accepted: 08.09.2010

ABSTRACT

Aim: In the assessment of meniscal tears, diagnostic accuracy of 0.2 Tesla (T) magnetic resonance imaging (MRI) was investigated and compared with arthroscopy as standard of reference.

Method: 340 patients suspected with meniscal tears were examined by 0.2 Tesla open MRI unit. 47 of the patients underwent arthroscopy. The arthroscopy results were compared with interpretations of MRI retrospectively.

Result: In detecting meniscal tears with 0.2 T MRI, sensitivity, specificity and diagnostic accuracy were 90%, 88,2%, 89,4% for medial meniscal tears and 91%, 91,6%, 91,5% for lateral meniscal tears, respectively.

Conclusion: 0.2 T MRI is effective in detecting meniscal tears and can be safely use in detecting the meniscal pathologies.

Key words: MRI, meniscal tears, arthroscopy

Correspondence: Mustafa Koplay M.D.
Selcuk University, Selcuklu Medical Faculty
Department of Radiology, 42100 Konya,
Turkey
Tlf: 90-332 2415000- 41134
E-mail: koplaymustafa@hotmail.com

0.2 Tesla Açık MR Ünitesinin Menisküs Yırtıklarının Saptamada Tanı Doğruluğu: Artroskopik ile Korelasyon

Amaç: Menisküs yırtıklarının değerlendirilmesinde 0.2 Tesla (T) manyetik rezonans görüntülemenin (MRG) tanısallık doğruluğu araştırıldı ve standart referans olarak artroskopi ile karşılaştırıldı.

Metod: Menisküs yırtığı şüphesi olan 340 hasta 0.2 T açık MRG cihazı ile incelendi. 47 hasta artroskopi ile değerlendirildi. Retrospektif olarak artroskopi ve MRG sonuçları karşılaştırıldı.

Bulgular: Menisküs yırtıklarının tespitinde 0.2 T MRG'nin sensitivite, spesifite ve tanısallık oranları medial menisküs için sırasıyla %90, %88,2 ve %89,4, lateral menisküs için %91, %91,6 ve %91,5 bulundu.

Sonuç: 0.2 T MRG, menisküs yırtıklarının tespitinde etkindir ve menisküs patolojilerinin tespitinde güvenli bir şekilde kullanılabilir.

Anahtar kelimeler: MRI, meniscal tears, arthroscopy

INTRODUCTION

Magnetic resonance imaging (MRI) is a non-invasive and reliable diagnostic tool in detecting meniscal tears (1). As low field MRI systems have better magnet homogeneity and lower costs compared to high field MRI, their use have been common (2). However, signal-to-noise ratio is better and scan times are shorter with 1.5 Tesla (T) system, also grade 1 meniscal degeneration is better visualized on images, that were acquired by 1.5 T MR units. Low field MRI systems have some disadvantages such as longer scanning time, lower signal-to-noise ratio, lower spatial resolution and the inability to obtain thin slices. (2). There are different reports about the diagnostic performances of low-field-strength MR systems. In this study, we aimed to investigate as retrospective the diagnostic accuracy of 0.2 T MRI in detecting meniscal tears.

MATERIALS AND METHODS

Patients

Patients from the orthopedic and the physical-rehabilitation department were enrolled in this study. 340 patients (150 men and 190 women; mean age: 48.6±8.5, age range 17- 75 years) clinically suspected with internal derangements of the knee had undergone MRI examination the between September 2008 and June 2009. In our study, we assessed 47 patients whose arthroscopy results were known. Their MRI results were scanned retrospectively. Persistent pain despite medication and physical therapy, locking and instability were the criteria for arthroscopy. The time interval between MRI and arthroscopy was usually less than 1 weeks.

MR techniques

Imaging was performed on a 0.2 T open MRI unit (Siemens Magnetom Concerto, Erlangen, Germany). Our routine

knee sequences were; T1 weighted spin-echo sagittal (SE; TR: 912 ms, TE: 26 ms, FOV: 233), T2 weighted turbo-SE coronal (TSE; TR: 3280 ms, TE: 109 ms, FOV: 230) and proton density (PD)-TSE- fat saturation (FS)-sagittal (TR: 4370 ms, TE: 31 ms, FOV: 260). Special knee coil with 4 mm thickness in all sequence was used.

Imaging analysis

All subjects were assessed for meniscopathy and other pathologies of the knee. All meniscal degenerations were classified into three degrees by one radiologist and all arthroscopic procedures were performed by one orthopaedic surgeon. Nonarticular, focal or globular increased signal intensity within the meniscal substance was determined as Grade 1. Horizontal, linear increased signal intensity within the meniscal substance that doesn't extend to joint surface was defined as Grade 2. Increased signal intensity that communicates or extends to at least one articular surface of the meniscus was determined as Grade 3 degeneration (meniscal tear) (3). Linear meniscal tears were graded as 3A, parted meniscal tears were graded as 3B. The grade of meniscus degenerations were noted during the arthroscopy. The results of arthroscopy and MRI examination were compared.

Statistical Analysis

Statistical analysis was performed using the arthroscopic findings as the reference standard, the presence or absence of degeneration (tear) at meniscus site was evaluated on the arthroscopy. We calculated the sensitivity, specificity, positive predictive values (PPV), and negative predictive values (NPV), and diagnostic accuracy of 0.2 T MRI. If a tear was detected on both MRI and arthroscopy, the patient was counted as a true-positive. When tears were not detected with either diagnostic method, we considered patients as true-negatives. If a

Table 1. The distribution of meniscal degenerations detected with MRI

	Medial meniscal degenerations n (%)	Lateral meniscal degenerations n (%)	Total cases n (%)
Grade 1	62 (18,2)	8 (2,4)	70 (20,6)
Grade 2	57 (16,7)	38 (11,2)	95 (27,9)
Grade 3	84 (24,7)	48 (14,1)	132 (38,8)
Normal	-	-	43 (12,6)

tear was detected by MRI but not detected by arthroscopy, the patient was counted as a false-positive. If the opposite findings were recorded, the patient was counted as a false-negative.

RESULTS

According to MRI results, grade 1 meniscal degeneration was detected in 20,6 % of 340 patients (n: 70), grade 2 and 3 degeneration was detected in 27,9 % (n: 95) and 38,8 % (n: 132) of the patients respectively (Figure 1, 2). There was no meniscal pathology in 43 patients. Medial and lateral meniscal degenerations detected with MRI are summarised in Table 1. Arthroscopy detected medial meniscal tears in 30 patients (63.8 %) and lateral meniscal tears in 11 patients (23.4 %). In detecting meniscal tears with MRI sensitivity was 90%, specificity was 88,2%, diagnostic accuracy was 89,4 % for medial meniscus, sensitivity was 91 %, specificity was 91,6 %, diagnostic accuracy was 91,5% for lateral meniscus. Our findings are similar with the ratios obtained from studies with high tesla (1 ve 1.5 T) MRI units (4- 6). Sensitivity, specificity, positive predictive values (PPV), and negative predictive values (NPV), and diagnostic accuracy of 0.2 Tesla MRI unit in detecting medial and lateral meniscal tears are summarised in Table 2. We also detected with MRI the other pathologies such as synovial effusion, patellar tendinitis, anterior cruciate ligament rupture, Baker's cyst, loose bodies, medial and lateral collateral ligament rupture, arthritis and bone tumors

DISCUSSION

In the literature the diagnostic accuracy of low Tesla MRI units is controversial. In a multi-center study of Fischer et al, MR examinations of 1014 patients were performed with different magnetic units, the diagnosis was subsequently confirmed arthroscopically (7). Increased accuracy was related with the strength of the magnetic field. Rand et al performed MRI in 25 patients with both high and low field units, seven of the patients underwent arthroscopy. The authors suggested that qualitative evaluation of the level of confidence for diagnosing meniscal tears was significantly superior with high field strength imaging (8). Kinnunen et al. performed 0.1T MRI examination and subsequent arthroscopy in 33 patients, the performance of low field MRI was similar with high field MRI sensitivity and specificity, except for lateral meniscus lesions with a specificity of only 25% (9). Parizel et al compared MR imaging of 10 subjects obtained with both 0.2T and 1.5T units, they reported that image quality and diagnostic performance of 0.2 and 1.5T units were equivalent (2). Kladny et al examined 22 patients with both 0.2T and 1.5T units and compared the results with intraoperative findings, they suggested both of the systems were reliable in diagnosing meniscal tears and anterior cruciate ligament ruptures (10).

These different results may be caused by the methodological and technical differences in the MR protocols and the size of patient population. The experience of

Table 2. MRI findings correlated with arthroscopy in meniscal tears

	Medial Meniscus	Lateral Meniscus
Sensitivity (%)	90	91
Specificity (%)	88,2	91,6
Positive predictive value (%)	93,1	77
Negative predictive value (%)	83,3	97
Diagnostic accuracy (%)	89,4	91,5

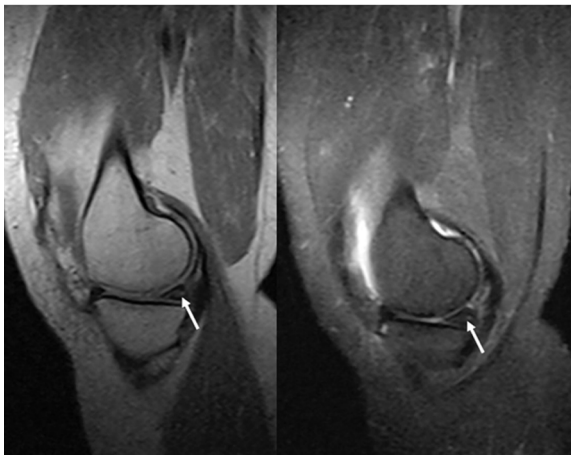


Figure 1. Grade 3 degeneration (horizontal tear) is seen on posterior horn of medial meniscus.

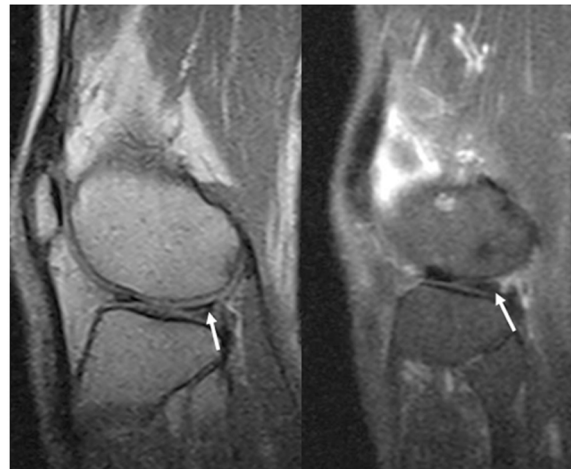


Figure 2. Grade 3 degeneration (oblique tear) is seen on posterior horn of lateral meniscus.

arthroscopists and radiologists may also reveal different results (11). Krampla et al reviewed fifty-two MRI studies and analysed inter-observer reliability in the interpretation of meniscal lesions, degree of chondropathy and integrity of the ACL. The findings were compared with intra-operative findings. Inter-observer correlation was low and radiologist experience was found to be more important than field strength (12).

There are some limitations of our study. The second imaging procedure with a high field MRI was not performed. We only compared arthroscopy findings and 0.2 T MRI results retrospectively. Although 340 patients underwent MRI examination, we could only compare the results of 47 patients. The number of patients undergone arthroscopy is limited. Because of the ethical reasons we didn't plan arthroscopy for the patients who showed improvement with medication and physical therapy. However, some of the patients did not accept the arthroscopic examination.

In detecting meniscal tears, trials comparing arthroscopy and MRI revealed that diagnostic accuracy of MRI was 87- 93 % for lateral meniscus and 88-92 % for medial meniscus (4-6). In our study, diagnostic accuracy was 89,4 % for medial meniscus and 91,5% for lateral meniscus. According to our results low field MRI is as effective as high field MRI in detecting meniscal tears. Many of the studies were made in the late 90's and the technology used in the MRI units are changed by the time.

Although there are studies assuming that low field MRI is not as effective as high field MRI in diagnosing meniscal pathologies, the improvements in technology and the experience with the low field MRI units increased the diagnostic accuracy rates.

In conclusion, low field MRI units as 0.2 T is effective in detecting meniscal tears and can be safely use in detecting the meniscal pathologies. Additionally, as they are open they are preferred for claustrophobic and obese patients. We believe that as the technology improves the image quality and diagnostic accuracy of low field MRI will increase.

REFERENCES

1. Chang CY, Wu HT, Huang TF, Ma HL, Hung SC. Imaging evaluation of meniscal injury of the knee joint: a comparative MR imaging and arthroscopic study. *Clin Imaging* 2004;28:372-6.
2. Parizel PM, Dijkstra HA, Geenen GP, et al. Low-field versus high-field MR imaging of the knee: a comparison of signal behaviour and diagnostic performance. *Eur J Radiol* 1995;19:132-8.
3. Stoller DW, *Knee, 1st ed*, in: Stoller DW, Tirman PF, Bredaella MA, Beltran S, Branstetter RM, Blease SC (Eds.), *Diagnostic Imagig Orthopaedics*, Amirsys Publishing Company, Canada, 2006; 5-2-41.
4. Cevikol C, Karaali K, Esen G, et al. MR imaging of meniscal tears at low-field (0.35 T) and high-field (1.5 T) MRI units. *Tani Girisim Radyol* 2004;10; 316-19.

5. Quinn SF, Brown TR, Szumowski J. Menisci of the knee: radial MR imaging correlated with arthroscopy in 259 patients. *Radiology* 1992;185:577-80.
6. Rubin DA. MR imaging of the knee menisci. *Radiol Clin North Am* 1997;35:21-44.
7. Fischer SP, Fox JM, Del Pizzo W, Friedman MJ, Snyder SJ, Ferkel RD. Accuracy of diagnoses from magnetic resonance imaging of the knee. A multi-center analysis of one thousand and fourteen patients. *J Bone Joint Surg Am* 1991;73:2-10.
8. Rand T, Imhof H, Turetschek K, et al. Comparison of low field (0.2T) and high field (1.5T) MR imaging in the differentiation of torned from intact menisci. *Eur J Radiol* 1999;30:22-7.
9. Kinnunen J, Bondestam S, Kivioja A, et al. Diagnostic performance of low field MRI in acute knee injuries. *Magn Reson Imaging* 1994;12:1155-60.
10. Kladny B, Glückert K, Swoboda B, Beyer W, Weseloh G. Comparison of low-field (0.2Tesla) and high-field (1.5 Tesla) magnetic resonance imaging of the knee joint. *Arch Orthop Trauma Surg* 1995;114:281-6.
11. Cotten A, Delfaut E, Demondion X, et al. MR imaging of the knee at 0.2 and 1.5 T: correlation with surgery. *AJR Am J Roentgenol* 2000;174:1093-7
12. Krampla W, Roesel M, Svoboda K, Nachbagauer A, Gschwantler M, Hruby W. MRI of the knee: how do field strength and radiologist's experience influence diagnostic accuracy and interobserver correlation in assessing chondral and meniscal lesions and the integrity of the anterior cruciate ligament? *Eur Radiol* 2009;19:1519-28.