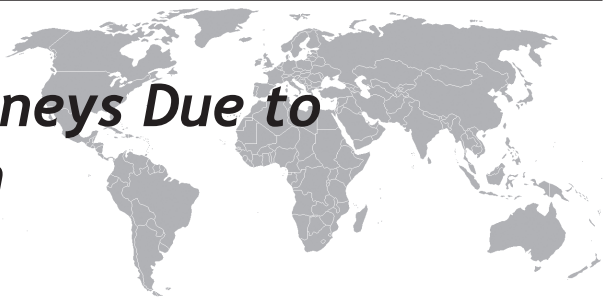

# Massively Enlarged Kidneys Due to Leukemic Infiltration in a Child



Murat Doğan<sup>1</sup>, Ali Bay<sup>2</sup>, Aydın Bora<sup>3</sup>, Mehmet Açıkgöz<sup>1</sup>, Ahmet F. Öner<sup>2</sup>

Yuzuncu Yil University, School of Medicine, Departments of Pediatrics<sup>1</sup>, Pediatric Hematology<sup>2</sup> and Radiology<sup>3</sup>, Van, Turkey

Eur J Gen Med 2010;7(1):114-117

## ABSTRACT

A few cases with bilateral renal enlargement in acute lymphoblastic leukemia were reported in literature. In this article, we reported an unusual case of a child with precursor B-ALL presenting with massively enlarged bilateral unobstructed kidneys and acute renal failure. Renal involvement of ALL should be taken into consideration in case with massively enlarged bilateral kidneys in radiological examination. Based on radiological, clinical and laboratory findings including bone marrow aspirate examination, the patient could be diagnosed as ALL without renal biopsy.

**Key words:** Acute lymphoblastic leukemia, bilateral kidney enlargement, renal failure, diagnosis

## INTRODUCTION

Acute lymphoblastic leukemia (ALL) is the most common malignancy in children, representing nearly one third of all pediatric cancers. Although a small percentage of cases are associated with inherited genetic syndromes, the cause of ALL remains largely unknown (1). The precursor B-cell form accounted for 80 % of all acute lymphoblastic leukemia (2). In most of B-ALL patients present with anemia, neutropenia, bone pain, and arthralgia. Acute renal failure (ARF) and nephromegaly, lymphomatous infiltration of the kidneys, are very rare manifestations of ALL in children (3, 4). In this article, we reported an unusual case of a boy with precursor B-ALL presenting with massively enlarged bilateral unobstructed kidneys and ARF.

## CASE

A 14 year-old boy with severe anemia was referred to our hospital. He had been suffered from generalized muscle pain, headache, paleness, and weight loss for the last 30 days. The diagnosis of iron deficiency anemia had established at another hospital and oral iron treatment had been started.

**Correspondence:** Murat Doğan MD, Hafiziye Mahallesi, K.Karabekir Caddesi, Araştırma Hastanesi Arkası, Uğur Sitesi D blok 4. kat No: 9, 65100 Van/ Turkey, Tel:+905065871817, Fax:+904322158160, E-mail: doganmurat.md@gmail.com

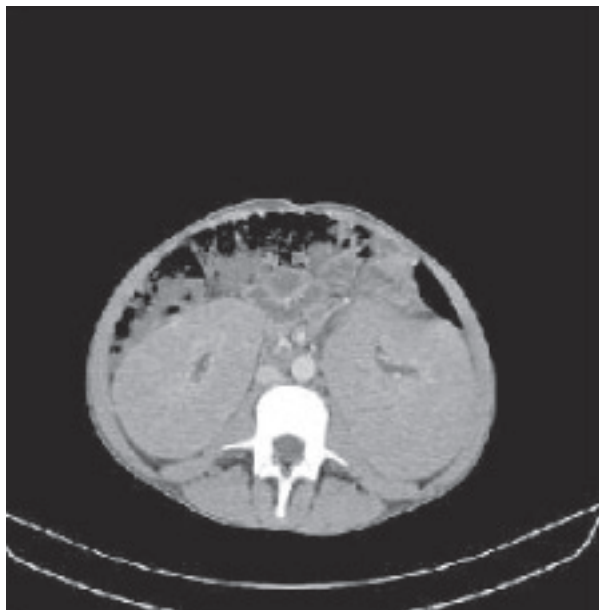

Figure 1. Computed tomographical examination revealed bilateral diffuse renal enlargement without any functional abnormality. There was no detectable focal lesion in the both kidney.

Because there was no response to iron supplementation on the 15th day of the treatment, the patient has referred to our hospital. He had a significant pallor, tachycardia (130/min) and a few petechiae eruptions on the lower extremities. His blood pressure was 130/80 mmHg. He had an enlarged liver and spleen both palpable 5 cm below the costal margin at the midclavicular line. The kidneys were bilaterally palpated as two solid tumor masses with smooth surface engaging the whole abdomen. There was no evidence of lymphadenopathy. The results of the complete blood count were as follows: hemoglobin 2.9 g/dl, mean corpuscular volume (MCV): 62 fl, white blood cell count  $4.2 \times 10^9/l$ , and platelet count  $60 \times 10^9/l$ . A peripheral blood smear revealed 80% lymphocyte, 2% monocyte and 18% neutrophil with inadequate platelets. Urine microscopy revealed no haematuria and there was no detectable proteinuria. Serum biochemistry, coagulation parameters (prothrombin time, activated partial thromboplastin time and fibrinogen level), vitamin B12, and folic acid levels were in the normal range except for elevated serum creatinine (1.4 mg/dl), uric acid (12 mg/dl), LDH (1100 U/L) levels. These elevated values returned to normal ranges after the treatment following anti-cancer chemotherapy (serum creatinine: 0.9 mg/dl, uric acid: 3.3 mg/dl, LDH: 514 U/L). Serological tests

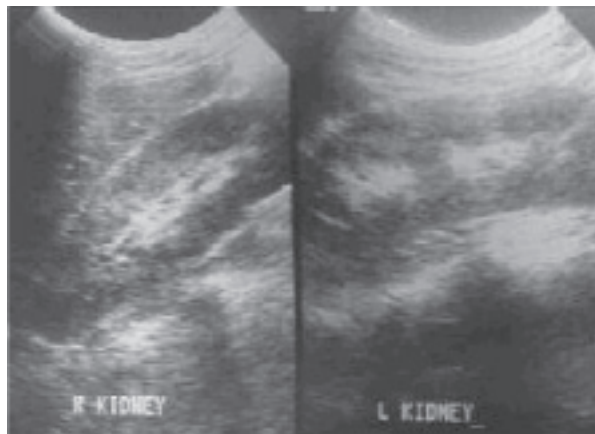


Figure 2. Abdominal ultrasound showed a progressive reduction in size of both kidneys at 3rd weeks after the initial diagnosis.

including EBV, CMV, HIV, rubella, parvovirus, and hepatitis B virus antibodies were found to be negative. In computed tomography (CT) examination, massively enlarged bilateral unobstructed kidneys with normal shape was revealed which was strongly suggested an infiltrative process (Figure 1). There was no other abnormal CT finding in abdomen and thorax except moderate hepatosplenomegaly. Examination of the bone marrow aspiration showed 95% blast cells that were characteristic of ALL, L1 type morphology. Immunophenotypic analysis of the bone marrow aspirate showed that the blast population consisted of predominately of CD10 and CD19, consistent with PreB cell acute lymphoblastic leukemia. Based on these findings, acute lymphoblastic leukemia (ALL) concomitant with acute renal failure was diagnosed. After red blood cell transfusion, chemotherapy against ALL was started. He received chemotherapy according to the previously described ALL BFM 2000 protocol.

In general, compliance with chemotherapy was good, with no major delays or reductions in dosage. Renal failure resolved within 3 days after the start of chemotherapy. Abdominal ultrasonography (US) was repeated at 3 weeks after the initial diagnosis and a progressive reduction on the kidney dimensions was observed (Figure 2). During the follow up period of 2 months, he had been in remission and continued to receive chemotherapy for ALL.

## DISCUSSION

Precursor B-cell acute lymphoblastic leukemia is defined as a neoplasm of lymphoblasts committed to the B-cell lineage, typically composed of small-to medium sized blast cells with scant cytoplasm, moderately condensed to dispersed chromatin and inconspicuous nucleoli (5). The disease involves bone marrow and blood. In our case, we suspected the leukemia because of the common clinical feature of ALL such as anemia, thrombocytopenia and fatigue. Therefore, peripheral blood smear and bone marrow aspiration were performed in the patient.

Although no blast was seen in peripheral blood smear, in bone marrow examination 95% lymphoblast had characteristic features of ALL, L1 type morphology. Although renal involvement is not uncommon, only a few cases of renal failure secondary to a diffuse bilateral parenchymal infiltration have been reported in the literature. Tumor infiltration into the kidneys can occur via hematogenous route. This infiltration of tumor cells into the kidneys is usually associated with evidence of malignancy elsewhere as identified by physical examination, imaging studies, and examination of the peripheral smear or bone marrow (4,6-9).

The development of acute renal failure in patients with hematological malignancies can present a major clinical problem, and generally develops as a direct invasion of the hematological malignant cells, e.g. obstruction of the ureters, or renal artery or vein thrombosis. Other more indirect causes of renal failure include hyperuricemia, sepsis, hemolysis, and paraproteinemia with deposits of paraprotein. Cryoglobulinemia, amyloid formation, nephrosis or nephritis may also be encountered (10). Our patient had nephromegaly and hematologic abnormalities on admission. So he was examined about the cause of nephromegaly. Peripheral blood smear examination was normal but 95% blast cells that were characteristic of ALL, L1 type morphology were found on the bone marrow examination. In addition of this, abdominal CT showed the tumoral infiltration of the kidneys.

Bilateral cellular infiltration of the renal interstitium may be seen in hematological malignancies. Ultrasound and CT are the main imaging modalities suggesting the search for any cellular infiltration within the renal parenchyma. In most cases, the US findings in leukemia or lymphoma include renal enlargement and diffuse or focal areas of homogenous hypoechogenicity (11-13). In our patient, the US and CT image of both kidneys impressed by their dimensions and by the thickness

of parenchyma, which significantly exceeded the age reference values. Renal failure resolved within 3 days after the start of chemotherapy. Abdominal US was repeated at 3 weeks after the initial diagnosis and a progressive reduction on the kidney dimensions was observed.

Renal biopsy is not indicated in cases which are suspected the hematopoietic malignancy presenting with renal insufficiency. Standard procedures (physical exam, radiographic studies, and examination of the peripheral smear or bone marrow.) firstly should be performed to explain the etiology. When these procedures do not show the cause of ARF and nephromegaly, a renal biopsy is mandatory for rapid diagnosis and therapy (14). In our case we followed these suggestions.

As a conclusion, a few cases with bilateral renal enlargement in ALL were reported in literature. Renal involvement of ALL should be taken into consideration in case massively enlarged bilateral kidneys in radiologic examination. Based on radiological, clinical and laboratory data including bone aspirate examination, the patient can be diagnosed without renal biopsy.

## REFERENCES

1. Sinnott D, Labuda D, Krajcinovic M . *Challenges Identifying Genetic Determinants of Pediatric Cancers - the Childhood Leukemia Experience. Fam Cancer* 2006;5:35-47.
2. Feltbower RG, Moorman AV, Dovey G, Kinsey SE, McKinney PA. *Incidence of childhood acute lymphoblastic leukaemia in Yorkshire, UK. Lancet* 2001;358:385-87.
3. Han BK, Babcock DS. *Sonographic measurements and appearance of normal kidneys in children. AJR* 1985;145:611-16.
4. Richmond J, Sherman RS, Diamond HD, Craver LF. *Renal lesions associated with malignant lymphomas. Am J Med* 1962;32:184-207.
5. Brunning RD, Borovitz M, Matutes E, et al. *Precursor B lymphoblastic leukaemia/lymphoblastic lymphoma (precursor B-cell acute lymphoblastic leukaemia). In: Jaffe ES, Harris NL, Stein H, Vardiman JV (eds): Pathology and genetics of tumors of haematopoietic and lymphoid tissues. WHO classification tumours of haematopoietic and lymphoid tissue. IARC Press, Lyon, 2001, p 111*
6. Ellman L, Davis J, Lichtenstein NS. *Uremia due to occult lymphomatous infiltration of the kidneys. Cancer*

- 1974;33:203-05.
7. Kanfer A, Vandewalle A, Morel-Maroger L et al. Acute renal insufficiency due to lymphomatous infiltration of the kidneys. *Cancer* 1976;38:2588-92.
  8. Randolph VL, Hall W, Bramson W. Renal failure due to lymphomatous infiltration of the kidneys. *Cancer* 1983;52:1120-21.
  9. Glicklich D, Sung MW, Frey M. Renal failure due to lymphomatous infiltration of the kidneys. Report of three new cases and review of the literature. *Cancer* 1986;58:748-53.
  10. Da'as N, Polliack A, Cohen Y et al. Kidney involvement and renal manifestations in non-Hodgkin's lymphoma and lymphocytic leukemia: a retrospective study in 700 patients. *Eur J Haematol* 2001;67:158-64.
  11. Gore RM, Shkolnik A. Abdominal manifestation of pediatric leukemias: sonographic assessment. *Radiology* 1982;143:207-10.
  12. Hartman CJ, Goldman SM, Friedman AC, Fritzsche P. Renal lymphoma: radiological pathologic correlation of 21 cases. *Radiology* 1982;144:759-66.
  13. Malena S, Gianviti A, Orazi C, Fariello G. Renal echography in the early diagnosis of malignant hemolymphopathy in children. Apropos of 4 cases. *Radiol Med*. 1990; 80:564-67.
  14. Boueva A, Bouvier R. Precursor B-cell lymphoblastic leukemia as a cause of a bilateral nephromegaly. *Pediatr Nephrol* 2005;20:679-82.